

# Secondary Retinitis pigmentosa subsequent to docetaxel and carboplatin combination - A rare cytotoxic chemotherapy complication

Taarika G, MBBS<sup>1</sup>, V Panimalar A Veeramani, DNB<sup>2</sup>, Sanjeev Kumar Puri, MS ophthalmology<sup>3</sup>, Divya N, MS ophthalmology<sup>4</sup>

Saveetha Institute of Medical and Technical Sciences (Deemed to be University): SIMATS Deemed University

## SUMMARY

Visual loss following secondary retinitis pigmentosa (RP) is a rare complication of cytotoxic chemotherapy. Few cases of docetaxel- and/or platinum-induced retinal toxicity have been reported. Routine ocular examination of patients undergoing chemotherapy is required for early recognition and intervention of ocular toxicity. A 72-year-old female undergoing docetaxel and carboplatin combination chemotherapy for the past 3 months presented with complaints of defective vision in both eyes for 2 months. Fundus examination revealed a waxy pale disc in both eyes, arteriolar attenuation, and peripheral bony spicules, suggesting secondary retinitis pigmentosa. Optical Coherence Tomography (OCT) of the macula revealed macular dystrophy. The Humphrey Visual Field (HVF) showed field defects. Despite the reduction in chemotherapy dosage, no improvement was observed during the three-week follow-up period.

## KEYWORDS:

Retinitis pigmentosa, chemotherapy, macular dystrophy

## INTRODUCTION

Due to the distinct anatomical, physiological, and biochemical properties of the eye, ocular toxicity caused by cancer treatment encompasses a wide range of conditions, including maculopathy, cortical blindness, and blurred vision. The adnexal, anterior segment, posterior segment, and neuro-ophthalmic segments are the categories in which ocular side effects can be divided. One of the medications in the taxane class, docetaxel is an anti-mitotic chemotherapy agent that is approved for the treatment of breast cancer and uterine carcinoma, among other solid tumors.<sup>1</sup> A hereditary retinal degeneration that causes gradual contraction of the visual field is called retinal pigmentosa (RP). Midperipheral photoreceptors are first affected by RP, and as the condition worsens, more central retinal regions are also affected.<sup>2</sup> Chemotherapy might affect the retina, causing ocular toxicity. Routine ocular examination with fundus evaluation should be performed for patients undergoing chemotherapy.

## CASE PRESENTATION

A 72-year-old woman with a known case of type 2 diabetes mellitus presented with complaints of defective vision in both

eyes for 2 months, which was sudden in onset and progressive in nature. History of right eye cataract surgery performed 4 years back and postoperative vision was 6/9. She had a history of uterine carcinoma 2 years ago, for which she underwent hysterectomy and was receiving docetaxel and carboplatin combination chemotherapy for the past 3 months. Docetaxel (60 mg/m<sup>2</sup>) was administered intravenously (iv) for 1 h, followed by carboplatin (6 mg/ml/min) administered intravenously for 1 h at 3 weeks interval. The patient developed a sudden decrease in vision after 3rd cycle of chemotherapy. The patient stated that her ocular problems began after the start of treatment, and her medical history revealed that she had no prior ocular disorders. There was no family history of retinal dystrophy.

On examination, visual acuity in both eyes was 6/24 and color vision in both eyes 0/25 plates. Anterior segment right eye pseudophakia and left eye nuclear sclerosis grade I with posterior subcapsular cataract and normal pupil reaction. The intraocular pressure was normal. Fundus examination revealed pale disc, arteriolar attenuation, and bony spicules in the periphery. Optical Coherence Tomography (OCT) macular dystrophy. The Humphrey Visual Field (HVF) showed both eyes near the total field defect. Bilateral loss of rod and cone cell function was demonstrated by electroretinography as diminished scopic and photopic responses.

The patient was diagnosed with secondary retinitis pigmentosa after chemotherapy. The patient was diagnosed with poor visual prognosis. The patient's condition was discussed with an oncologist, and the dose of chemotherapy was reduced. The patient was followed-up for 3 weeks, and the visual acuity and fundus changes remained the same.

## DISCUSSION

The development of secondary retinitis pigmentosa following cytotoxic chemotherapy, particularly docetaxel and carboplatin combination therapy, represents a rare but significant ocular complication. Docetaxel and carboplatin are commonly used in the treatment of various malignancies, including uterine cancer, due to their efficacy in inhibiting cancer cell proliferation. However, both agents have been associated with ocular side effects, albeit less frequently than other systemic adverse reactions.

This article was accepted: 07 August 2024

Corresponding Author: Rajeshkumar Shanmugam

Email: rajeshkumars.smc@saveetha.com

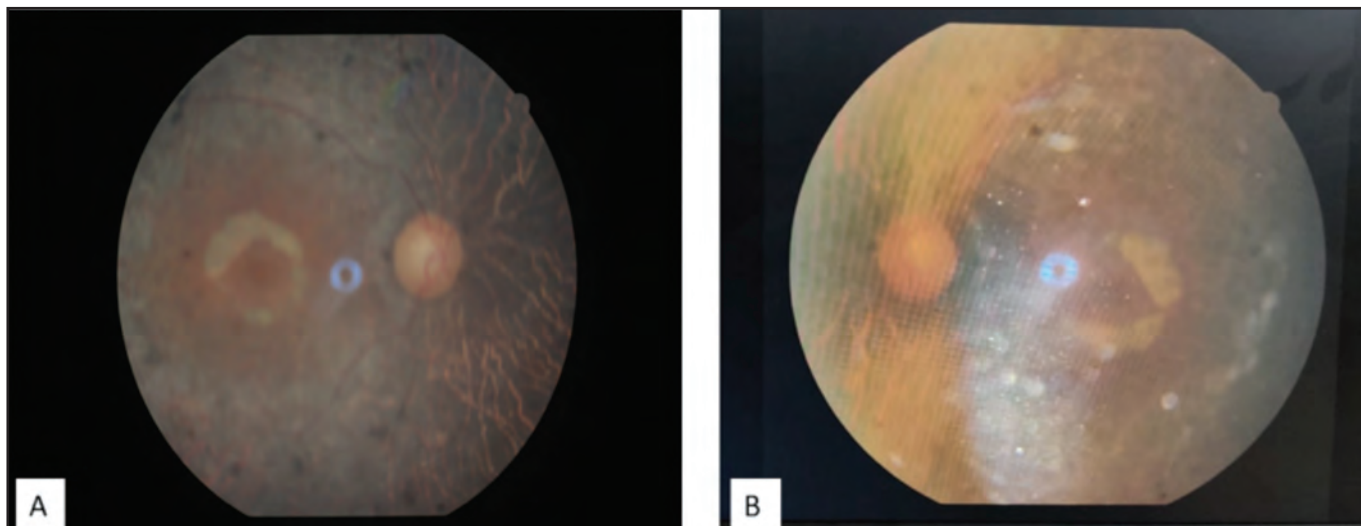


Fig. 1: A & B showing fundus photograph of right and left eye with waxy pale disc, arteriolar attenuation, bony spicules in periphery respectively

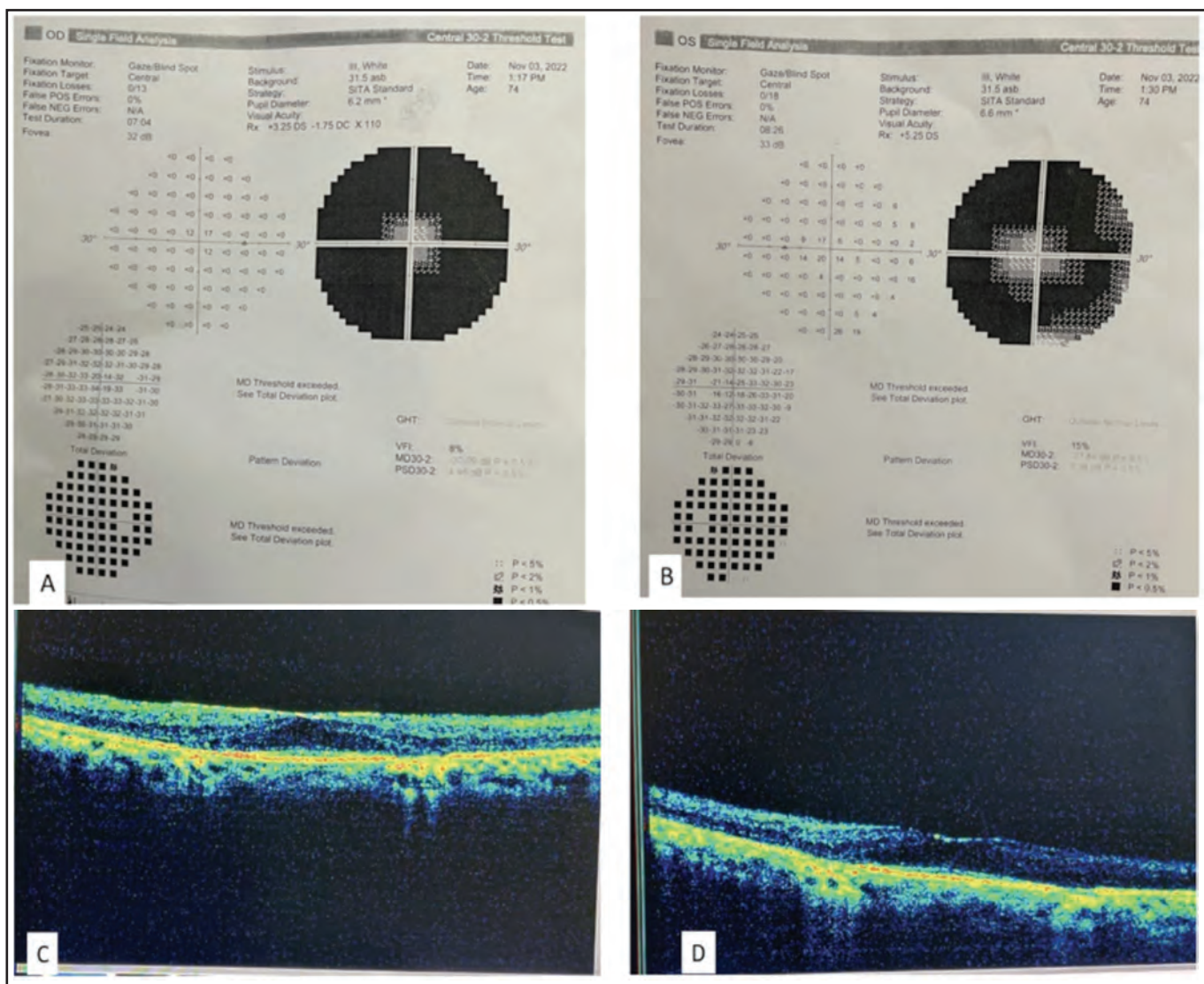


Fig. 2: A & B: Right eye and left eye near total field defect respectively. C & D: Right eye and left eye OCT showing macular dystrophy respectively

The mechanism underlying chemotherapy-induced retinal toxicity remains poorly understood; however, several hypotheses have been proposed. Chemotherapy agents may directly damage retinal cells, disrupt retinal microvasculature, or induce oxidative stress, leading to cellular dysfunction and apoptosis.<sup>3</sup> Additionally, individual susceptibility factors, such as genetic predisposition or pre-existing retinal abnormalities, may influence the development and severity of chemotherapy-related ocular toxicity.

One case study reported an acceleration of RP in a patient with non-Hodgkin's lymphoma, a known case of Usher's syndrome.<sup>4</sup> There is another case study showed bilateral blindness with secondary retinitis pigmentosa following postoperative docetaxel and platinum combination chemotherapy in primary small-cell carcinoma of the endometrium.<sup>5</sup> In which, the patient presented with symptoms consistent with RP within a few months of chemotherapy, suggesting the onset of retinal toxicity. Therefore, it's feasible that the patient's chemotherapeutic treatment may have led to the development of RP through a neurotoxic effect caused by one of its components. Neurotoxicity of taxanes showed alterations in electroretinogram.<sup>3</sup> Patient had no ocular complaints suggestive of RP in the past and patient record during right eye cataract surgery showed normal fundus findings. No family history of retinitis pigmentosa was present, indicating that chemotherapy exposure was the precipitating factor. Notably, the onset of visual disturbances coincided with the administration of docetaxel and carboplatin combination therapy, further supporting their potential role in retinal injuries.

The management of chemotherapy-induced RP primarily focuses on symptomatic relief and supportive care as there are currently no definitive treatments to reverse retinal degeneration. Ophthalmologic monitoring is essential for the early detection of RP and the initiation of interventions to optimize visual function and quality of life. Additionally, patients receiving cytotoxic chemotherapy should be educated about potential ocular side effects and encouraged to report any visual changes promptly.

## CONCLUSION

The present case underscores the importance of recognizing and addressing chemotherapy-induced ocular complications, particularly the rare occurrence of secondary RP after docetaxel and carboplatin combination therapy. Despite being primarily used for their antineoplastic effects, cytotoxic agents can inadvertently lead to ocular toxicity, highlighting the need for vigilant monitoring and early intervention. The onset of RP symptoms following the initiation of chemotherapy emphasizes the importance of follow-up care for patients undergoing cytotoxic treatment. All patients undergoing chemotherapy should undergo regular ophthalmological screening to identify complications at the earliest.

## DECLARATION

The authors declare no conflict of interest

## INFORMED CONSENT

Written informed consent was obtained from the patient for publication of this case report

## REFERENCES

1. Škubník J, Pavlíčková V, Ruml T, Rimpelová S. Current perspectives on taxanes: Focus on their bioactivity, delivery and combination therapy. *Plants* 2021; 10(3): 569.
2. Li Y, Li Y, Li J, Pi G, Tan W. Paclitaxel- and/or cisplatin-induced ocular neurotoxicity: a case report and literature review. *Oncol Targets Ther* 2014; 7: 1361-6.
3. Bakbak B, Gedik S, Koktekir BE, Yavuzer K, Tulek B, Kanat F, et al. Assessment of ocular neurotoxicity in patients treated with systemic cancer chemotherapeutics. *Cutan Ocul Toxicol*. 2014; 33(1): 7-10.
4. Blanchet P, Wellemeyer ML, Burton GV. Case report: retinitis pigmentosa following cytotoxic chemotherapy in Usher's syndrome. *Am J Med Sci* 1992; 303(5): 319-20.
5. Tang Q-L, Liu J, Zuo L, Chi C, Dong H-Y, Jiang X-X, et al. Bilateral blindness with secondary retinitis pigmentosa following postoperative docetaxel and platinum combination chemotherapy in primary small-cell carcinoma of the endometrium: An unusual case report and review of the literature. *Mol Clin Oncol* 2017; 6(4): 477-82.