

Diffusion-weighted imaging in hyperacute haemorrhagic stroke patients presenting within thrombolysis window

Mohd Fandi Al Khafiz Kamis, MD¹, Azril Ishak, MD¹, Norafida Bahari, MD¹, Mohd Naim Mohd Yaakob, MD¹, Ezamin Abdul Rahim, MD¹, Janudin Baharin, MD², Iskasymar Ismail, MD³, Mohamad Khairi Mahmood, MD¹, Hilwati Hashim, MD⁴, Ahmad Sobri Muda, MD¹

¹Department of Radiology, Hospital Sultan Abdul Aziz Shah (HSAAS), Faculty of Medicine and Health Sciences, Universiti Putra Malaysia, Serdang, Malaysia, ²Department of Neurology, Hospital Hospital Sultan Abdul Aziz Shah (HSAAS), Faculty of Medicine and Health Sciences, Universiti Putra Malaysia, Serdang, Malaysia, ³Hospital Hospital Sultan Abdul Aziz Shah (HSAAS), Faculty of Medicine and Health Sciences, Universiti Putra Malaysia, Serdang, Malaysia, ⁴Department of Radiology, Faculty of Medicine, Universiti Teknologi MARA, Sungai Buloh, Malaysia

ABSTRACT

Introduction: Diffusion-weighted imaging (DWI) in magnetic resonance imaging (MRI) has been proposed as the first line of neuroimaging for acute ischaemic stroke. The reliability of DWI in detecting intracranial haemorrhage, however, is still unproven, compared with susceptibility-weighted imaging (SWI) and CT scan which being considered the gold standard. This study seeks to establish the reliability of DWI as a first-line imaging modality to detect the intracranial haemorrhage in the patients present within the thrombolysis window.

Materials and Methods: A retrospective cross-sectional analysis was performed on patients who presented to our institution from April 2020 until July 2021 for acute stroke and had MRI brain as first-line neuroimaging. A total of 31 subjects were included in this study. Two radiologists assessed the signal patterns in DWI sequence and compared them with SWI and CT Brain, whenever available, as the gold standard for observing the presence of intracranial haemorrhage.

Results: The majority of patients with hyperacute bleed proven to be revealed on SWI or CT, thus showed characteristics of central hyperintensity and peripheral hypointense rim, on DWI. Slightly more than half (51.6%) presented with mild to moderate NIHSS scores (1–15). The sensitivity, specificity, positive predictive value and negative predictive value of DWI in detecting intracranial intra-axial haemorrhages were exceptionally high. There is strong interobserver level of agreement in identifying central haemorrhagic signal intensity [$\kappa = 0.94$ (0.06), $p < 0.05$].

Conclusion: This study supported the DWI sequence as a reliable sequence in MRI, to detect intracranial haemorrhage in hyperacute stroke.

KEYWORDS:

Acute stroke; haemorrhagic; magnetic resonance imaging; diffusion-weighted imaging

INTRODUCTION

Haemorrhage accounts for 15–30% of hyperacute stroke, rapid neuroimaging is readily available in many centres and advocated in many recommendations.^{1,3} To ensure a safe and optimal acute management, it is critical to exclude the intracranial haemorrhage, where intravenous thrombolysis and mechanical thrombectomy are contraindicated.^{4,5} Non-contrasted computed tomography (CT) and magnetic resonance imaging (MRI) are effective tools to exclude intracranial haemorrhage in hyperacute stroke. Although more than 90% of centres are using CT as the first line of neuroimaging, there are now more centres adopting an MRI-first policy in hyperacute stroke.^{7,8}

Diffusion-weighted imaging (DWI) provides a more accurate measure of infarct core volume, which is valuable as the first sequence in hyperacute stroke. However, the DWI is not routinely used to evaluate haemorrhage. Kang et al.⁹ described the signal intensity of hyperacute haemorrhage as observed on the DWI as hyperintense core and focal areas of variable hypointensity. These are consistently found in all patients with hyperacute haemorrhage. According to the authors, the hypointense areas are not caused by susceptibility artefact due to paramagnetic substances such as intracellular deoxyhemoglobin or methaemoglobin but may be related to the T2 shine-through effect caused by vasogenic oedema surrounding the haematoma.⁹

Our centre is a newly established teaching hospital which adopted the MRI-first policy for hyperacute stroke using the Putra Acute Stroke.¹⁰ This study was performed to share early experience conducting the reliability of DWI as the first sequence to detect the intracranial haemorrhage in MRI on acute stroke patients who presented within the thrombolysis window.

MATERIALS AND METHODS

The retrospective data were collected from our acute stroke registry. All cases presented within the acute stroke treatment window and triggering the stroke code who had MRI as the first neuroimaging were then evaluated. All cases that

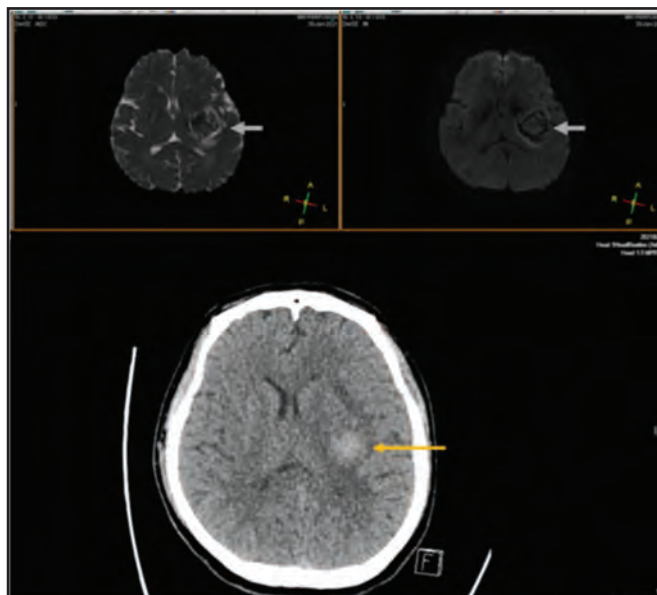


Fig. 1: DWI shows central hyperintensity with surrounding hypointensity rim with the outer hyperintense rim in b-1000 and ADC, representing oedema (arrows). Comparison to SWI and CT of the same patient.

underwent MRI using Philips Ingenia 3.0 Tesla by employing the Putra Acute Stroke protocol.¹⁰

Putra Acute Stroke Protocol for acute stroke consists of three main sequences: diffusion-weighted imaging (DWI), Fluid Attenuated Inversion Recovery (FLAIR), and MR angiography (time of flight). Additional sequences were also applied, which include susceptibility-weighted imaging (SWI), Perfusion imaging and BB (Black Blood) post-contrast, when necessary. The decision for treatment is usually achieved after the third sequence and IV thrombolysis will be given inside the MRI room if indicated. Thrombolysis will not be given if the initial sequence shows a haemorrhagic lesion on the DWI.

Two radiologists with at least 5 years of experience in general radiology reviewed all the MRI images. Each observer documented the demographic data, National Institute of Health Stroke Scale (NIHSS) score, characteristic appearance of the haemorrhagic lesion on DWI, ADC value and compared with SWI or CT Brain, whichever is available. Intra-observer agreements were calculated for the appearance of suspected haemorrhage on the DWI by correlating the findings with the SWI sequence. Observers were blinded to the patient's identity and MRI report. The intra-observer reliability and agreement were tested by Kappa coefficient statistical test.

RESULTS

There were a total of 345 patients who presented with hyperacute stroke from April 2020 to July 2021. In this study, 281 cases with ischaemic stroke, transient ischaemic stroke, or normal findings, and further 14 cases of stroke mimics were excluded. Another 11 patients who had extra-axial

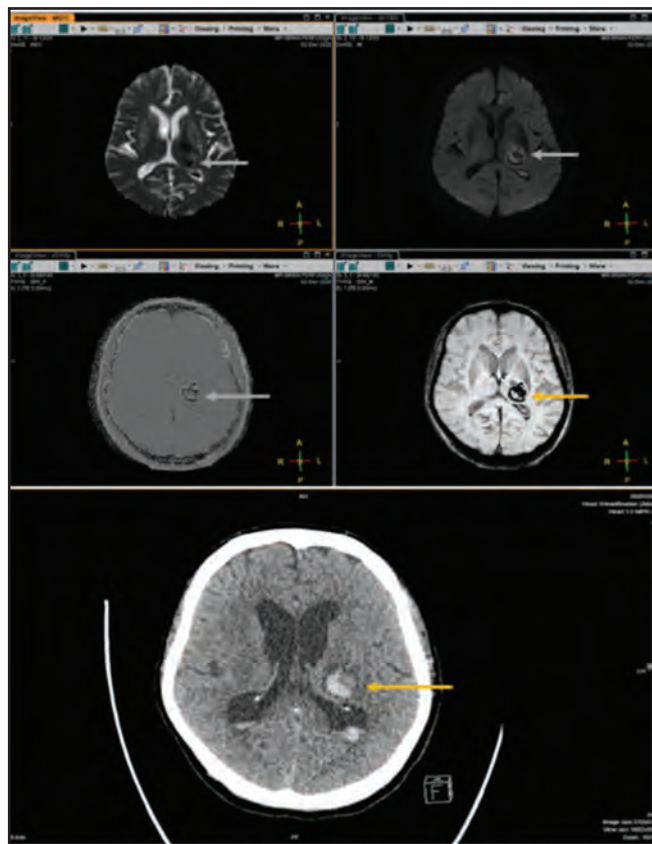


Fig. 2: Another hyperacute haemorrhagic stroke patient with left basal ganglia bleed, showing similar central hyperintense area with surrounding hypointense rim (arrows). Comparison to SWI and CT brain of the same patient.

haemorrhages and microhemorrhages were also excluded. The remaining 39 subjects had a haemorrhagic stroke with SWI confirming the presence of haemorrhages. However, eight subjects presented beyond thrombolysis windows from the onset, and thus were excluded. Only a total of 31 patients were included in this study.

Of the 31 patients with haemorrhagic stroke included in this study, the majority were men (81%) and the mean age was 58.1 years (95% of patients were 34.7– 81.5 years old). Sixteen patients (51.6%) presented with mild to moderate NIHSS scores (1–15). A majority (65%) of intra-axial haemorrhagic lesions occurred within the basal ganglia, followed by the cerebral cortex (25%) and the posterior fossa (10%).

The features in the DWI were variable intensities of the central area with peripheral hypointense rim and outer rim of oedema. The signal intensity was classified as either predominantly hyperintense or hypointense, or heterogeneous. There is a very high agreement among the observers, who noted that most subjects (58%–61%) demonstrated hyperintense central area while a significant percentage of the subjects (25–29%) showed hypointense central area. Nearly all subjects demonstrated peripheral hypointensity (96.8%) with the remaining being heterogeneous.

There was excellent percentage agreement (100%) demonstrated between the two radiologists in terms of identifying and localising the haemorrhage, based on the DWI sequences (b-1000 and ADC) in comparison to the SWI.

DISCUSSION

CT scan is still a preferred imaging technique to rule out the haemorrhage in hyperacute stroke. Few authors studied the feasibility of DWI versus conventional imaging in assessing the intracranial haemorrhage.^{6,7,9,11} DWI detects the restricted diffusion resulting from cell death, which includes haemorrhagic changes.^{9,11} The T2 effect contributed to the DWI signal due to the presence of paramagnetic haemoglobin by-products, deoxyhaemoglobin and methaemoglobin.¹²

In acute haematoma, DWI typically shows a markedly hyperintense core due to the paramagnetic effect of intracellular deoxyhemoglobin and methaemoglobin and a thin markedly hypointense rim (Fig. 1). From this study, the authors concluded that DWI is more accurate in detecting, characterising and staging the hyperacute, medium and large-sized acute and early subacute haemorrhages. DWI, however, is not sensitive in characterising the small haemorrhages, which, in other gradient echo sequences like SWI or GRE as necessary.¹³ Kang et al.⁹ also supported the findings of central hyperintensity representing diamagnetic oxyhaemoglobin and a peripheral hypointense rim representing early conversion to paramagnetic deoxyhemoglobin in the hyperacute haematomas.

In this study, DWI demonstrated three main components in haemorrhagic stroke, central area of hyperintensity with a small percentage of heterogeneous central intensities, surrounding peripheral rim of hypointensity and outer rim of peripheral oedema. All cases in this study concurred with the SWI, and some cases corresponded well with the CT, in confirming the presence of haemorrhage (Fig. 2). This experience demonstrated that the DWI features are vivid and easily differentiated, which may not require a very experienced neuroradiologist to elicit the findings of haemorrhagic stroke. Despite SWI or GRE sequences being used as the gold standard to detect hemorrhagic stroke in MRI, this study supported the notion that DWI has high sensitivity and specificity in order to identify the haemorrhage in hyperacute stroke.

LIMITATIONS

Small retrospective series of only 31 subjects without validation against the gold standard are among the limitations of this study. However, we believe this series will give useful insights to your esteemed readers.

CONCLUSIONS

In the acute stroke imaging procedure, DWI with ADC may be a viable substitute for CT to rule out hemorrhagic stroke. This study also demonstrated that the MRI-first policy for hyperacute stroke patients won't affect the ability to identify hemorrhagic stroke patients.

ACKNOWLEDGMENTS

The authors would like to acknowledge Farid Bajuri (ORCID iD: 0000-0003-1517-7282) from the Department of Aerospace Engineering, Faculty of Engineering, Universiti Putra Malaysia, 43400, Serdang, Selangor, Malaysia on the formatting and arrangement of the manuscript.

REFERENCES

1. Aziz ZA, Lee YYL, Ngah BA, Sidek NN, Looi I, Hanip MR, et al. Acute Stroke Registry Malaysia, 2010-2014: Results from the National Neurology Registry. *Journal of stroke and cerebrovascular diseases : the official journal of National Stroke Association* [Internet]. 2015 [cited 2019 May 19];24(12):2701-9. Available from: <https://www.ncbi.nlm.nih.gov/pubmed/26338106>
2. Neelamegam M, Looi I, Cheah WK, Narayanan P, Abdul Hamid AM, Ong LM. Stroke incidence in the South West District of the Penang Island, Malaysia. *Preventive Medicine*. 2013;57:S77-9.
3. Loo KW, Gan SH. Burden of Stroke in Malaysia. *International Journal of Stroke* [Internet]. 2012 Jan 20 [cited 2019 Jul 7];7(2):165-7. Available from: http://www.medic.usm.my/images/files/pub-march/mac_cited05%20.pdf
4. Malaysian Society of Neurosciences, Clinical Practice Guidelines: Management of Ischaemic Stroke (3rd edition). *CVNS 2021*; 3: 1-155.
5. Chia PK, Mohamad NA, Inche Mat LN, Itam@Ismail I, Yusof Khan AHK, Loh WC, et al. Regional Emergency Stroke Quick-Response (RESQ) Network: A Proposed Paradigm of Malaysia Stroke Care Services. *Malaysian J Med Health Sci* 2020; 16: 353-61.
6. Vilela P, Rowley HA. Brain ischemia: CT and MRI techniques in acute ischemic stroke. *European Journal of Radiology*. 2017; 96: 162-72.
7. Provost C, Soudant M, Legrand L, Ben Hassen W, Xie Y, Soize S, et al. Magnetic Resonance Imaging or Computed Tomography Before Treatment in Acute Ischemic Stroke. *Stroke* [Internet]. 2019 Mar [cited 2020 Jan 28]; 50(3): 659-64. Available from: <https://www.ahajournals.org/doi/full/10.1161/STROKEAHA.118.023882>
8. Sølling C, Mahmoud Ashkanian, Hjort N, Carsten Gyldensted, Andersen G, Østergaard L. Feasibility and logistics of MRI before thrombolytic treatment. *Acta Neurologica Scandinavica*. 2009; 120(3): 143-9.
9. Kang BK, Na DG, Ryoo JW, Byun HS, Roh HG, Pyeun YS. Diffusion-Weighted MR Imaging of Intracerebral Hemorrhage. *Korean Journal of Radiology* [Internet]. 2001 Dec 31 [cited 2023 May 8];2(4):183-91. Available from: <https://synapse.koreamed.org/articles/1027489>
10. Muda AS, Kamis MFAK, Mohd Yaakob MN, Abdul Rahim E, Mahmood MK, Md Noh MSF, et al. Putra acute stroke protocol. *CVNS 2021*; 3: 12-4.
11. Cavusoglu M, Duran S, Sözmen Cılız D, Tufan G, Hatipoglu Çetin HG, Ozsoy A, et al. Added value of diffusion-weighted magnetic resonance imaging for the diagnosis of perianal fistula. *Diagnostic and Interventional Imaging* [Internet]. 2017 May [cited 2020 Apr 20];98(5): 401-8. Available from: <https://isiarticles.com/bundles/Article/pre/pdf/148544.pdf>
12. Whang JS, Kolber M, Powell DK, Libfeld E. Diffusion-weighted signal patterns of intracranial haemorrhage. *Clin Radiol*. 2015 Aug;70(8):909-16. doi: 10.1016/j.crad.2015.04.006. Epub 2015 Jun 4. PMID: 26050534.
13. Fiebach JB, Schellinger PD, Gass A, Kucinski T, Siebler M, Villringer A, et al. Stroke Magnetic Resonance Imaging Is Accurate in Hyperacute Intracerebral Hemorrhage. *Stroke*. 2004 Feb; 35(2): 502-6.