

# A curious case of Meckel's diverticulum

Michael Arvind<sup>1</sup>, MRCs, Benedict Dharmaraj<sup>1</sup>, MS, Mohd Razali Ibrahim<sup>1</sup>, MS, Jasjit Singh Nijhar<sup>2</sup>, MS, Zainal Ariffin Azizi<sup>1</sup>, MS

<sup>1</sup>Department of General Surgery, Hospital Kuala Lumpur, <sup>2</sup>Department of Surgery, Hospital Selayang

## SUMMARY

Meckel's diverticulitis or Meckel's associated pathology frequently presents in childhood with gastrointestinal bleeding. It is rarely seen in adults. It is a congenital abnormality that commonly goes undetected. We present a case of a perforated Meckel's diverticulum due to fishbone ingestion in an elderly gentleman. The aim of this case report is to highlight the rare presentation of a perforation in a Meckel's diverticulum due to an extrinsic pathology and to outline diagnostic and management options in cases of Meckel's diverticulum.

## KEY WORDS:

*Meckel's diverticulum; perforation; appendicitis; laparoscopic; fish bone*

## INTRODUCTION

Meckel's diverticulum is the commonest congenital malformation of the upper gastrointestinal tract. It is seen in 2% of individuals, two feet from the ileocaecal valve and is two inches long. It is a remnant of a persistent vitello-intestinal duct. German anatomist, Johann Friedrich Meckel, first described it in 1809 and Salzer only established discovery of ectopic gastric mucosa about 100 years later.<sup>1</sup> It is commonly seen in the paediatric age group, presenting either as haemorrhage, intestinal obstruction or abdominal pain. We highlight a case of a perforated Meckel's diverticulum in a 63-year-old male presenting with symptoms suggestive of acute appendicitis. This case report aims to highlight the curious presentation of a Meckel's diverticulum in an elderly male.

## CASE REPORT

A 63-year-old gentleman with underlying type II Diabetes Mellitus, Ischemic Heart Disease post angioplasty in 2013 and underlying gastritis, who self medicates, presented with complaints of right iliac fossa pain for one day. It was sudden in onset, continuous in nature but not associated with any migration or radiation of pain. He was afebrile, had no diarrhea or vomiting, did not complain of loss of appetite and did not have any urinary tract infection. He had no significant surgical history. Clinically his abdomen was tender on deep palpation at the right iliac fossa and he had bilateral reducible inguinal hernias. The rest of the general and systemic examination was unremarkable. His white cell

count was  $6.9 \times 10^9/L$ . All other blood investigations were within normal limits. His erect X-ray did not demonstrate air under the diaphragm. An ultrasound showed minimal free fluid and pericolic streakiness, which was suggestive of acute appendicitis. Following the investigations, he underwent a diagnostic laparoscopy. Intraoperatively, it was noted that the appendix was white and he had a perforated broad based Meckel's diverticulum, due to a fish bone, 60cm from the terminal ileum. There was no intra-abdominal contamination. He underwent a laparoscopic assisted open wedge resection of the Meckel's diverticulum with primary single layer extra mucosal seromuscular closure. Postoperative recovery was uneventful. He was discharged home post operation day 5 after completing antibiotics and resuming normal feeds.

## DISCUSSION

Meckel's diverticulum is a true diverticulum, meaning it possesses all three layers of the intestinal wall and has its own blood supply from the superior mesenteric artery (SMA). It is seen in 2% of the population, with a male to female ratio of 2:1. It is located two feet from the ileocaecal valve, on the antimesenteric border, and can be two inches long.<sup>2</sup> It is due to failure or incomplete obliteration of the vitello-intestinal duct.<sup>2</sup> A Meckel's diverticulum is most often asymptomatic except in 4-6% of individuals.<sup>2</sup> When complications arise, it commonly presents as bleeding in the paediatric age group; or as intestinal obstruction and acute inflammation that can mimic acute appendicitis in adults.<sup>2</sup> More often than not, it can also be identified incidentally during abdominal exploration, as was demonstrated in our patient.

The controversy arises when it comes to treatment: should all Meckel's diverticulum be excised? All symptomatic Meckel's diverticulum should be resected. The options available are laparoscopic and open surgery. Both can be done using staplers or sutures. In this case, a laparoscopic wedge resection with primary closure using single layer extra mucosal seromuscular closure was done. Another option is a simple diverticulectomy. Care must be taken during resection to ensure patency of the lumen is preserved and all ectopic mucosa along with possible mucosal ulceration is resected. There is no definitive data proving one is better than the other.<sup>4</sup>

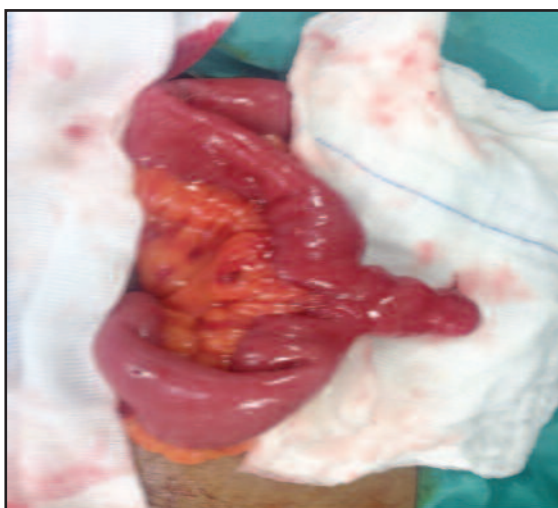
This article was accepted: 6 April 2016

Corresponding Author: Michael Arvind, Medical Officer, Hospital Kuala Lumpur, General Surgery, Jalan Pahang, Kuala Lumpur, Wilayah Persekutuan 50586, Malaysia

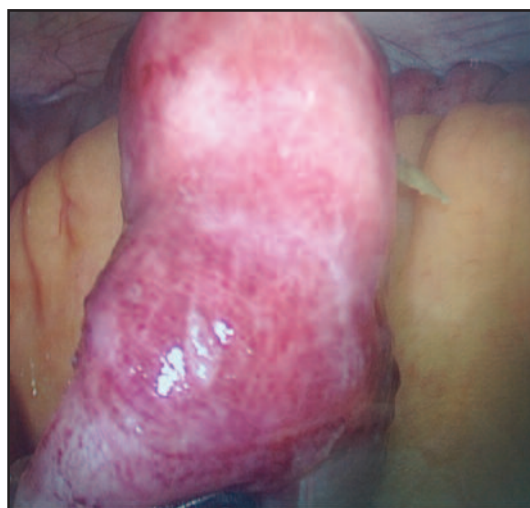Email: michaelarvind@gmail.com

**Table I: Investigation studies for Meckel's diverticulum**

Plain Abdominal X-Ray	<ul style="list-style-type: none"> <li>• Non specific sign of intestinal obstruction</li> <li>• May demonstrate an enterolith in the lower abdomen, but cannot be definitely localised to Meckel's as opposed to appendix</li> </ul>
Abdominal Ultrasound	<ul style="list-style-type: none"> <li>• An obstructed Meckel's diverticulum may be identified as a fluid filled pouch off the distal small intestine</li> <li>• Easily confused with appendicitis</li> </ul>
Abdominal CT	<ul style="list-style-type: none"> <li>• Intussusception can be diagnosed but unable to attribute lead point due to Meckel's</li> <li>• Rarely identifies asymptomatic or bleeding diverticulum</li> <li>• Almost impossible to differentiate between Meckel's and normal small bowel loops with abscess and inflammation</li> </ul>
Upper GI Study	<ul style="list-style-type: none"> <li>• Acutely inflamed diverticulum associated with bowel wall thickening of peri-diverticular fat can be identified as a blind pouch off distal small bowel</li> <li>• Can demonstrate Meckel's on small bowel series, but not reliable</li> <li>• High false negative due to rapid emptying of contrast from diverticulum, obscured visualisation and poor filling of diverticulum if narrow neck</li> </ul>
Mesenteric angiography	<ul style="list-style-type: none"> <li>• Meckel's can be diagnosed if presence of anomalous SMA feeding diverticulum or if bleeding which is shown as active extravasation of contrast</li> </ul>
Meckel's Scan	<ul style="list-style-type: none"> <li>• Can detect bleeding as little as 0.3ml/min</li> <li>• Only identifies ectopic gastric mucosa</li> <li>• Using radioactive isotope, technetium 99m pertechnetate</li> <li>• 97% sensitivity and 95% specificity in both the paediatric and adult age groups</li> </ul>



**Fig. 1:** Meckel's diverticulum with perforation.



**Fig. 2:** Laparoscopic view of perforation with fish bone in-situ

Current guidelines state that in children and adults where a Meckel's diverticulum is detected incidentally on imaging studies, elective resection should not be performed. However as demonstrated in this case, complications may arise at any age. In a study regarding the outcomes of surgical management of Meckel's diverticulum related complications, it was shown that operative mortality and morbidity rates were 2% and 12% respectively, and that the cumulative risk of long-term postoperative complications was 7%. In contrast, the analysis of patients receiving incidental diverticulectomy showed that the operative mortality, morbidity, and risk of long-term postoperative complications were lower (1%, 2%, and 2%, respectively). It is generally recommended that Meckel's diverticulum discovered incidentally during operation should be removed, regardless of the patient's age.<sup>5</sup>

At our centre, the decision to resect an asymptomatic Meckel's diverticulum is on a case to case basis. Factors favouring resection would be a diverticulum longer than 2 cm, with a narrow neck, previous abdominal obstruction, and any palpable or visual abnormality of the Meckel's diverticulum.

The intriguing aspect regarding this case is the location of the perforation. Perforation at a Meckel's diverticulum is rare. As previously mentioned, being a true diverticulum means that the wall integrity is similar to other parts of the small bowel. Not unlike sump syndrome, the depression caused by the diverticulum may act as a sump for debris and foreign bodies to be deposited and, as in this case, a perforation due to the sharp nature of the foreign body. If this theory proves true, it would drastically alter management guidelines. It is an unproven hypothesis that will require further in vivo tests to validate.

**REFERENCES**

1. Jayesh S, Vikas K, Shah DK. Meckel's diverticulum: a systemic review. *J R Soc Med.* 2006; 99(10): 501-5
2. Brunnicardi F, Andersen D, Billiar T, *et al.* *Schwartz's Principles of General Surgery* 9th ed. McGraw-Hill Education; 2010
3. Lin S, Suhocki PV, Ludwig KA, Shetzline MA. Gastrointestinal bleeding in adult patients with Meckel's diverticulum: the role of technetium 99m pertechnetate scan. *South Med J* 2002; 95: 1338-41
4. Park JJ, Wolff BG, Tollefson MK, *et al.* Surgical management of Meckel's diverticulum: the Mayo Clinic experience with 1476 patients (1950-2002). *Ann Surg* 2005; 241: 529-33
5. Cullen JJ, Kelly KA, Moir CR, *et al.* Surgical management of Meckel's diverticulum. An epidemiologic, population-based study. *Ann Surg* 1994; 220: 564-69