

Hypercalcemic Crisis – A Fatal Case of Primary Hyperparathyroidism

Yueh Chien Kuan, MRCP, Florence Tan, MRCP

Department of Medicine, Sarawak General Hospital, Kuching, Sarawak, Malaysia

SUMMARY

We describe the clinical presentation, investigation and management of an eventually fatal case of hypercalcemic crisis due to primary hyperparathyroidism (PHPT).

A 60 year-old lady with history of urolithiasis presented with worsening generalized bone pain, spinal scoliosis and a limp. Laboratory data showed hypercalcemia and raised alkaline phosphatase. Left hip x-ray revealed a subcapital femoral neck fracture. Intact parathyroid hormone was elevated, 187.6 pmol/L (1.6 – 6.9) and ultrasound showed an enlarged right parathyroid gland. Despite initial reduction of serum calcium with saline infusion and multiple doses of intravenous pamidronate, her calcium increased to 4.14 mmol/L a week following application of Buck's traction for persistent left hip pain. She succumbed eventually with serum calcium peaking at 6.28 mmol/L despite multiple therapeutic interventions.

KEY WORDS:

Primary hyperparathyroidism, hypercalcemic crisis, pathological fracture, urolithiasis

INTRODUCTION

Hypercalcemic crisis is a condition of decompensated hypercalcemia usually with serum calcium above 3.5 mmol/L. There is no standard definition for this syndrome. Most literature, however, emphasizes that it is associated with rapid deterioration of the central nervous system, cardiac, renal and gastrointestinal function, resulting in renal failure, encephalopathy, cardiac dysrhythmias and even death.^{1,2} We report an unusual case of extreme hypercalcemia due to primary hyperparathyroidism (PHPT).

CASE REPORT

A 60 year-old woman, with chronic generalized bone pain presented to the orthopedic clinic with worsening left hip pain for the past 1 month rendering her unable to weight-bear. It was associated with generalised malaise, anorexia and weight loss. Past medical history included right urolithiasis treated by extracorporeal lithotripsy and hypertension treated with nifedipine and atenolol. She denied other medications. Review of other systems was normal.

On examination she walked with a limp, had scoliosis of the spine and was pale. Vital signs were normal and there was no palpable neck swelling or nodes. Chest spring and pelvic spring were negative. There was no spinal tenderness.

Laboratory evaluation yielded normochromic normocytic anemia: hemoglobin, 9.9 g/dL, mild leukocytosis with total white cell count of 11040/ μ L and normal platelet count. Erythrocyte sedimentation rate (ESR) was 62 mm in the first hour.

Biochemical assays revealed hypercalcemia, with corrected serum calcium at 3.37 mmol/L (2.02 – 2.60 mmol/L). Serum urea and creatinine were raised at 17.7 mmol/L (1.7 – 8.3 mmol/L) and 212 μ mol/L (40 – 90 μ mol/L) respectively. The serum phosphate was 1.21 mmol/L (0.87 – 1.45 mmol/L), serum potassium and magnesium were low at 2.8 mmol/L (3.3 – 5.1 mmol/L) and 0.57 mmol/L (0.65 – 1.05 mmol/L) respectively.

Liver function tests showed raised alkaline phosphates level at 848 U/L (35 – 104 U/L) and normal total protein (with normal albumin/globulin ratio), total bilirubin, aspartate and alanine transaminases levels. Thyroid function tests showed free T4 level at 13.59 pmol/L (11.50 – 22.70 pmol/L) and TSH level at 0.293 pmol (0.35 – 4.50 pmol/L).

Immunoglobulin electrophoresis was normal. Left hip x-ray revealed subcapital femoral neck fracture.

Over a period of one month, she underwent upper and lower endoscopy, chest x-ray, mammography, ultrasonography of the abdomen and pelvis, bone scan and gynecological examination for suspected malignant hypercalcemia before primary hyperparathyroidism was finally suspected and confirmed by elevated intact parathyroid hormone at 187.6 pmol/L (1.6 – 6.9). She required saline diuresis and multiple doses of intravenous pamidronate to decrease her serum calcium below 3.0 mmol/L. Due to persistent left hip pain, Buck's traction was applied. A week later, she was noted to be drowsy and hypotensive. Serum calcium repeated was 4.14 mmol/L. Despite initiation of saline infusion, subcutaneous calcitonin and intravenous hydrocortisone, she deteriorated rapidly within the next 6 hours with peak serum calcium of 6.28 mmol/L. Electrocardiography showed Osborn waves or J waves characteristically seen in severe hypercalcemia (Figure 1). Despite all efforts at resuscitation the patient could not be revived.

This article was accepted: 30 September 2014

Corresponding Author: Kuan Yueh Chien, Medical Department, Sarawak General Hospital, Jalan Hospital, 93586 Kuching, Sarawak, Malaysia

Email: kychien2006@yahoo.com

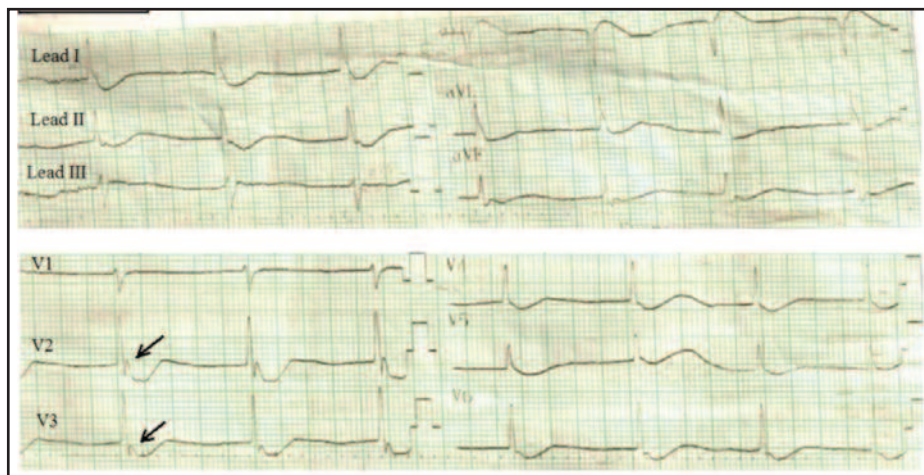


Fig. 1: 12-lead electrocardiogram showing J waves (arrow heads); recorded when serum calcium was 6.28 mmol/L.

DISCUSSION

Hypercalcemic crisis secondary to PHPT has variously been called parathyroid crisis, parathyroid storm and parathyrotoxicosis. Stable hypercalcemia in PHPT that decompensates into hypercalcemic crisis is uncommon, ranging from 1% to 6%.^{2,3} This may be due to the advent of automated biochemical assays which easily detect hypercalcemia during routine blood analysis, thus triggering further investigations and treatment before the disease is allowed to destabilize into a crisis.

Malignancy is the most common cause of hypercalcemia whether in the stable compensated state or decompensated state of hypercalcemic crisis.^{1,3} Malignancies commonly associated with hypercalcemia are squamous cell carcinoma of the lung, breast cancer, renal cell carcinoma, bladder cancer, and multiple myeloma. Mechanisms for hypercalcemia in malignancy include secretion of parathyroid hormone-related polypeptide, tumour production of other osteolytic factors, direct invasion or primary disease of the bone, and bone resorption due to osseous metastases.^{1,3}

Although malignancy is the commonest cause of hypercalcemia, our case highlighted the need to exclude PHPT early in the disease. Our patient had a history of urolithiasis and a long history of symptoms that strongly suggests parathyroidal hypercalcemia. Nephrolithiasis is an established symptom of PHPT and is included in the often quoted medical mnemonic “bones, stones, groans and moans”. It is recommended therefore that tumoral work-up be initiated simultaneously with steps to exclude parathyroidal hypercalcemia, simply by measurement of parathyroid hormone level. Elevated parathyroid hormone level in the presence of hypercalcemia is pathognomonic of PHPT.^{1,3}

Why patients with chronic hypercalcemia due to PHPT can suddenly evolve into hypercalcemic crisis is unclear. Infection, trauma, surgery, and even use of calcium antagonist have been suggested as precipitating factors.² In this patient, the crisis occurred a week after application of Buck's traction suggesting that immobilization could be the precipitating factor. Immobilization is a well-proven but

often overlooked cause of hypercalcemia especially in at-risk patients with high bone turnover, such as ours; due to her age and underlying hyperparathyroidism.

Our case report illustrates that parathyroid crisis is both a medical and surgical emergency. High mortality rate of 93.5% in patients treated conservatively without parathyroidectomy had been reported.² The mortality rate is reduced markedly to 6.7% with parathyroidectomy by an experienced endocrine surgeon.^{1,2,4} Hence, it is recommended that three vital steps be taken simultaneously when managing a patient with a parathyroid storm: medical therapy to lower serum calcium and to stabilize the patient; suspecting and establishing the diagnosis of PHPT by measuring parathyroid hormone level; and urgent parathyroidectomy. Calcium-free hemodialysis can be considered if the usual treatments of forced saline diuresis, bisphosphonate, glucocorticoid and/or calcitonin therapy fail.⁵ In retrospective review, calcium-free hemodialysis might have reduced serum calcium and stabilized our patient for surgery.

CONCLUSION

We report a rare case of hypercalcemic crisis secondary to PHPT. This case highlighted the need to consider primary hyperparathyroidism in patients presenting with hypercalcemic crisis, as well as the need for urgent parathyroidectomy once the diagnosis is established. Medical therapy alone is rarely successful and delay in surgical treatment can lead to a fatal outcome.

REFERENCES

1. Reinhard Ziegler. Hypercalcemic crisis. *J Soc Nephrol* 2001; 12: S3-S9.
2. Gurrado A, Piccinni G, Lissidini G, *et al.* Hypercalcaemic crisis due to primary hyperparathyroidism – a systematic literature review and case report. *Endokrynol Pol* 2012; 63(6): 494-502.
3. Wong P, Carmeci C, Jeffrey RB, *et al.* Parathyroid crisis in a 20 year old – an unusual cause of hypercalcaemic crisis. *Postgrad Med J* 2001; 77: 468-70.
4. Marienhagen K, Due J, Hanssen TA, *et al.* Surviving extreme hypercalcemia – a case report and review of the literature. *J Intern Med* 2005; 258(1): 86-9.
5. Koo WS, Jeon DS, Ahn SJ, *et al.* Calcium-free hemodialysis for the management of hypercalcemia. *Nephron* 1996; 72: 424-8.