

## CASE REPORT

# Severe Diabetic Papillopathy Mimicking Non-Arteritic Anterior Ischemic Optic Neuropathy (NAION) in A Young Patient

P S Mallika, MS\*, S Aziz, MS\*\*, T Asok, MMED\*\*, MS Chong, MS\*\*, A K Tan, MD\*, C N Chua, MRCP, FRCO\*

\*Department of Ophthalmology, Faculty of Medicine and Health Sciences, University Malaysia Sarawak, Kuching, Sarawak, Malaysia (Mallika Premsenthil, Tan Aik Kah, Chua Chung Nen), \*\*Department of Ophthalmology, Sarawak General Hospital, Sarawak, Malaysia (Mohamad Aziz Salowi, Asokumaran Thanaraj, Chong Min Siew)

### SUMMARY

With the pathophysiology not clearly understood and fewer than 130 cases having been reported in the literature, diabetic papillopathy presents a special challenge to the ophthalmologist. We report a case of a young patient with more than 12 years of Type 1 diabetes mellitus (T1DM) on insulin with poor compliance to treatment who presented with sudden bilateral loss of vision. Ocular examination, fluorescence angiography (FA) and systemic signs were conclusive of diabetic papillopathy. His fasting blood sugar level was high and serum glycosylated haemoglobin (HbA1c) indicated a long term fluctuating blood glucose control. His vision initially improved with treatment, but later deteriorated with tight glycaemic control.

### KEY WORDS:

*Diabetic papillopathy; Type 1 diabetes mellitus; non-arteritic anterior optic neuropathy; papilloedema*

### INTRODUCTION

Diabetic papillopathy is an uncommon ocular manifestation of diabetes mellitus (DM). It occurs in patients with both Type 1 diabetes mellitus (T1DM) and Type 2 diabetes mellitus (T2DM). Some authors consider it as a diagnosis of exclusion while others regard it as a separate disease entity. The clinical findings closely resemble non-arteritic anterior ischemic optic neuropathy (NAION), because both diabetic papillopathy and NAION are considered as ischemic optic neuropathies; however the former is an asymptomatic optic disc edema, whereas in the latter it is an acute optic disc infarction.

While authors have been describing diabetic papillopathy for more than 30 years as an asymptomatic, benign condition with no or minimal visual impact, we highlight a case of diabetic papillopathy in an uncontrolled DM, with sudden and severe visual impairment, exacerbated by tight glycaemic control.

### CASE REPORTS

A 22 year-old gentleman presented with blurring of vision involving both his eyes for 2 days duration. The vision loss was worse in the left eye. The blurring of vision was sudden

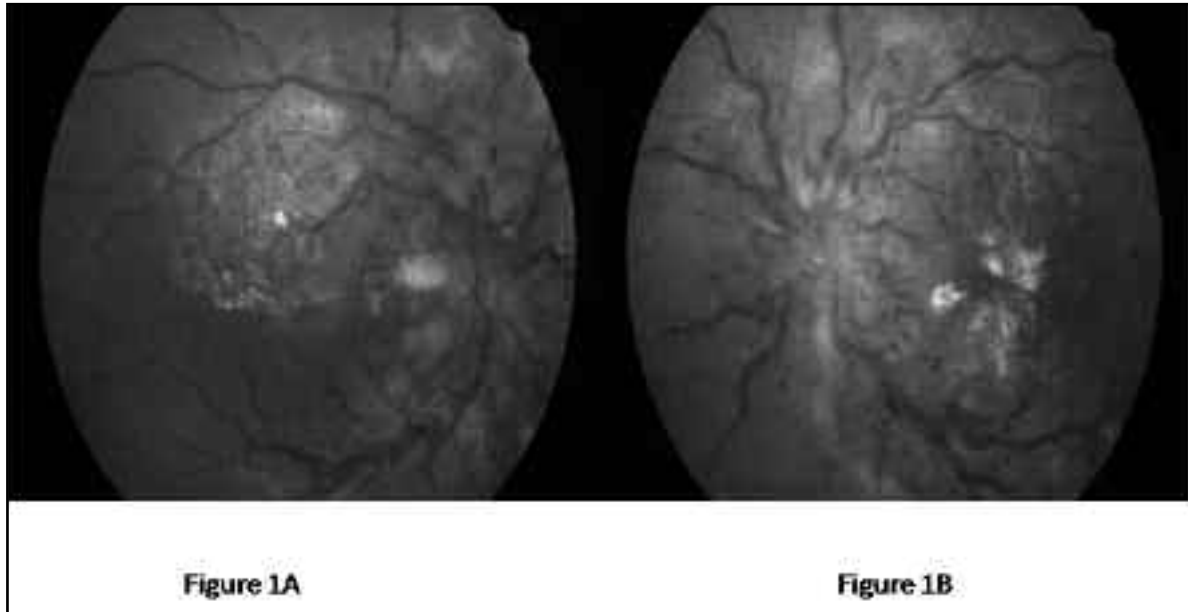
and not associated with any pain. He had difficulty in seeing distant objects and doing his near work. There were no other ocular symptoms. His past ocular history was unremarkable. He had T1DM for 12 years for which he was on insulin. He was not compliant to diabetic medications and currently not on any medications. There were no other systemic complaints associated with his diabetes. He had a strong family history of DM.

Neurological examination was normal. The visual acuity of his right eye was counting fingers (CF) at 2 M and left eye CF at 1 M not improving with pin hole. Both pupils were round, 4 mm in diameter with sluggish direct light reflex. Intraocular pressures (IOP) were 16 mm Hg in the right eye and 15 mm Hg in the left. Fundus examination showed bilateral hyperemic disc swelling, superficial dilated telangiectatic vessels on the disc, flame shaped hemorrhages and venous engorgement (Figure 1a & 1b). Moderate non-proliferative diabetic retinopathy (NPDR) was present in both eyes. FA showed hyperfluorescence of both discs with leakage of dye into the surrounding retina (Figure 2a & 2b). There was no delay in choroidal filling or choroidal filling defect. Visual field examination could not be done due to his poor vision. No orbital pathology was detected in the ultrasound B scan.

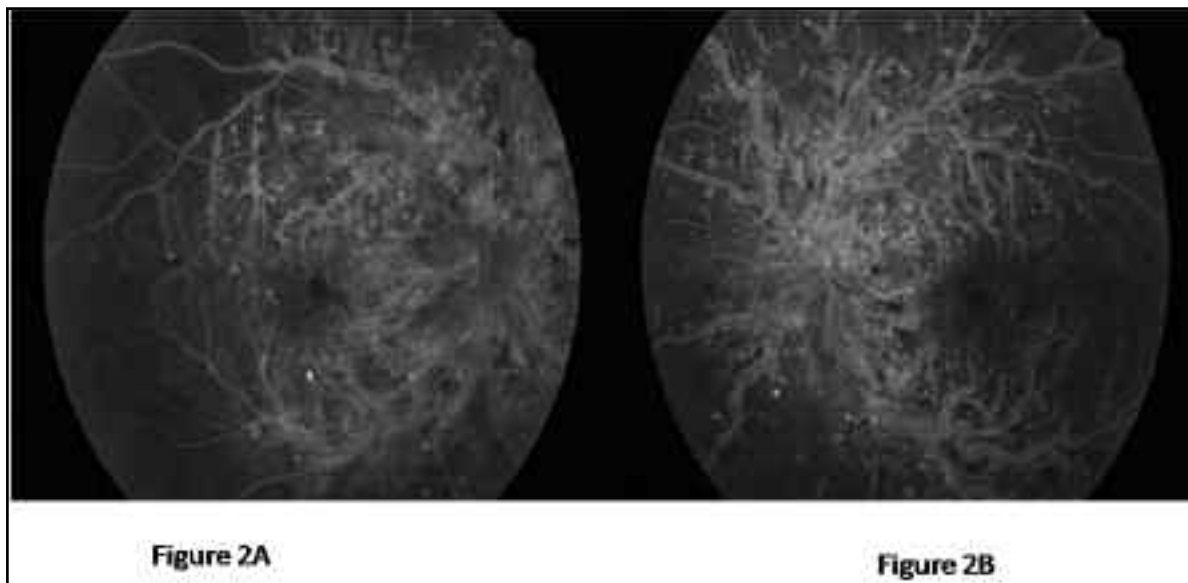
A detailed evaluation was done to establish the cause of the disc edema. His random blood sugar was 19.7mmol/L, HbA1C was 7.5%, fasting blood sugar 7mmol/L and blood pressure 130/90 mm Hg. Complete blood count, hemoglobin assay, serum electrophoresis, C reactive protein, rheumatoid factor, anti-nuclear antibodies, serum electrolytes, blood urea and nitrogen, chest X-ray were unremarkable. Neuro-imaging was not done for this patient as there were no symptoms and clinical signs of raised intracranial pressure (ICP). The patient was diagnosed with bilateral diabetic papillopathy, more severe in the left eye. He was immediately referred to a physician for his blood sugar control. One week later his vision in the right eye improved to 6/36, but his left eye vision remained the same. Fundus examination revealed resolving optic disk edema. However, one month later he presented again with deterioration of his right eye vision. His visual acuity dropped to counting finger in the right eye. This episode of visual deterioration was associated with an

This article was accepted: 19 February 2012

Corresponding Author: Mallika Premsenthil, Faculty of Medicine and Health Sciences, University Malaysia Sarawak, Lot 77, Seksyen 22, Kuching Town Land District, Jalan Tun Ahmad Zaidi Aduce, 93150 Kuching, Sarawak, Malaysia Email: pmallika@fmhs.unimas.my



**Fig. 1a & 1b:** Fundus pictures show bilateral hyperemic disc swelling, dilated vessels on the disc, venous congestion, flame shaped hemorrhages and non-proliferative diabetic changes and macular edema.



**Fig. 2a & 2b:** Fundus fluorescence picture showing bilateral early disc hyperfluorescence with leakage into the surrounding retina.

increase in his insulin dosage from 15 units to 20 units/day. Right eye fundus again revealed marked hyperemic swollen disc and venous congestion. His vision in both the eyes remained the same in subsequent three visits.

#### DISCUSSION

The exact incidence of diabetic papillopathy is difficult to estimate due to the low number of reported cases. The first report of diabetic papillopathy was in 1971 by Lubow & Makley in T1DM patients<sup>1</sup>. Recent studies have reported

similar findings in older individuals with T2DM. The pathophysiology is not fully understood and several theories have been suggested. One such hypotheses is that it is caused by perfusion deficiency from disruption of the capillary membranes and interstitial fluid dynamics causing edema which may lead to ischemic, compressive or toxic effects to ONH<sup>2</sup>.

Common clinical features of diabetic papillopathy are: young patient, insidious onset, mild blurring or distortion of vision, normal pupil function, enlarged blind spot, unilateral or

bilateral disc swelling with superficial dilated telangiectatic vessels on the disc, and disc hyperfluorescence with late leakage in fluorescein angiography (FA). Acute presentation of diabetic papillopathy is an uncommon finding. In this patient the severe perfusion deficiency associated with chronic hyperglycemia may be the cause for the sudden onset.

Though diabetic papillopathy is a diagnosis of exclusion, a detailed evaluation is imperative to rule out other causes of optic disk swelling. Laboratory evaluation includes: fasting blood sugar, HbA1c, visual fields, FFA, blood pressure, complete blood count, ESR, C reactive protein, fluorescent treponemal antibody test and neuro-imaging.

Current accepted criteria for the diagnosis of diabetic papillopathy include: confirmed diagnosis of diabetes (type 1 or type 2), optic disc oedema, and absence of substantial optic nerve dysfunction, normal ICP and lack of nerve inflammation, infection, or infiltration<sup>3</sup>. Cardinal features of NAION are: older patient, acute onset, visual impairment, RAPD, pallid disc swelling, attenuated peripapillary vessels, hypo fluorescence or filling defects in FA, and subsequent optic atrophy<sup>2</sup>. Apart from NAION, papilloedema is another important differential diagnosis for bilateral disc oedema especially in young patient. In our patient, papilloedema was ruled out for the following reasons: acute loss of vision in contrast to transient obscuration of vision, presence of APD, absence of symptoms and signs of raised ICP and normal neurological examination.

There is no definitive treatment for diabetic papillopathy, as in most instances the disc edema resolves within a few months with no visual impairment. Mansour et al reported the beneficial effects of periocular steroids in the

management of diabetic papillopathy<sup>4</sup>. Periocular corticosteroids stabilize the blood-ocular barrier at the disc and the macular and causes resolution of the disc and macular edema. The role of intravitreal anti-VEGF in the management of diabetic papillopathy has been reported in few cases<sup>5</sup>.

In patients with severe diabetes, intensive control of hyperglycemia can cause worsening of DR by closure of the small retinal vessel that were narrowed but previously patent. In our patient increase in the dosage of his insulin caused a sudden deterioration of his existing diabetic papillopathy. In conclusion, though diabetic papillopathy has been considered a benign optic neuropathy there might be a correlation between the patient's glucose level and the visual prognosis.

**ACKNOWLEDGEMENT**

We would like to thank all the staff involved in this patients care.

**REFERENCES**

1. Lubow M, Makley TA Jr. Pseudopapilledema of juvenile diabetes mellitus. *Arch Ophthalmol* 1971; 85: 417-22.
2. Slagle WS, Musick AN, Eckermann DR. Diabetic papillopathy and its relation to optic nerve ischemia. *Optom Vis Sci.* 2009 Apr; 86(4): e395-403.
3. Arnold AC. Ischemic optic neuropathy. In: Miller NR, Newman NJ, eds. *Walsh and Hoyt's Clinical Neuro-Ophthalmology*, 6th ed. Philadelphia: Lippincott Williams & Wilkins; 2005: 377-8.
4. Mansour AM, El-Dairi MA, Shehab MA, Shahin HK, Shaaban JA, Antonios SR. Periocular corticosteroids in diabetic papillopathy. *Eye (Lond)*. 2005 Jan; 19(1): 45-51.
5. Al-Dhibi H, Khan AO. Response of diabetic papillopathy to intravitreal bevacizumab. *Middle East Afr J Ophthalmol.* 2011 Jul; 18(3): 243-5.