

Internal Iliac Artery Pseudo aneurysm Occlusion Using Amplatzer Vascular Plug

Kumara Guru, MD, MS (Surgery), Mazri Yahya, MBBS, MS (Surgery)

Hosp Kuala Lumpur, Dept of Surgery, Hosp Kuala Lumpur, Jalan Pahang, Kuala Lumpur, Wilayah Persekutuan 50586 Malaysia

SUMMARY

Pseudoaneurysm of the internal iliac artery is a rare occurrence. Our patient presented with pain over the lower abdomen which also radiated to the back. An Angiogram of the aorta and the iliac arteries showed a pseudoaneurysm of the right internal iliac artery which measured about 8 x 8 cm with a proximal branch of the internal iliac artery distended. Initial efforts of trying to embolize the pseudoaneurysm revealed that there was a connection between the pseudoaneurysm and the internal iliac vein where foam was getting dislodged into the venous system. Subsequently, we decided to use a vascular plug which has just been recently being introduced. Post procedure there was no more flow into the right internal iliac artery pseudoaneurysm.

INTRODUCTION

Pseudoaneurysms of the internal iliac artery is a rare occurrence. There have not been many reported cases in the literature till now. Previously the treatment modality for this was to do open surgery by dissecting and ligating the pseudoaneurysm. We feel that this procedure can increase the morbidity and mortality of these patients especially as the pseudoaneurysm is in a very difficult and non accessible area of the human body. The advent of endovascular stent technology, various novel approaches have been described to reduce the complication rates. We present a case of internal iliac artery pseudoaneurysm occlusion using a vascular plug by endovascular method.

CASE REPORT

A 60 year old lady presented with pain over the lower abdomen and radiated to the back. The pain has been increasing in severity for the past 4 months. She has a background medical history of hypertension which is well controlled and had undergone bilateral tubal ligation 20 years ago.

Patient initially sought treatment at the Queen Elizabeth Hospital in Kota Kinabalu. She presented to the surgical clinic with the complaint of dysuria and 1 episode of hematuria. Per rectal examination revealed a pulsatile mass outside the rectum. Ultrasound of the urinary system was normal but revealed a right iliac aneurysm. Proceeded with a CT angio of the abdomen which revealed a right iliac arteriovenous fistula with an aneurysm and an ectatic aorta. She was later seen by

the visiting vascular surgeon and was transferred to Hospital Kuala Lumpur for further management.

We proceeded with an angiogram which showed a pseudo aneurysm arising from the right internal iliac artery which measured about 8 x 8 cm and the proximal part of the right internal iliac artery was distended. There was also a communication into the right internal iliac vein thus confirming the presence of a arteriovenous fistula. Initial efforts trying to embolize the pseudo aneurysm was unsuccessful as the foam that was used for the embolization procedure was dislodging into the low pressure venous system. Due to this difficulty that we faced, we decided to use the Amplatzer II vascular plug to try and occlude the internal iliac pseudo aneurysm.

We used a size 16mm vascular plug using a 8 Fr delivery system. This was done under local anesthesia and the whole process took less than 1 hour. Post procedure showed that there was no more flow into the right internal artery pseudo aneurysm. Subsequently the patient was sent back to the surgical ward for observation and was discharged well on day two post procedure.

DISCUSSION

Isolated internal iliac pseudo aneurysms are rare and accounts to about 0.4% of all intra abdominal aneurysms, but their

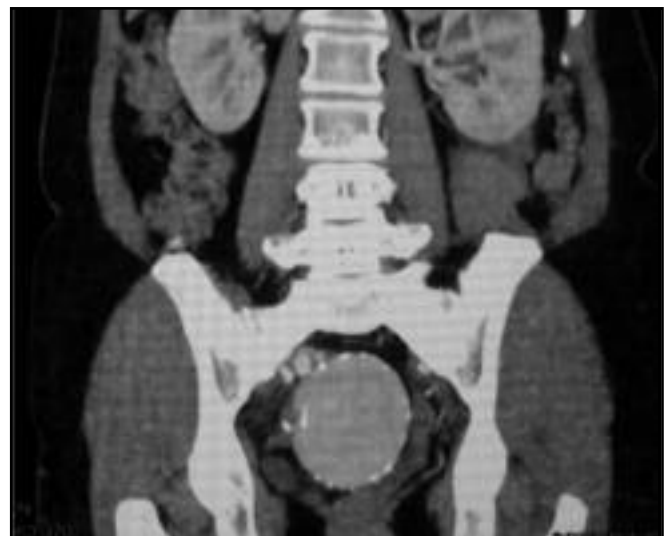

Fig. 1: CT angio of the abdomen reveals the right internal iliac.

This article was accepted: 12 September 2011

Corresponding Author: Kumara Guru, Hosp Kuala Lumpur, Dept of Surgery, Hosp Kuala Lumpur, Jalan Pahang, Kuala Lumpur, Wilayah Persekutuan 50586 Malaysia Email: guru1604@gmail.com

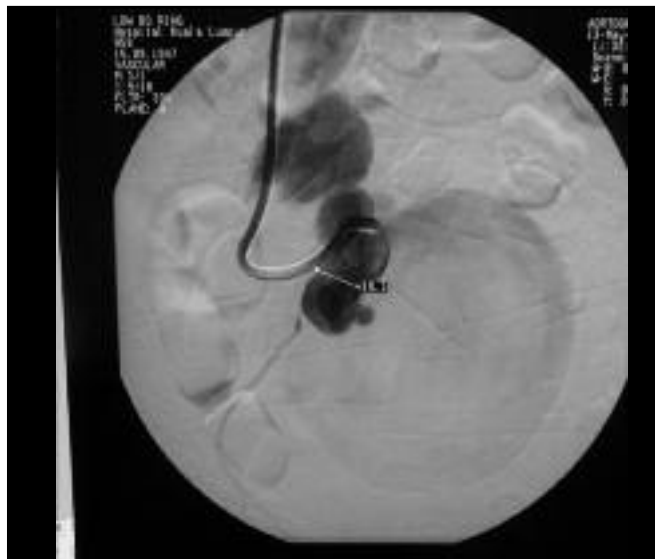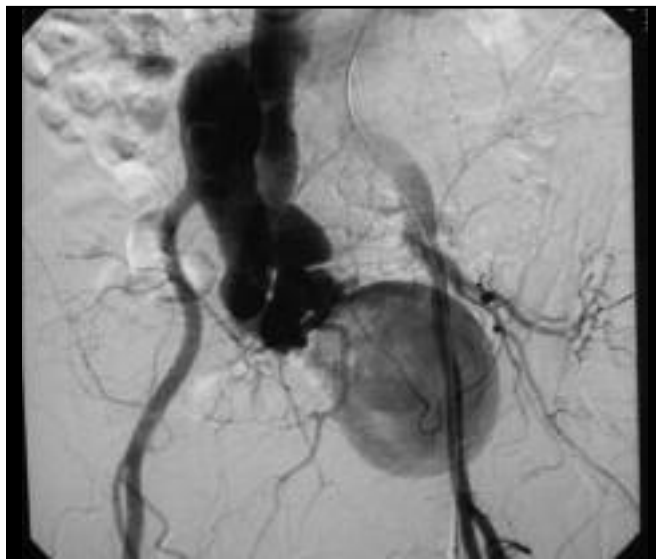


Fig 2: Angiogram of the right internal iliac artery pre and post deployment of the vascular plug. Post procedure angiography shows that the aneurysmal sac is not visualized. The ostium of the right internal iliac artery has been totally occluded.

prognosis is guarded. Brin and Busuttill have reported a 67% incidence of rupture, with 90% mortality in untreated patients. Early diagnosis and exclusion of the aneurysm is imperative to avoid this outcome. For this reason, less invasive alternatives have been developed, including combined interventional and surgical techniques and exclusively transluminal approaches.

This is because the internal iliac artery is situated deep in the deep pelvic region where there are a lot of vital structures surrounding it. This poses an increased risk of intraoperative injuries to occur if open surgery was to be done. This greatly increases the morbidity and mortality of the patient.

As it is shown in this case presentation, the insertion of a vascular plug and creating an occlusion at the ostium of the internal iliac artery, is equivalent to proximal surgical ligation. The Amplatzer surgical plug has been used widely in cardiac related cases as in Patent Ductus Arteriosus and also other areas where the access of the major vessels are reduced. Another complication that is reduced by using the vascular plug compared to conventional coil embolization is buttock claudication.

CONCLUSION

Internal iliac pseudo aneurysm is a rare presentation and can be effectively treated with a Amplatzer vascular plug which is equivalent to surgical ligation and with better results in term of reduced morbidity and mortality.

REFERENCES

1. Cynamon J, Lerer D, Veith F *et al.* Hypogastric artery coil embolization prior to endoluminal repair of aneurysms and fistulas complication. *J Vasc Interv Radiol*, 2000, 11: 573-7.
2. Wyers MC, Schermerhorn ML, Fillinger MF *et al.* Internal iliac occlusion without coil embolization during endovascular abdominal aortic aneurysm repair. *J Vasc Surg*, 2002, 36: 1138-45.
3. HA CD, Calcagno D. Amplatzer Vascular Plug to occlude the internal iliac arteries in patients undergoing aortoiliac aneurysm repair. *J Vasc Surg*, 2005, 42: 1058-62.
4. Kritpracha B, Pigott JP, Price CI, Russell TE, Corbey MJ, Beebe HG. Distal internal iliac artery embolization : a procedure to avoid. *J Vasc Surg*, 2003, 37: 943-8.