

CASE REPORT

Proptosis: A Rare Presentation of Metastatic Renal Cell Carcinoma

C C K Ho, MS, K K Krishna, MD, S Praveen, MS, E H Goh, MS, B C Lee, MS, M Z Zulkifli, MS

Urology Unit, Department of Surgery, Universiti Kebangsaan Malaysia Medical Centre, Jalan Yaacob Latif, Bandar Tun Razak, 56000 Cheras, Kuala Lumpur, Malaysia

SUMMARY

We present a case of a middle-aged man who was incidentally found to have right renal solid mass while investigating for his left eye proptosis. Computerised tomography (CT) scan confirmed the diagnosis of renal cell carcinoma and the tumour was successfully excised via open surgery. The histopathology examination revealed the 10x7x8 cm mass to be a clear cell type renal cell carcinoma. The rare presentation of this metastatic renal cell carcinoma, its diagnosis and management will be discussed.

KEY WORDS:

Proptosis, Metastasis, Renal cell carcinoma, Orbit

INTRODUCTION

Renal cell carcinoma (RCC), a tumour originating from the renal cortex, accounts for 2% of all systemic malignancies but constitutes over 80% of all malignant renal tumours¹. RCC has been reported to occur nearly twice as often in men as in women and predominantly occurs in their seventh and eighth decades of life. About 30% of patients have overt metastasis at the time of initial diagnosis of RCC with the most common sites of involvement being lung parenchyma, bones, liver and brain¹. Metastatic lesions to the orbit are a rare but important cause of orbital disease². In this report, we describe a rare case of renal cell carcinoma with orbital metastasis as the presenting complaint.

CASE REPORTS

A 40 year old gentleman developed a painless proptosis and redness of his left eye for 3 months (Figure 1). He had no diplopia, no history of trauma, or any underlying systemic disease. His visual acuities were 6/6 bilaterally and had limitation of left eye movement on upward gaze. The pupils were 3mm, reactive to light, with no relative afferent pupillary defect. The rest of the eye examination was normal.

Computed tomography (CT) scan of the orbit and brain showed an enhancing lesion arising from the left superior rectus muscle, measuring 2.9 x 1.5 cm (Figure 2). Initial clinical impression was lymphoma. However, on further questioning, he revealed that he had a few episodes of frank haematuria as well. Ultrasound of the abdomen was done and it showed a right renal solid mass. CT scan of the abdomen revealed a heterogeneously enhancing mass measuring 9.4x7.6x10.4 cm in the mid and lower poles of right kidney

with liver metastasis. CT scan of the thorax showed bilateral lung metastasis. The technetium-99m bone scan showed no evidence of skeletal metastasis.

Nephrectomy was performed. Intraoperatively, the renal mass measured 10x7x8 cm. Patient was extubated postoperatively and nursed in the ward. His postoperative recovery was uneventful and was discharged well after 5 days.

Histopathological examination revealed the mass as renal cell carcinoma, clear cell type, Fuhrman's Grade 2. External beam radiotherapy comprising 5 fractions of 20 Gy was given to the affected orbit. He was then sent to the oncologist for sunitinib therapy.

DISCUSSION

Metastasis is a rare cause of a mass in the orbit, comprising 3-7% of cases¹. It is more likely to be found in elderly individuals, the mean age of the patients in different series being around 60 years, with patients most commonly presenting with proptosis or diplopia¹. The most common sources for orbital metastases are carcinoma breast in women and carcinoma lung and prostate in men². Orbital metastases from renal cell carcinoma, however, are rarely reported.

The ocular signs and symptoms which accompany orbital tumours usually appear rather suddenly due to rapid progression of most metastases which leads to local infiltration and entrapment of structures². The orbit was the most frequently involved site by metastatic renal cell carcinoma (36.8%), followed by the choroids (29.4%). Other structures reported were the iris, ciliary body, lacrimal gland, conjunctiva, eyelid, eyebrow and extraocular muscles¹.

Because the eye has no lymphatic channels, all orbital metastases are from haematogenous spread and therefore must transmit through the lung. Thus, pulmonary metastases typically accompany orbital metastases, and the lung is particularly an important site to investigate in these patients³.

In most cases, the orbital metastasis occurred 7-15 years after the diagnosis of renal cell carcinoma¹. However, there are cases where the orbital metastases precede the diagnosis of renal cell carcinoma, as happened to our patient. We were fortunate that there was a history of haematuria which led us to investigate the urinary system with imaging which subsequently revealed the renal cell carcinoma. In cases

This article was accepted: 19 November 2010

Corresponding Author: Christopher Ho Chee Kong, Department of Surgery, Universiti Kebangsaan Malaysia Medical Centre, Jalan Yaacob Latif, Bandar Tun Razak, 56000 Cheras, Kuala Lumpur, Malaysia Email: chriskho2002@yahoo.com

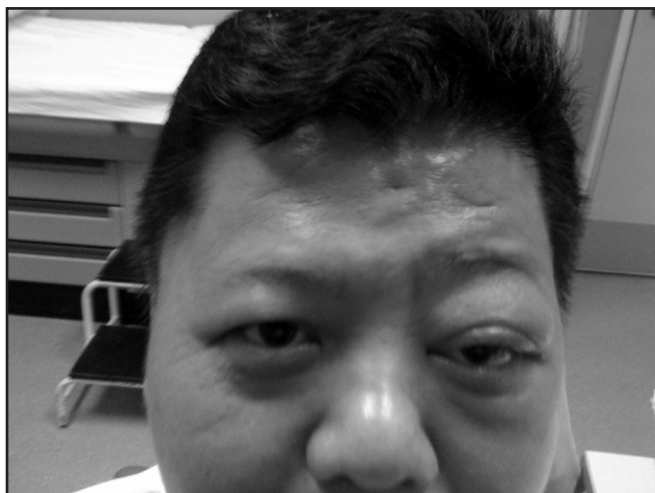


Fig. 1: Proptosis of the left eye
*written consent has been obtained from the patient

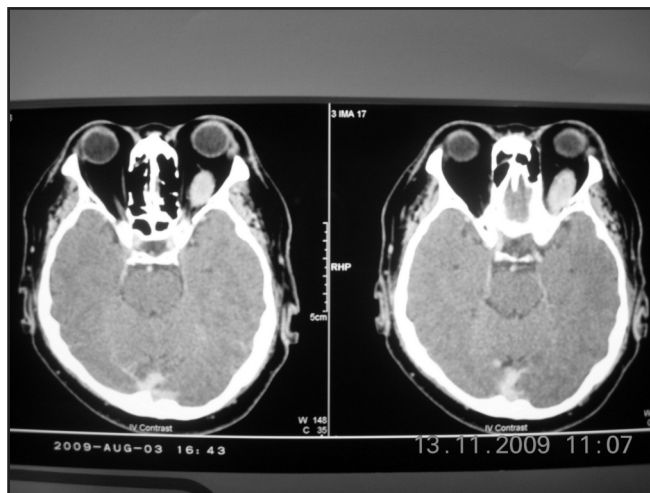


Fig. 2: Computerised tomography scan of the orbit and brain showing an enhancing lesion arising from the left superior rectus muscle.

where the primary is not known, biopsy of the orbital tumour is necessary for diagnosis. Since our patient was already having haematuria, removal of the offending lesion, which was the renal cell carcinoma, via nephrectomy was indicated. The presence of multiple liver and lung metastasis with a renal tumour, makes it highly logical that the orbital tumour is a metastasis, rather than a primary tumour with multiple metastasis. This renders biopsy of the orbital tumour as unnecessary. CT scan of the orbit and brain showed involvement of the extraocular muscle. Primary tumour of the extraocular muscle is very rare as opposed to metastasis to the extraocular muscle⁴. Several patterns were thought to be very typical for orbital metastases. These included intramuscular focal mass, involving the extraocular muscle⁵. All these features supports the diagnosis of orbital metastasis rather than primary orbital tumour.

Nephrectomy is generally recommended for palliation of symptoms. The orbital metastasis can be treated with external beam radiotherapy, excision, enucleation or evisceration¹. In our patient, since there was already other metastasis in the lung and liver, we palliated his symptoms only with radiotherapy to the orbit.

In conclusion, physicians should be aware that one of the differential diagnosis of proptosis is orbital metastasis. Orbital metastasis of renal cell carcinoma is rare but may be the first clinical manifestation preceding the diagnosis of primary tumour. Therefore, a thorough history and physical examination is imperative so as not to miss the diagnosis.

REFERENCES

1. Debraj S, Santosh GH, Pankaj G. Metastasis to the Eye and Orbit from Renal Cell Carcinoma- A Report of Three Cases and Review of Literature. *Surv Ophthalmol.* 2007; 52: 213-23.
2. Passorn P, Shantha A, Chee CY. Orbital Metastasis of Renal Cell Carcinoma Masquerading as Cysticercosis. *Orbit.* 2008; 27: 370-73.
3. Ellen SH, Richard JM. Renal Cell Carcinoma Metastatic to the Orbit. *Clinical Eye and Vision Care.* 1998; 10: 99-101.
4. Lacey B, Chang W, Rootman J. Nonthyroid causes of extraocular muscle disease. *Surv Ophthalmol.* 1999; 44(3): 187-213.
5. Char DH, Miller T, Kroll S. Orbital metastases: diagnosis and course. *Br J Ophthalmol* 1997; 81: 386-90.