

# The Use of Paramedian Forehead Flap Reconstruction after Wide Excision of Basal Cell Carcinoma of the Nose

Y K Chew, MBBS, Y Noorizan, MBBCh, A Khir, MS, S Brito-Mutunayagam, MS, N Prepagaran, FRCS

Department of Otorhinolaryngology, Hospital Pakar Sultanah Fatimah, 84000 Muar, Johor, Malaysia

## SUMMARY

Basal cell carcinoma (BCC) is an indolent, slow-growing malignant skin tumour. Approximately 70% of the tumours occur in the head and neck region. The nose is a common site for malignant skin tumours, such as basal cell carcinoma and squamous cell carcinoma because it is exposed to the sun. Excision of the BCC will leave the nose with a soft tissue defect which requires reconstruction. This report illustrates a case of BCC of nose whereby a wide excision and reconstruction was performed with a paramedian forehead flap.

## KEY WORDS:

*Basal cell carcinoma, Paramedian forehead flap*

## INTRODUCTION

The nose is the most prominent feature of the human face, therefore, any defect will be noticeable. Wide excision of the BCC of nose will leave a soft tissue defect of soft tissue and sometimes part of the skeleton may be exposed too. Reconstruction is an integral part of the surgery to bring the tissue that matches well with the uninvolved skin both in structure and colour. The paramedian forehead flap is the most popular flap as it has most of the characteristic required for the ideal nasal reconstruction.

## CASE REPORT

A seventy-nine-year old lady was referred to our clinic with a complain of a growth at right side of the nose for two years duration. The growth is progressively increased in size and was associated with occasional bleeding and itchiness.

On examination, the patient was comfortable. There was a 3cm x 4cm pigmented, cauliflower-like growth with irregular surface at the right nasal alar region. (Figure 1a). Biopsy was taken from the lesion and the histopathological examination revealed basal cell carcinoma.

The patient underwent wide excision with reconstruction of the nose using a paramedian forehead flap under general anaesthesia. Intraoperatively, wide excision of the basal cell carcinoma was performed exposing the cartilage. Paramedian forehead flap was harvested and separated from the periosteum of the skull. The flap then rotated to cover the defect with the pedicle intact (Figure 1b). The donor site was closed primarily.

Post-operative recovery was uneventful. Two weeks postoperatively, the donor and recipient site had healed. The pedicle of the flap was clean. Release of pedicle and closure of wound was done a month later. During the follow up, two months postoperatively, the forehead flap had healed well (Figure 1c).

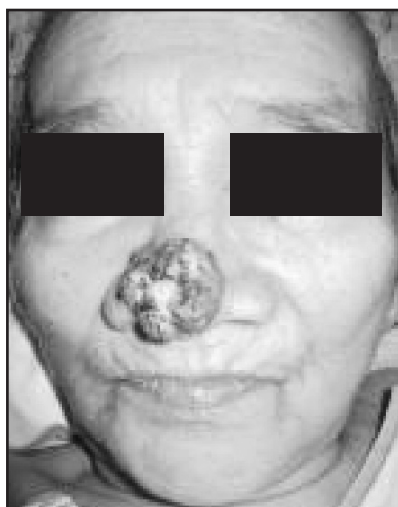

Fig. 1a: Growth of carcinoma at the nose

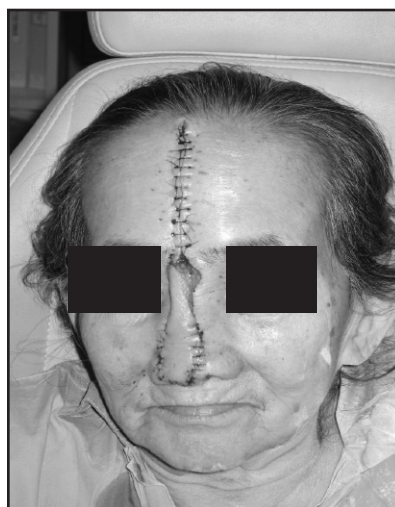


Fig. 1b: Paramedian forehead flap in-situ

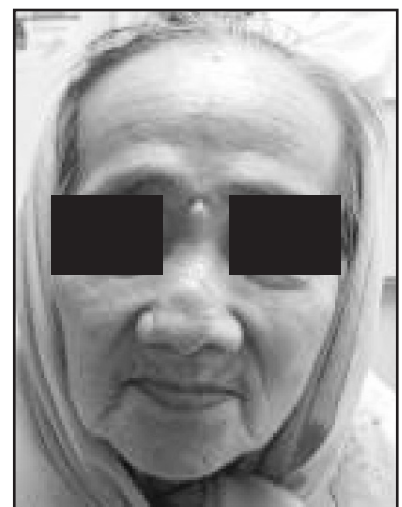

Fig. 1c: On 2-month follow-up, wound healed with minimal scar

This article was accepted: 27 August 2008

Corresponding Author: Chew Yok Kuan, Department of Otorhinolaryngology, Hospital Pakar Sultanah Fatimah, 84000 Muar, Johor, Malaysia

Email: chewyokkuan@gmail.com

## DISCUSSION

Basal cell carcinoma is an indolent, slow-growing tumour. Approximately 70% of this tumour occur in the head and neck region. Wide excision of the BCC is an accepted approach in managing the primary tumor. The reconstruction of the nose is important to prevent exposure of the underlying soft tissue and cartilage, as well as for aesthetic reasons.

There are wide variety of defect closures which include free skin graft, local flaps and regional flaps. According to Gertrude, 1998 free skin grafts are generally rejected because of their poor colour and texture match and their inability to fill the defects satisfactorily, especially in areas of thick, sebaceous skin of the nose where free skin grafts are ugly. Local flaps such as V-Y flaps, Z-flaps and transposition flaps are only suitable for closure of small to median-sized nasal defects. Therefore regional flaps, for example paramedian forehead flap is the most suitable option for closure of large defect in this case.

Quatela, 1995 had used the paramedian forehead flap for the defects larger than 1.5cm to 2cm. The defect as in this case is 3cm to 4cm and therefore the paramedian forehead flap was preferred. Menick, 1990 has recommended that the forehead flap need to be tailored to match the nasal defect exactly to prevent collapse of the support when it is too tight or bulging when it is too loose. We performed this tailoring intraoperatively on the site of the defect in order to give us a precise reconstruction.

Closure of the donor site is the main concern in these cases. Failure of closure will leave the patient with scarring and defect at the forehead which is cosmetically unacceptable. Primary closure is the ideal way to deal with the donor site as it ensures minimal scarring and almost perfect wound healing as in this case. However, in some cases this cannot be achieved because of the width of the flap needed. In those cases, the wound will be left open for secondary healing and this can resulting in wide and depressed scars. Hence, in this case, we had closed the donor site with Dafilon suture to promote primary healing. Conley and Price, 1981 described that closing the donor site primarily the donor area gives the best aesthetic result and allows future reharvesting of the flap.

## CONCLUSION

Wide excision of basal cell carcinoma of the nose and reconstruction with paramedian forehead flap has the advantage of being a good matching of skin colour and texture. The dissection of the flap under direct vision is safe and on-site design of the flap can give a precise dimension as required. Primary closure of donor site is easy and without scarring.

## REFERENCES

1. Conley JJ, Price JC. The midline vertical forehead flap. *Otolaryngol. Head Neck Surg.* 1981; 89: 38.
2. Gertrude MB. Closure of nasal defects after tumor excision with local flaps. *Aesth Plast Surg.* 1998; 22: 42-7.
3. Menick FJ. Aesthetic refinements in use of forehead for nasal reconstruction: The paramedian forehead flap. *Clin. Plast. Surg.* 1990; 17: 607.
4. Quatela VC, Sherris DA, Rounds MF. Esthetic refinements in forehead flap nasal reconstruction. *Arch. Otolaryngol. Head Neck Surg.* 1995; 1221: 1106.