

# Infective Endocarditis in Pregnancy Complicated by Septic Embolization to the Cerebellum

H J Tan, MRCP, R Rabani, MBChB, S Noorfaizan, MRCP

Department of Medicine, Faculty of Medicine, Hospital Universiti Kebangsaan Malaysia, Jalan Yaacob Latif, Cheras 56000 Kuala Lumpur

## SUMMARY

This report describes a pregnant lady in early trimester that was admitted with fever and left loin pain and was initially treated as presumed pyelonephritis. Subsequently she was found to have infective endocarditis with vegetation on the mitral valve. The course of her illness was complicated by acute pulmonary edema and septic embolization to the cerebellum. A decompressive craniectomy and resection of the lateral lobe of cerebellum was performed. Although the presenting features and risk factors are well described, the atypical presentations of infective endocarditis in pregnancy remain a diagnostic challenge for the treating physician. This report highlights the importance of rapid detection of endocarditis in pregnancy and the treatment of systemic complications.

## INTRODUCTION

The incidence of infective endocarditis in pregnancy is about 0.006%.<sup>1</sup> Despite advances in the diagnosis and management, it still carries a high mortality from complications of heart failure and embolic events. Atypical presentations may delay the diagnosis and management of infective endocarditis. Systemic embolisation is a frequent complication of infective endocarditis despite adequate antibiotic therapy. Treatment includes eradication of the microorganism as well as managing the systemic complications. The following report will describe a pregnant lady with infective endocarditis complicated by septic embolisation to the cerebellum.

## CASE REPORT

A 22-year-old lady in her first pregnancy at 12 weeks, presented with fever of 4 days prior to admission which was associated with back pain, myalgia, arthralgia, and vomiting. Examination revealed blood pressure 106/96 mm Hg, pulse rate 154 beats/min, respiratory rate of 20/min and temperature 38 Celcius. Apart from right subconjunctival haemorrhage, the rest of the peripheral examination was normal. There was left loin tenderness but no organomegaly. The heart and lungs were normal.

Investigations revealed the hemoglobin 11 g/dl, total white cell count  $20 \times 10^9$  (predominantly neutrophils) and platelets  $21,000/\text{mm}^3$ . The renal and liver function tests were normal. The erythrocyte sedimentation rate 120 mm/hr and C-reactive protein 8.7 mg/dl (elevated). Septic work-out was

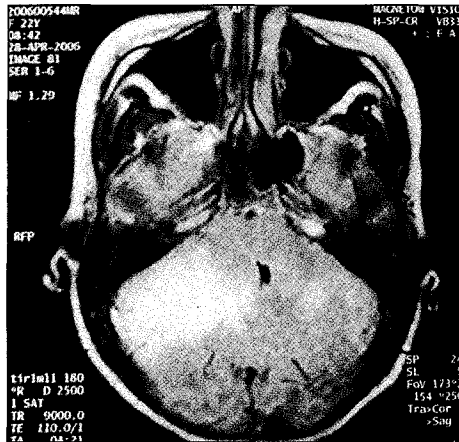
negative. Urine microscopy examination revealed microscopic haematuria. She was treated empirically for pyelonephritis with intravenous cefuroxime. However, her temperature continued to spike despite antibiotic therapy and she remained tachycardic. An echocardiography revealed a vegetation at the mitral valve about  $1\text{cm}^2$ . Intravenous penicillin 2 MU 4 hourly and Gentamicin 120 mg daily was commenced for the treatment of infective endocarditis. On day 5 of admission, she developed two episodes of generalized tonic clonic seizures and her Glasgow coma score dropped to 11/15. A brain MRI revealed multiple hyperintense lesions in the right cerebellum with hydrocephalus consistent with septic emboli involving branches of the basilar artery. An emergency extraventricular drainage was inserted. She remained seizure free following the operation and the Glasgow coma score had improved to 15/15. However, two days post EVD insertion, she developed acute respiratory distress which was evidenced by a drop in oxygen saturation and generalized crepitations in the lungs. She was treated for acute pulmonary edema with high flow oxygen therapy, intravenous frusemide and ventilatory support for respiratory failure. A repeat echocardiography showed a prolapsed anterior mitral valve with moderate mitral regurgitation and vegetation on the mitral leaflet. There was no rupture of chordae tendinae, aortic root abscess, thrombus or pericardial effusion. A repeat MRI brain showed progression in the cerebellar lesions with edema and compression of the 4th ventricle (Figure 1). She underwent a decompressive posterior fossa craniectomy. Intraoperatively, the cerebellum was very tight and highly vascularised. The lateral lobe of the cerebellum was resected. Histopathologically, there was liquefactive necrosis and suppuration of the cerebellar tissue (Figure 2). She was gradually weaned off the ventilator and her neurological status improved. Serial scans of the fetus revealed normal fetal growth. She completed two weeks of gentamicin and eight weeks of penicillin. There was an improvement in the white cell count and inflammatory markers. Regular echocardiography demonstrated reduction and finally resolution of the vegetation. She delivered her baby via elective Caesarean section and was planned for a valve replacement at a later date.

## DISCUSSION

The presentation of infective endocarditis can be variable but the triad of fever; anemia and heart murmur has been described<sup>2,4</sup>. Fever was the presenting complaint in this

This article was accepted: 21 March 2007

Corresponding Author: Tan Hui Jan, Department of Medicine, Hospital Universiti Kebangsaan Malaysia, Jalan Yaacob Latif, Cheras 56000 Kuala Lumpur



**Fig. 1:** Axial MRI brain (FLAIR sequence) showing hyperintense lesion in the right cerebellum with compression of the 4th ventricle and brainstem



**Fig. 2:** Histopathology of the cerebellum showing liquefactive necrosis and suppuration

patient. A fever above 38 Celcius is found in 85 to 96% of patients diagnosed with IE and is usually the first presenting symptom. Heart murmurs may be absent in 24% of patients with IE on initial presentation. Subacute IE presents with anorexia, weight loss, malaise and night sweats. Non-specific symptoms such as weakness, myalgias, dyspnea, fatigue and thoracic pain have been reported. Back pain has been reported in a patient with IE, which was complicated by an epidural abscess<sup>3</sup>. The presence of tachycardia, subconjunctival haemorrhage and microscopic haematuria in this patient were supportive of the diagnosis of IE.

The prediction of individual patient risk for embolisation depends on various factors. Studies has demonstrated higher embolic rates with left sided vegetation that is more than 1cm in diameter<sup>5,6</sup>. The mortality rate is increased with mobile vegetations of more than 15 mm in size. The highest risk occurs in the first few days and drops after two weeks<sup>5</sup>. Certain microorganisms such as Staphylococcus, Streptococcus bovis and Candida species are associated with an increase risk of embolisation. Although this patient had no risk factors for IE, she had increased risk of embolisation as the vegetation in the mitral valve was more than 10 mm.

The development of acute pulmonary edema required urgent cardiac evaluation to exclude the possibility of ruptured chordae tendinae or papillary muscles, acute mitral regurgitation, aortic root abscess, extension of infection into the septum leading to arrhythmias, fistula formation or cardiac tamponade. Neurogenic pulmonary edema can occur as a result of the septic emboli to the brain.

Neurologic complications of IE develop in 20-40% of all cases with IE<sup>2,5</sup>. These complications are the result of either cerebral embolism or infarction, rupture of a mycotic aneurysm, meningitis or brain abscess. Septic embolisation occurred in the branches of the basilar artery in our patient is unusual as more than 90% of central nervous system emboli lodge in the distribution of the middle cerebral artery territory. The involvement of the cerebellum causes compression of the 4th ventricle with resultant obstructive hydrocephalus requiring decompression craniectomy and resection of the lateral lobe of cerebellum.

This case illustrates that rapid detection of endocarditis in pregnancy and treatment of systemic complications is important in reducing the risk of maternal and fetal mortality.

**REFERENCES**

1. Montoya ME, Karneth BM, Ahmed M. Endocarditis during pregnancy. Southern Med J 2003; 96 (11): 1156-7.
2. Mylonakis E, Calderwood SB. Medical progress: Infective endocarditis in Adults. NEJM 2001; 345(18): 1318-330.
3. Gordon PR, Allen SA. Atypical infective endocarditis. J Am Board of Fam Pract 1999; 12 (5): 391-4.
4. Calkins TR, Vaca FE. Atypical presentation of infective endocarditis: case report and literature review. Topics in Emerg Med 2000; 22(4): 58-64.
5. Habib G. Management of infective endocarditis. Heart 2006; 96: 124-30.
6. Baddour LM, Wilson WR, Bayer AS *et al.* Infective endocarditis. Circulation 2005; 111: c394-c433.