

Underlay Myringoplasty: Comparison of Human Amniotic Membrane to Temporalis Fascia Graft

S Harvinder, MMed (ORL-HNS)**, S Hassan, MCPS*, D S Sidek, MS (HN ORL)*, M Hamzah, MS (HNORL)*, A R Samsudin, FDS*, R Philip, MMed (ORL-HNS)*

Department of ORL & HNS, School of Medical Sciences, Universiti Sains Malaysia, Kubang Kerian, Kelantan, Jabatan ENT, Hospital Ipoh, Jalan Hospital, 30990, Ipoh, Perak

Summary

Human amniotic membrane as a homograft material was compared to temporalis fascia to close tympanic membrane perforations in 50 patients with chronic otitis media. Human amniotic membrane was used in 20 patients while temporalis fascia was used in the remaining 30. Anatomical closure of the perforation and reduction of the air-bone gap was measured. The graft uptake showed a 65% success rate for the amniotic membrane and 56.7% for the temporalis fascia at 3 months post-operatively. Significant closure of air-bone gap was observed in the human amniotic group. These results indicate comparable outcomes between human amniotic membrane and the temporalis fascia graft.

Key Words: Myringoplasty, Homograft, Amniotic Membrane, Temporalis Fascia, Underlay technique

Introduction

A variety of graft materials such as allografts, homografts, and heterografts have been used to cover the defects of tympanic membrane. Commonly, autograft materials such as temporalis fascia, tragal perichondrium, vein and fat are used. The choice of graft material depends on availability, preservability, manageability and acceptability to the host¹. Preserved human amniotic membrane graft satisfies the criteria mentioned above. In addition, it has low antigenicity, does not show allergic or immunologic reactions and has antimicrobial property^{2,3}. The use of a preserved graft will also reduce the need for general anaesthesia and operating time.

Materials and Methods

This is a prospective controlled study of 50 myringoplasties performed by the Otolaryngology

Head and Neck Surgery Department of University Sains Malaysia Hospital in Kubang Kerian, Kelantan, from June 1999 to June 2001. The objectives of this study was to evaluate the efficacy of preserved human amniotic membrane as an alternative graft material in terms of its anatomical and functional outcomes in closing tympanic membrane defects during myringoplasties. We compared it with the standard temporal fascia graft. The ethical committee of Universiti Sains Malaysia granted permission for this study to be carried out.

Patients were divided into two groups. One group used human amniotic membrane while the other group temporalis fascia. The choice of graft material used was explained in detail to each individual patient, including the advantages, disadvantages and the risk of disease transmission. Informed consent was taken from all patients using the standard consent forms in our hospital. The surgery for repairing the defects of

This article was accepted: 28 June 2005

Corresponding Author: Harvinder Singh, Jabatan ENT, Hospital Ipoh, Jalan Hospital, 30990, Ipoh, Perak

tympanic membrane was performed by senior surgeons using underlay technique under general anesthesia.

Selection of patients in this study was based on strict inclusion and exclusion criteria's. Only patients with an etiologic diagnosis of chronic suppurative otitis media were included. The ear must have been dry for at least 3 months with evidence of an air-bone gap. Patients with active ear discharge, previous myringoplasties or mastoidectomies, on going ossicular and mastoid pathologies were excluded.

The size of tympanic membrane perforations was defined specifically for this study. Small perforations involved at least two quadrant of the tympanic membrane or when considered as a percentage is less than 50%. Medium sized perforations involved at least 3 quadrants or more than 50% but less than 75%. Subtotal perforation involves all four quadrants or more than 75% but less than 100% (total).

In this study, the amniotic membranes were obtained from donors undergoing normal vaginal delivery and caesarian sections. There is no age limit for the donors and donor's written consent is necessary. All donors were screened for Hepatitis B and C, syphilis and HIV. They must have no history of transmissible diseases like syphilis, gonorrhoea, toxoplasmosis, cytomegalovirus and AIDS. The amnion will only be procured if the membranes has ruptured less than 12 hours before delivery.

The amniotic membrane will then be subjected to various cleaning processes and then dried using laminar airflow and subsequently freeze dried to ensure better physical properties. Sterilization of these processed human amniotic membrane was performed at Tenaga Nuklear Unit (UTN) in Bangi, Selangor using Gamma Irradiation-2.5 Megarads. The duration for valid usage of this lyophilised and air-dried amnion is one year.

The surgical approach was permeal, endaural or postauricular but the technique was limited to underlay or underlay through perforation. Audiometric evaluation was carried out in a soundproof room with a diagnostic audiometer. Pure tone thresholds were obtained using earphones, and the average of the three frequencies tested (0.5, 1 and 2 kHz) was used to calculate the mean air conduction, mean bone conduction and mean air-bone gap.

Postoperative results were evaluated with respect to the anatomic and functional outcomes. To assess anatomic results, the results were divided in terms of success or failures. Success was defined as total closure of the tympanic membrane, 3 months post-operatively. Reasons for failure like residual perforation, infections, graft lateralization or dislodgment's were identified.

The evaluation of functional outcome was based on the postoperative pure tone audiometry air-bone gap 3 months post-operatively, which was calculated from the mean postoperative air conduction threshold and the mean preoperative bone conduction threshold.

Results

The total number of cases included in this study were 50, out of which 28 are males whereas remaining 22 are females. The age ranged from 9 years to 66 years with a mean age of 32.08 years. The mean follow-up of the patients was 3 months. In the temporal fascia group, successful closure was achieved in 17 (56.7%) of 30 cases. Among the 13 failures (43.3%), 4 were due to infection, 6 due to residual perforation, 2 due to graft dislodgment and one failure due to graft lateralization. The relationship between the various sizes of tympanic membrane perforations and its postoperative anatomical outcomes in this group is shown in Table I.

In the temporal fascia group, small tympanic membrane defects achieved the highest success rate in terms of anatomical closure compared to moderate and subtotal perforations. Most anatomical failures were observed in subtotal perforations.

However, in the human amniotic membrane group, successful closure was achieved in 13 (65%) of 20 cases. There were 7 failures (35%), among which 4 cases were attributed to residual perforations, two of infection and one of graft lateralization. The relationship between the various sizes of tympanic membrane defects and its postoperative anatomical outcome in the amnion group is outlined in Table II.

In the amnion group as well, small perforations achieved the highest closure rates. In the moderate perforations group, encouraging results were obtained. As the number of cases in the subtotal perforation group was small, adequate inferences on the success of amniotic membrane in this group cannot be made at this juncture as more cases are needed for proper evaluation and justification.

The audiometric results are shown in Table III and IV respectively. In the temporal fascia and human amniotic group, there was statistically significant difference between the preoperative and postoperative mean air conduction thresholds. Again, satisfactory and significant closure of pre and postoperative air-bone gap was observed only in the human amniotic group.

In the temporal fascia group, of the 30 ears tested postoperatively, 22 ears (73.33%) demonstrated air-bone gap closure within 20 dB (Figure 1), whereas in 20 ears tested in the human amniotic group, 95% (19/20), showed air bone gap closure within 20 dB. This relationship is depicted in Figure 2.

Table I: Postoperative anatomical outcomes in various sizes of tympanic membrane defects in temporal fascia group.

Size	Cases	Success (%)	Failures (%)
Small	5	100%	0%
Medium	16	62.5% (10)	37.5% (6)
Subtotal	9	22.2% (2)	77.8% (7)

Table II: Postoperative anatomical outcomes in various sizes of tympanic membrane defects in amnion group.

Size	Cases	Success (%)	Failures (%)
Small	8	100%	0%
Medium	11	45.5% (5)	54.5% (6)
Subtotal	1	None	100%

Table III: Results of preoperative and postoperative audiometric testing (dBHL), and comparison between preoperative and postoperative thresholds in temporal fascia group using paired-T test.

	Pre-operative (30 ears)	Post-operative (30 ears)	p value
Mean air conduction threshold	39.67 ± 2.27	32.63 ± 3.26	0.003 (S)
Mean bone conduction threshold	21.13 ± 2.26	18.30 ± 1.78	0.001 (S)
Mean air bone gap	18.53 ± 1.76	14.33 ± 2.54	0.066 (NS)

NS = not significant.

S = significant

Table IV: Results of preoperative and postoperative audiometric testing (dBHL), and comparisons between preoperative and postoperative thresholds in amnion group using paired-T test.

	Pre-operative (20 ears)	Post-operative (20 ears)	p value
Mean air conduction threshold	33.80 ± 4.64	23.10 ± 4.86	0.000 (S)
Mean bone conduction threshold	17.35 ± 3.20	14.05 ± 3.49	0.010 (S)
Mean air bone gap	16.40 ± 2.14	9.05 ± 1.86	0.001 (S)

NS = not significant.

S = significant.

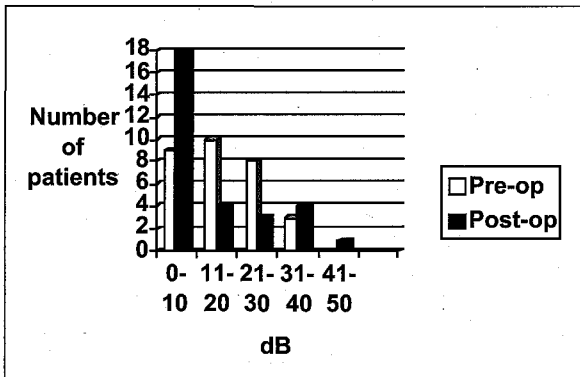


Fig. 1: Preoperative and postoperative air-bone gap in temporal fascia group

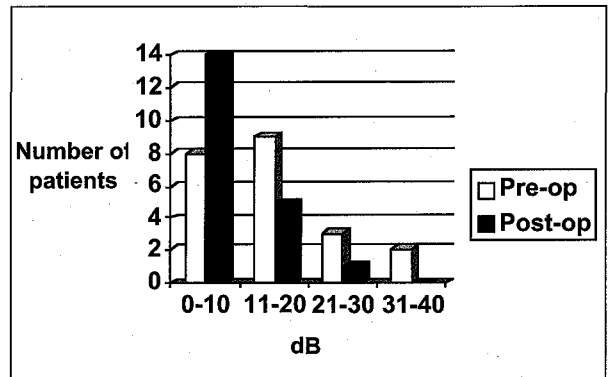


Fig. 2: Preoperative and postoperative air-bone gap in amnion group.

Discussion

The use of human amniotic membrane in surgical practice is substantial. It is used as a biologic dressing for burns⁴, in the treatment of leg ulcers⁵ and for vaginal epithelization⁶. In otolaryngology, it has been used for replacing nasal mucosa affected by hereditary telengectasia for the control of epistaxis and in cases of regional flap necrosis⁷.

Lyons et al⁸ has employed the use of 70% alcohol preserved amniotic membrane in a variety of otological procedures. In traumatic tympanic membrane repair, homologous amniotic membrane was used in 35 cases with excellent results. These cases involved tympanic membrane repair at the time of stapes surgery and in those acute perforations, which required middle ear explorations for repair of persistent perforations following trauma. However, in perforations of tympanic membrane from chronic otitis media, a 80% failure rate was reported in 20 cases in which homologous amniotic membrane was used. The only successful cases in this group were those which had small perforations. The reasons for the high failure rate in the other perforations were not elaborated by the author.

Zohar et al⁷ reported the use of fresh amniotic membrane in 7 patients undergoing tympanoplasties. Patients with only medium to subtotal perforation were selected. They all had dry ears during the procedure. The fresh amniotic grafts were cut to size, allowed to dry, and was placed with the mesenchymal surface to

the flap on antibiotic impregnated gelfoam patches and covered by a tympanomeatal flap. In this case series, 5 out the 7 patient's operated on were unsuccessful. The reasons for failure was not explained by the author.

One interesting pilot study done in Pakistan shows the effectiveness of human amniotic membrane in closing perforations in tympanoplasty⁹. In this study, freshly procured amnion was preserved in buffered formaldehyde at pH 7.4. Two patients had small perforations while 8 showed subtotal perforations. The graft was well taken in 7 out of 10 patients giving a 70% anatomical success. Closure of air-bone gap of 20 dB was achieved in 5 out 7 cases giving a functional success of 71.5%.

In our study, we achieved satisfactory anatomical results in 10 out of 15 cases in the amnion group. In these 10 successful closures, 7 were small perforations. Our results is comparable to other reported studies in the literature^{8,9}. Our success in the moderate sized perforations were very encouraging and is contrary to the work performed by Zohar and his colleagues⁷. As for our subtotal perforations, we need more data and experience on a long -term basis to assess this graft material in these group.


Conclusion

Human amniotic membrane is a suitable alternative graft material for repairing perforated tympanic

Underlay Myringoplasty: Comparison of Human Amniotic Membrane to Temporalis Fascia Graft

membranes. It is readily available in our institution, easily processed and stored and of low antigenicity. It also gives good anatomical and functional results and is comparable to the present widely used standard temporalis fascia graft material.

However, human amniotic membrane is not widely available throughout Malaysia and subjected to various cleaning and sterilization processes. It also carries a very minimal risk of transmissible infection as compared to the more readily available, inexpensive and infection free temporalis fascia graft material.

-
- 
1. Catalano GB and Conticello S. The long term results of myringoplasty with amnion graft. *Otorinolaryngologie* 1969; 14: 97-102.
 2. Matthews RN. Human tissue response to an allograft. *Lancet* 1981; 2: 1428-29.
 3. Rao TV and Chandrasekharan. Use of human and bovine amnion as a biological dressing. *Surgical* 1981; 116: 891-96.
 4. Colocho G, Graham WP, Greene AE. Human amniotic membrane as a physiologic wound dressing. *Arch Surg* 1974; 109: 370-73.
 5. Ward DJ, Bennet JP. The long term results of the use of human amniotic membrane in the treatment of leg ulcers. *Br J Plast Surg* 1984; 37: 191-93.
 6. Trancer ML, Katz M, Veridiano NP. Vaginal epithelization with human amnion. *Obstet Gynecol* 1979; 54: 345-49.
 7. Zohar Y, Talmi TP, Frankelstein T., et al. Use of human amniotic membrane in Oto-laryngologic practise. *Laryngoscope* 1987; 97: 978-80.
 8. Lyons GD, Dyer RF, Ruby JR. Morphologic analysis of tympanic membrane grafts. *Laryngoscope* 1977; 87: 1705-9.
 9. Jalisi M, Iqbal K, Ashrafi Ahmed K.S. The human amniotic membrane as a graft material in tympanoplasty. *Pakistan J Otolaryngol* 1997; 13: 11-12.