

# Neurocysticercosis an Uncommon Intra-Cerebral Infection in Malaysia

K Arasu, MS\*, A Khairul, FACTM\*\*, V Waran, FRCS\*

\*Division of Neurosurgery, and \*\*Department of Parasitology, University Malaya Medical Centre, 50603 Kuala Lumpur

### Summary

Neurocysticercosis, infection of the central nervous system (CNS) by larvae of the pork tapeworm *Taenia solium*, is the commonest neuroparasitic infection in humans. However in countries as in Malaysia it poses a diagnostic problem as the disease is not seen amongst the local population, however with the arrival of immigrant workers, a number of cases have recently been diagnosed. There were 3 cases of neurocysticercosis reported in our centre over the last 5 years.

**Key Words:** Neurocysticercosis, *Taenia solium*, Scolex

### Introduction

Neurocysticercosis, has a worldwide distribution but is most common in Central and Latin America, Mexico, Asia, Africa, Spain, Portugal, and Eastern Europe. In Malaysia it poses a diagnostic problem as the disease is not seen amongst the local population.

### Case Report

There were 3 cases of neurocysticercosis reported in our centre.

#### Case 1

A 25 years old man from the southern part of Rangoon, Myanmar presented to the casualty department with his first episode of tonic-clonic seizure lasting for five minutes. He did not have a past medical history of significance. His clinical examination was unremarkable with no obvious neurological findings. Plain and contrasted brain CT scan done at the time of admission demonstrated a single hypodense lesion that did not enhance with contrast. It measured 1.5cm in

diameter and was within the right parital lobe. Within the hypodense lesion a punctate eccentric high density area suggestive of a scolex was noted. Mild cerebral edema was also noted surrounding the lesion (Figure 1). MRI done demonstrated small cystic lesion with surrounding edema (Figure 1). Enzyme-linked Immunotransfer Blot assay (EITB) that was subsequently done was positive for cysticercoids antibody. A diagnosis of cerebral cysticercosis was made and treatment with Albendazole was commenced. He was also started on Phenytoin 300mg a day for his seizures.

#### Case 2

A 28 years old Nepalese admitted for cerebral concussion after a fall and developed fits 24 hours later. His CT scan demonstrated multiple scolexes (Figure 2). Enzyme-linked Immunotransfer Blot assay (EITB) that was subsequently done was positive for cysticercoids antibody. A diagnosis of cerebral cysticercosis was made and treatment with Albendazole was commenced. He was also started on Phenytoin 300mg a day for his seizures.

This article was accepted: 18 May 2005

Corresponding Author: Kalai Arasu Muthusamy, Division of Neurosurgery, Department of Surgery, University of Malaya Medical Centre, Lembah Pantai, 50603 Kuala Lumpur

**Case 3**

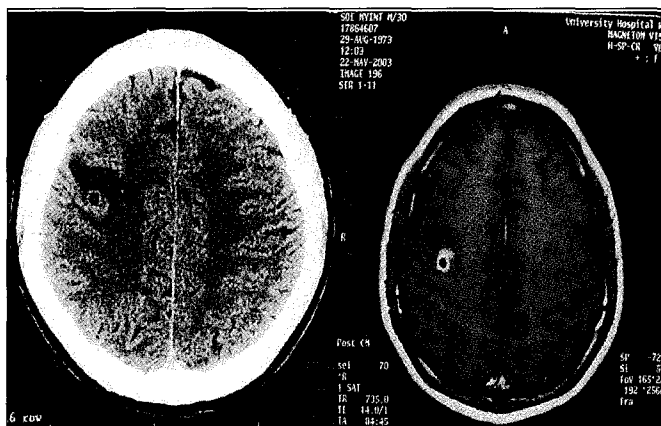
A Nepalese child who was diagnosed as cerebral cysticercosis and admitted for fits. She was previously treated for cysticercosis. Her fits were stabilized with anti epileptic and discharged well.

**Discussion**

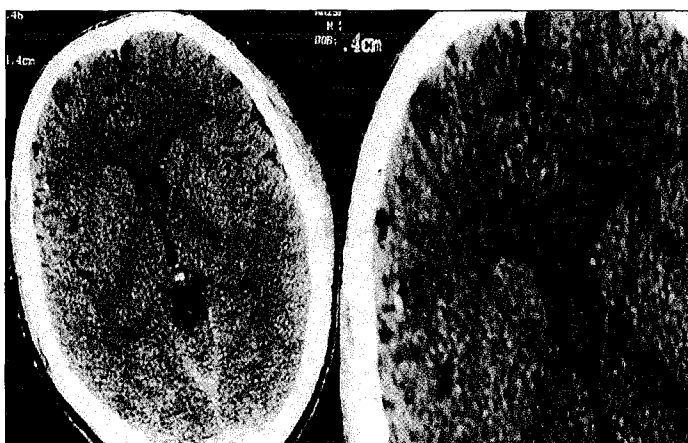
We have seen 5 cases of neurocysticercosis at our institution over the last 3 years. Two of these were post-mortem findings.

Humans are the only definitive hosts of the adult tapeworm and the infection is acquired by consuming uncooked pork which is infected by viable larvae or cysticerci. The pig is the intermediate host.

In humans, individuals who ingest *T. solium* eggs develop tissue infection with parasite cysts (cysticercosis), while those who ingest larval cysts acquire 'pork' tape worm, i.e., the adult form of *T. solium*. Cysticercosis represents tissue infection with larval cysts of the cestode *Taenia solium*, in which the patient serves as an intermediate host for the parasite. The eggs liberate oncospheres (the larval of tape worm) in the intestine that migrate to tissues throughout the body, including the central nervous system where cysts form. For cysticercosis the incubation period is months to years<sup>1</sup>. In patients with infestation of their central nervous system the clinical presentation can be variable and mimic virtually any disease of the CNS, depending upon the number, size, and location of the cysts<sup>1</sup>.



**Fig. 1: CT scan brain showing the scolex which is hypodense lesion with a punctate eccentric high density area and MRI brain showing the scolex.**



**Fig. 2: CT scan brain showing multiple scolexes.**

## CASE REPORT

Cysts of *Taenia solium* in the brain (neurocysticercosis) can cause seizures, behavioral disturbances and obstructive hydrocephalus. The host reaction to degenerating cysts can produce signs and symptoms of meningitis. Cysticerci in brain tend to grow to a larger size than in other tissues. Cysts in the spinal column can cause gait disturbance, pain and transverse myelitis. Subarachnoid lesions may cause meningitis, while intraventricular or aqueductal lesions may lead to hydrocephalus. Signs of increased intracranial pressure such as headache, vomiting, and confusion, may be present. An increased risk for cerebrovascular accidents has been reported. Enlarging cysticerci may also exert a mass effect<sup>2</sup>.

Immunologically there is relative tolerance and a minimal inflammatory response so long as the larvae remains viable allowing the patient to remain asymptomatic. Antigen exposure, however, occurs when the larvae degenerate. This leads to an acute inflammatory response predominantly by eosinophils with pronounced oedema. The inflammation subsequently becomes granulomatous and finally forming a fibrous scar<sup>1</sup>. The diagnosis of Cysticercosis is usually by a positive EITB assay<sup>3</sup>.

CT scan done in patients with cerebral cysticercosis usually demonstrates hypodense lesion that do not enhance with contrast. Within the hypodense lesion a punctate eccentric high density area suggestive of a scolex may be present. MRI imaging may not always provide a definitive diagnosis of cisternal cysticerci, a high index of suspicion, clinical and imaging follow-up might be needed to arrive at a diagnosis<sup>4</sup>.

The treatment of neurocysticercosis has evolved from surgical therapy in the past to anticysticercal chemotherapy. Both Praziquantel and Albendazole reduce or even eliminate the cysticerci. Courses of Albendazole for as short as 8 days have been reported to be effective<sup>4</sup>. However, increased symptoms occur in some patients because death of the larvae stimulates the host inflammatory response. Concurrent steroid treatment may be given to alleviate these symptoms<sup>4</sup>.

In countries such as Malaysia where this disease does not traditionally occur when findings similar to the above are made especially in patients from countries where this condition is endemic this diagnosis must be entertained and the necessary assays should be done and patients treated accordingly.

---

## References

1. Pittella JE. Neurocysticercosis. *Brain Pathology*. 1997; 7: 681-93.
2. Garg PE. Drug treatment of neurocysticercosis. *National Medical Journal of India*. 1997; 10: 173-77.
3. Connor DH, Chandler FW, Schwartz DA, Manz HJ, Lack EE. *Pathology of Infectious Diseases*. Connecticut: Appleton & Lange. 1997; 1365-371.
4. Del Brutto OH. Neurocysticercosis. *Current Opinion in Neurology*. 1997; 10: 268-72.