

# Intractable Epistaxis Secondary to a Post-traumatic Pseudoaneurysm

G S Mann, MS (HNORL), R Philip MMED (ORL-HNS), A Balachandran MS (HNORL)

Department of Otorhinolaryngology, Hospital Ipoh, Jalan Hospital, 30990 Ipoh, Perak

## Summary

Epistaxis is a common problem encountered in clinical practice. It is usually self-limiting and is usually controlled with conservative measures such as nasal compression or ice-packs. Occasionally nasal packing is required. It is rarely severe enough that surgical intervention is warranted. The following report illustrates a patient who presented to us with a rare cause of life-threatening epistaxis that is, a post-traumatic pseudoaneurysm who finally required surgical intervention to control the bleeding.

**Key Words:** Epistaxis, Post-traumatic pseudoaneurysm, Angiogram, Internal carotid artery

## Case report

A 31 year old Chinese man was admitted to Hospital Ipoh in March 2001 for epistaxis. It was sudden in onset and stopped spontaneously. He was admitted for observation.

He gave a history of assault in December 2000 and from the previous CT report it was noted that he sustained a thin subdural hematoma at the right frontal area with an overlying fracture through the frontal bone and sinus and multiple fractures of the walls of the right maxillary antrum, right zygomatic arch and right orbital walls. He was treated at a private specialist centre where drainage of the subdural hematoma was performed.

During the current admission he was investigated well. His haemoglobin level was 14.3 g/dl, platelet levels and coagulation profiles were within the normal range. A nasal endoscopy performed in the clinic under local anaesthesia was unremarkable except for clots in the nasal cavity. He was then discharged home.

He was subsequently brought in to Casualty on the 21st of May 2001 with profuse epistaxis with approximate blood loss about 1.5 to 2.0 L. He was resuscitated in the emergency room for hypovolemic shock and was given blood transfusion. However, the bleeding stopped spontaneously. Rigid endoscopy performed subsequently revealed clots in the nasal cavity and post-nasal space. He was well until he developed another episode of profuse epistaxis the next day for which an anterior and posterior nasal packing were performed. Due to the uncontrolled epistaxis he was subjected to EUA (Examination Under Anaesthesia) and repacking. The EUA was unremarkable.

The following week, the pack was removed under GA and repeat nasal endoscopy did not reveal any gross pathology. He was discharged well. A CT scan and MRI (Fig.1) was performed and the only consistent finding was a left sphenoidal mass.

He was sent to Hospital Kuala Lumpur for an angiogram, which was performed on June 2001 and revealed no abnormalities. Unfortunately, only the external carotid system was demonstrated. He has

This article was accepted: 22 December 2004

Corresponding Author: Gurdeep Singh Mann, Department of Otolaryngology, Hospital Ipoh, Jalan Hospital, 30990 Ipoh, Perak

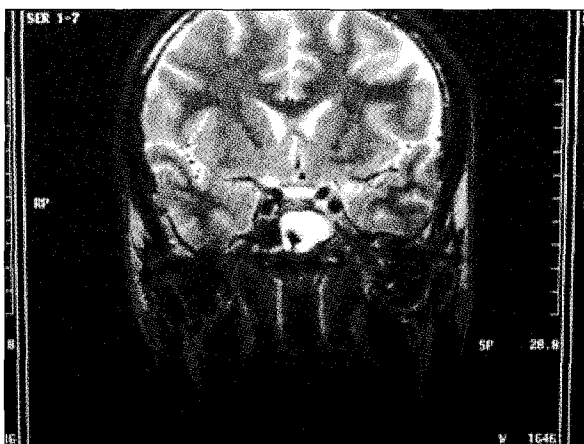
## CASE REPORT

since bled thrice on admission, each time losing about 700 mls, lasting about 20 minutes and stops spontaneously before packing was performed. It was a torrential bleed mainly from the left nostril. The bleeding episodes were preceded by a dull frontal ache.

It was concluded that the patient had a post-traumatic pseudoaneurysm involving the internal carotid system. He was referred to Hospital U.K.M. for a repeat angiogram of the internal carotids and embolisation / ligation of the offending vessel.

The patient bled again soon after admission requiring a transfusion of 2 units of whole blood. An urgent angiogram was performed which showed a pseudoaneurysm of the right internal carotid artery proximal to the branch of the ophthalmic artery. The right internal carotid artery was ligated.

Post-operatively there was no neurological deficit or blurring of vision. To date (1 month post-operatively) patient has had no bleeding episodes.



**Fig. 1: MRI showing contrast enhancing left sphenoidal mass**

### Discussion

Epistaxis is a common occurrence that afflicts 60% of the general population during some point in their lives. The majority of these individuals will be able to control their bleeding easily. Therefore, only 6% of those affected will seek or require medical attention<sup>1</sup>.

There are several causes of epistaxis, including dryness of the nasal cavity, digital trauma to the nasal cavity,

hypertension, anticoagulation and blood dyscrasias<sup>2</sup>. Conservative therapy includes local pressure, vasoconstrictors nasal packing and balloon catheters. Patients who do not respond to such measures will require more invasive methods such as transantral arterial ligation of the internal maxillary artery, external carotid artery ligation, anterior ethmoidal artery clipping. Other measures include arterial embolization, submucous resection and endoscopic cauterly and ligation<sup>1</sup>.

Trauma and vascular abnormalities account for less than 5% of all severe cases of epistaxis<sup>2</sup>. The majority of post-traumatic epistaxis occur in the anterior region of the membranous septum and can usually be controlled by direct anterior nasal packing or coagulation. Sources of more profound epistaxis are the ethmoidal and sphenopalatine artery, facial and skull base trauma and post-traumatic aneurysms.

The majority of cavernous ICA aneurysms that result in epistaxis are traumatic in origin and are therefore more appropriately termed pseudoaneurysms. Other causes of ICA aneurysm include arteriosclerosis, dysplasia and infection. The hallmark of post-traumatic pseudoaneurysm is delayed, progressively more severe and sometimes fatal epistaxis. Immediate complete or partial ipsilateral monocular visual loss caused by either compression or laceration of the optic nerve, or thrombosis of the ophthalmic artery is common. The oculomotor nerve and the ophthalmic and maxillary divisions of the trigeminal nerve are less frequently involved. The combination of head injury, monocular blindness and epistaxis constitutes Maurer's triad<sup>3</sup>.

ICA aneurysms can be managed surgically by ligation of either the cervical common carotid artery or the ICA. The procedure carries the risk of reperfusion phenomenon due to anastomosis from the ipsilateral and contralateral carotid systems<sup>2</sup>.

However, with the development of endovascular techniques, detachable balloons and coils have been successfully used in the treatment of these aneurysms. In addition, a test occlusion of the ICA can be performed with a nondetachable balloon to determine the adequacy of collateral blood flow to the brain. Detachable balloons also allow for not merely the proximal occlusion of the ICA, but also occlusion of the segment of the ICA distal to the aneurysm. In this manner, collateral blood flow to the aneurysm can be prevented and the likelihood of a rebleed as well as delayed embolic strokes reduced<sup>4</sup>.

Complications of embolization include blindness, facial nerve palsy, soft tissue necrosis and cerebral infarction<sup>1</sup>. Its distinct advantage over surgery include distal access near bleeding points, demonstration of bleeding points, control of multiple bleeding points, repeatability, no necessity for general anaesthesia and short procedure time<sup>5</sup>.

The confirmation of complete occlusion of the aneurysm can be obtained with a post-embolization/surgical ligation arteriogram.

A post-traumatic pseudoaneurysm can be managed either by surgical arterial ligation or by endovascular embolization. In this patient, surgery was opted due to the emergency of the situation. If the problem recurs he will need clamping of the ICA distal to the aneurysm.

---

## References

1. Elahi MM, Parnes LS, Fox AJ, Pelz DM, Lee DH. Therapeutic embolization in the treatment of intractable epistaxis. *Arch Otolaryngol Head Neck Surg.* 1995; 121(1): 65-9.
2. Cohen S, Anastassov GE, Chuang SK. Posttraumatic pseudoaneurysm of the sphenopalatine artery presenting as persistent epistaxis: diagnosis and management. *J Trauma.* 1999; 47(2): 396-9.
3. Maurer JJ, Mills M, German WJ. Triad of unilateral blindness, orbital fractures and massive epistaxis after head injury. *J Neurosurg.* 1961; 18: 837-40.
4. Kim JY, Farkas J, Putman CM, Varvares M. Paraclinoid internal carotid artery aneurysm presenting as massive epistaxis. *Ann Otol Rhinol Laryngol.* 2000; 109(8 Pt 1): 782-6.
5. Komiyama M, Nishikawa M, Kan M, Shigemoto T, Kaji A. Endovascular treatment of intractable oronasal bleeding associated with severe craniofacial injury. *J Trauma.* 1998; 44(2): 330-4.