

Tarsometatarsal Joint Injuries – Review of Clinical Presentation and Surgical Treatment

S Y Loh, FRCS (Orth)*, J L Soon, MBBS**, W J Verhoeven, FRCS***

*Department of Orthopedic Surgery, Alexandra Hospital, 378, Alexandra Road, Singapore 159964, **Singapore Health Services, ***Department of Orthopedic Surgery, Changi General Hospital

Summary

The tarsometatarsal (Lisfranc) joint suffers a spectrum of injuries ranging from solely ligamentous injury to fracture dislocation. The authors evaluated eighteen consecutive patients who underwent surgery for tarsometatarsal joint injuries, utilising 4.5 mm cancellous screws and 1.6 mm K-wires. The outcome of function and anatomical reduction were assessed by AOFAS (American Orthopedic Foot and Ankle Society) midfoot score and radiography. Patients with only ligamentous injury scored poorer partly due to delay in diagnosis and the nature of the injury. The technique used maintained anatomical reduction at the time of review.

Key Words: Lisfranc fracture, Surgery, Anatomical reduction

Introduction

Injury of the tarsometatarsal joint is not common. It is a spectrum encompassing soft tissue and bony injuries. In a bony injury, the diagnosis made after history and physical examination is readily confirmed by x-rays. However, when only soft tissue is involved, the subtle radiographic signs might not be appreciated by the untrained eye and can lead to delay in the diagnosis and treatment of the ligamentous injury. Studies have shown that the outcome is better with stable anatomical reduction¹⁻⁸. The treatment trend is towards open reduction and screw fixation^{1,2,4,6}. The authors advocate treating all bony and displaced ligamentous tarsometatarsal joint injuries with open anatomical reduction utilising 4.5 mm cancellous screws and 1.6 mm K-wires. Kuo et al⁹ had noted the comparative poorer outcome in the solely ligamentous injuries after surgery. We reviewed eighteen consecutive cases of tarsometatarsal injuries that had undergone surgery and evaluated the outcome in terms of function (AOFAS midfoot score) and anatomical reduction (radiographs).

Materials and Methods

A retrospective study of all the patients with tarsometatarsal injuries that underwent surgery at Changi General Hospital between Jan 1997 to Dec 2001 was carried out. The inclusion criterion was open reduction and internal fixation of the tarsometatarsal joint. The indications for surgery were fractures and displacement. The ligamentous injuries were included when they showed instability on stress x-rays (more than 1 mm displacement of bony alignment) 28 patients were identified from the trauma registry database and contacted by telephone. The history was evaluated with attention to trauma mechanism, concurrent injuries, open or closed fractures, and interval between injury and surgery. The initial x-ray findings were also documented. The functional outcome was assessed with the AOFAS (American Orthopedic Foot and Ankle Society) midfoot score by only one author (J L Soon) to prevent interobserver variability. The AOFAS score is based on a scale of 0 to 100 points, with 100 points indicating an excellent or maximum outcome. The

This article was accepted: 3 June 2004

Corresponding Author: James Sir-Young Loh, Department of Orthopedic Surgery, Alexandra Hospital, 378, Alexandra Road, Singapore 159964

clinical and radiographic results and functional outcomes were analysed to evaluate the effect of injury and treatment parameters. The main components of the scoring scale consisted of pain, function (further subdivided into activity limitation, footwear requirement, maximum walking distance, walking surfaces and gait abnormality) and alignment of the foot.

Surgical Technique

The senior author (W J Verhoeven) performed the surgeries. The surgical approach was via 2 incisions. The medial incision between the proximal first and second metatarsals enabled access to the medial column. The first metatarsal-medial cuneiform joint was first reduced, followed by the second metatarsal-middle cuneiform joint and the third metatarsal-lateral cuneiform joints. 4.5mm cannulated screws were used. The dorsalis pedis and nerves were identified and preserved. The lateral column was approached via the lateral incision over the proximal fourth metatarsal. 1.6 mm K-wires were used to reduce the fourth and fifth metatarsal-cuboid joint. Attention was given to ensure an adequate skin bridge between the 2 incisions.

Concurrent fractures were treated at the same surgery. The image intensifier was used intra-operatively to assess the fracture reduction and aid in implant placement. Intra-operative radiographs were done for all the surgeries before reversal. Post-operatively, the patient was splinted below the knee for a minimal of 6 weeks and non weight bearing was instructed. Any increase in duration of the non weight bearing status depended on x-ray and clinical assessment of healing. The implants are removed at the end of 3 to 4 months after surgery.

Results

Twenty-eight patients were found suitable for the study. However, ten were not available: four refused participation and six were foreign workers who had returned to their country. The remaining eighteen patients with eighteen tarsometatarsal injuries participated in the study. The age ranged from twenty-one to sixty-seven years old, with a mean of 32.2 years. There were fifteen male and three female patients. All patients were Asian. There were eleven left feet and seven right feet. Ten patients had sustained high energy trauma (four fall from height and six crush). The remaining eight patients sustained low energy trauma

(twist and blunt trauma). Nine were polytrauma and nine were isolated injuries.

There were nine cases with associated injuries. Of these, one was a ligamentous injury with an associated fibula fracture (the fibula fracture was treated conservatively). The other eight were obvious tarsometatarsal fractures with associated injuries. There was a single case of open fracture involving the tarsometatarsal joint. Eleven were obvious fractures at the time of first presentation to the medical practitioner (Fig 1). The diagnosis was evident on radiological assessment. The other seven were ligamentous injuries and the radiographs only showed subtle bony mal-alignment. They had been referred to the orthopedic clinic by the emergency or family physician for a symptomatic foot with normal radiographic finding. The shortest interval between injury and surgery was within one day involving a tarsometatarsal fracture dislocation. The mean interval between injury and surgery for bony tarsometatarsal joint injury was 5.5 days while that of ligamentous injury was 30 days (excluding the case of a military personnel with a seven month delay).

A number of reasons contributed to the delay in surgery. In polytrauma, basic resuscitation and stabilization were given priority. Skin injury also necessitated a delay in surgery to avoid incision wound complications. Open injury also required initial debridement before definitive surgery. All the ligamentous injuries were referred to the orthopedic clinic before they were admitted for surgery. The average follow-up period was thirty months, the shortest was twelve months and the longest was thirty-nine months.

There were no post-operative complications noted in the follow-up review. No broken implants were noted. The single case of open fracture required split thickness skin grafting. The average AOFAS score was 81.4 points (ranging from 54 points to 100 points). Patients lost points for mild pain, mal-alignment and reduced function. The average was lower for the ligamentous injury subgroup (76.3 points) compared to the bony injury subgroup (84.6 points). The highest score for both groups were 100 points. The lowest score for the ligamentous injury subgroup was 54 points while that for the bony injury subgroup was 58 points. Seven were asymptomatic (one ligamentous injury and six bony injury). The remaining eleven (six ligamentous injury and three bony injury) had symptoms of varying severity (eight sustaining mild pain and stiffness; remaining three affected in walking, sports and work).

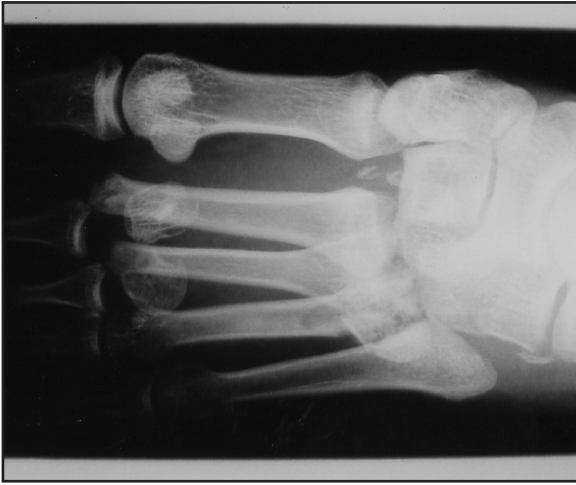

Fig 1: Bony tarsometatarsal joint injury at time of presentation

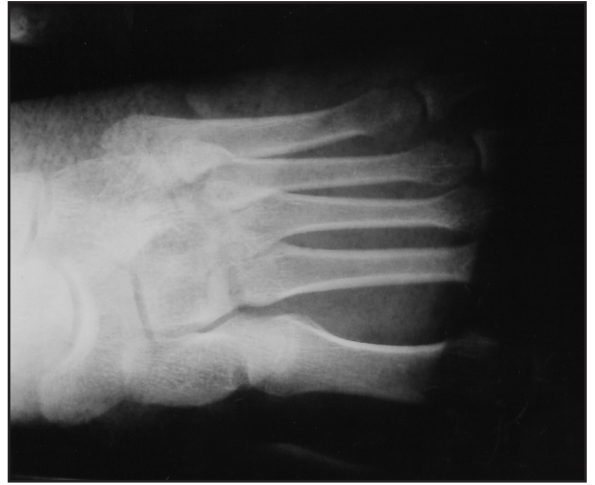

Fig 2: Ligamentous tarsometatarsal joint injury presented as a symptomatic foot with no obvious x-ray findings in non weight bearing films

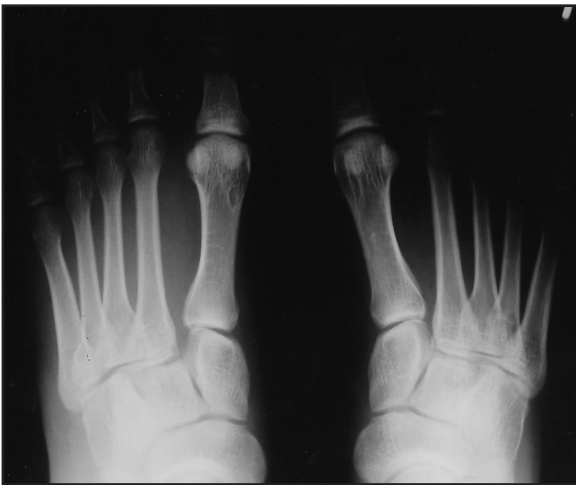

Fig 3: Subtle diastasis widening can be detected in the antero-posterior weight bearing comparison film

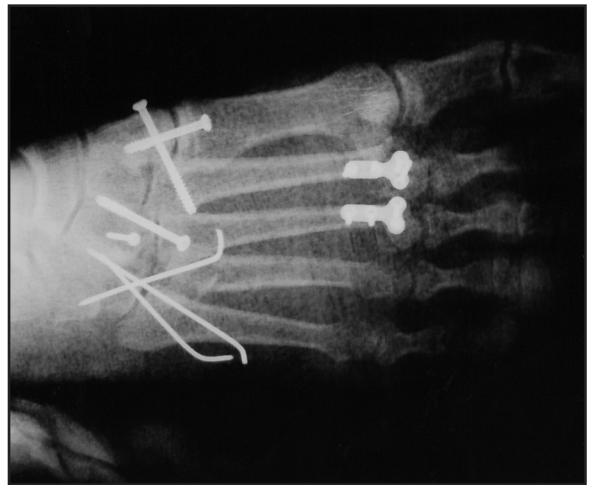


Fig 4: Reduction with screws in the medial column and K-wires in the lateral column

Table I: Comparison between ligamentous and bony Lisfranc injury

	Ligamentous Injury (n=7)	Bony Injury (n=11)
AOFAS score (mean)	76.3	84.6
AOFAS score (highest)	100	100
AOFAS score (lowest)	54	58
Polytrauma	1	8
Isolated	6	3
Immediate diagnosis	0	11
Delayed diagnosis	7	0
Interval between injury and diagnosis (day) *		0
Mean	24.2	
Longest	76	
Shortest	2	
Interval between diagnosis and surgery (day)		
Mean	5.8	5.5**
Longest	0	11
Shortest	27	0
Follow-up period (months)		
Mean	34.1	28.3
Shortest	13	12
Longest	59	48

* Excluding the case of the military personnel which was delayed for 7 months

** Delay is due to soft tissue considerations and resuscitation prioritization

Discussion

The tarsometatarsal joint injury accounts for only 0.2 percent of all fractures. In the ligamentous injury with its associated subtle radiographic signs (Fig 2), the diagnosis is easily missed¹⁰. A weight bearing anteroposterior film of bilateral feet is helpful in the assessment (Fig 3). However, this is not always possible in an acute injury. A high index of suspicion is needed and it is advisable to seek the opinion of the orthopedic surgeon. The nature of this injury might have resulted in the greater interval between injury and surgery. One series showed poor functional results in patients with delayed diagnosis^{1,11}. Other studies suggested a delay of up to six weeks could still produce a favorable outcome¹²⁻¹⁴. Thus early diagnosis is crucial to facilitate early treatment and obtain a favorable outcome.

Though the ligamentous injuries were the result of seemingly minor trauma, the average AOFAS midfoot score after surgery was less than that of bony injury (Table I). The statistical significance of this observation

cannot be determined in the current study because of its small number. Kuo et al⁹ had noted a similar outcome. When it is a bony injury, the healing is better than ligamentous injury. The delay in diagnosis resulted in a greater interval between injury and surgery, could have resulted in further damage to the articular surfaces, due to prolonged malpositioning and instability. Dissection and reduction was made more difficult by fibrosis that set in. There was one workman compensation case and 3 military recruits who had sustained ligamentous injury, However, there was no obvious reason to suspect secondary gain.

No classification system was used in this study. There is no single classification that comprehensively covers the broad spectrum of this condition, enables prognostication and directs treatment. We advocate open reduction and internal fixation with the aim of achieving stable anatomical reduction. Surgery enables direct visualization and assessment for osteochondral injury, comminution, loose fragments and soft tissue interposition². This facilitates reduction of the fracture and prognostication. The importance of stable

anatomical reduction is supported by a number of studies¹⁻⁸. The combination of 4.5 cannulated screws and 1.6 mm K-wires were used (Fig 4). The medial column is inherently more rigid than the lateral column. Therefore, screws were used to secure the stability required for anatomical reduction and healing. 4.5 mm cannulated screws were chosen over 3.5 mm as they were stronger. Compared to 1.6 mm K-wires, the articular surface damage is greater but the benefit of greater stability outweighs this consideration. K-wires afforded sufficient stability to the lateral column that is inherently a relatively mobile column. Removal of implants was approximately 3 to 4 months after surgery. This reduced implant complications such as breakage and K-wire migration. Primary arthrodesis was reserved as a salvage procedure for complications such as persistent pain or non-union. Mulier et al¹⁵ had suggested that primary complete arthrodesis should be reserved as a salvage procedure. Limitations of the current study included the 64.3 percent follow-up rate

and the mean duration of 30 months. The study population was small. A prospective study would be better suited to analyze the fixation technique.

Conclusion

A longer interval between injury and surgery was noted in the ligamentous subgroup. This observation highlighted the subtlety in presentation and diagnostic difficulty of this subgroup. The delay might have contributed to the lower AOFAS score, despite similar treatment and the minor trauma involved. Anatomical reduction was maintained in all cases at the time of review.

Acknowledgements

The authors thank Mercy Christian and Dr Leong Wai May for the administrative and technical support.

References

1. Curtis MJ, Myerson MS, Szura B: Tarsometatarsal joint injuries in the athlete. *Am J Sports Med* 1993; 21: 497-502.
2. Arntz CT, Veith RG, Hansen ST: Fractures and fracture dislocation of the tarsometatarsal joint. *J Bone and Joint Surg* 1988; 70-A: 173-81.
3. Myerson MS, Fisher RT, Burgess AR, Kenzora JE: Fracture dislocations of the tarsometatarsal joints: end results correlated with pathology and treatment. *Foot and Ankle* 1986; 6: 225-42.
4. Myerson M: The diagnosis and treatment of injuries to the Lisfranc joint complex. *Orthop Clin North Am* 1989; 20: 655-64.
5. Rosenberg GA, Patterson BM: Tarsometatarsal (Lisfranc's) fracture dislocation. *Am J Orthop* 1995; supplement: 7-16.
6. Buzzard BM and Briggs P J: Surgical management of acute tarsometatarsal fracture dislocation in the adult. *Clin Orthop* 1998; 353: 125-33.
7. Myerson M: Injuries to the forefoot and toes. In *Disorders of the Foot and Ankle: Medical and Surgical Management*, M H Jahss (ed). Ed 2, vol 3, p2233-2272. Philadelphia, W B Saunders, 1991.
8. Teng AL, Pinzur MS, Lomasney L, Mahoney L, Havey R: Functional outcome following anatomic restoration of tarsal-metatarsal fracture dislocation. *Foot Ankle Int* 2002; 23(10): 922-6.
9. Kuo RS, Tejwani NC, DiGiovanni CW et al: Outcome after open reduction and internal fixation of Lisfranc joint injuries. *J Bone and Joint Surgery* 2000; 82-A (11): 1609-618.
10. Perron AD, Brady WJ, Keats TE: Orthopedic pitfalls in the ED: Lisfranc fracture-dislocation. *Am J Emerg Med* 2001; 19(1): 71-5.
11. Richter M, Wiperman B, Krettek C, Schratz H E, Hufner T, Therman H: Fractures and fracture dislocations of the midfoot: occurrence, causes and long-term results. *Foot Ankle Int* 2001; 22(5): 392-8.
12. Arntz CT, Hansen ST: Dislocations and fracture dislocations of the tarsometatarsal joints. *Clin Orthop* 1987; 18: 105-14.
13. Trevino SG, Baumhauer JF: Lisfranc injuries. In Myerson M S (ed): *Current therapy in foot and ankle surgery*. St Louis, Mosby year book, 1993.
14. Trevino S G, Kodros S: Controversies in tarsometatarsal injuries. *Orthop Clin of North Am* 1995; 26: 229-38.
15. Mulier T, Reynders P, Dereymaeker G, Broos P: Severe Lisfranc injuries: Primary arthrodesis or open reduction and internal fixation? *Foot Ankle Int* 2002; 23(10): 902-5.