

Large Fusiform Posterior Cerebral Artery Aneurysm (P2 Segment): Successful Trapping and Excision via Subtemporal Approach

A R M Ramzisham, MRCS, A B Azizi, MS, A A R Zurin, MS

Division of Neurosurgery, Department of Surgery, Hospital University Kebangsaan Malaysia, Jalan Yaacob Latiff, Cheras, 56000 Kuala Lumpur

Summary

A 62-year-old man presented with a 2-month history of right occipito-parietal headache and worsening ipsilateral ptosis. CT scan and cerebral angiography revealed a large fusiform aneurysm of the P2 segment of the right posterior cerebral artery (PCA). The aneurysm was successfully trapped and subsequently excised via subtemporal approach leaving no additional neurological deficits to our patient.

Key Words: Cerebral aneurysm, Posterior cerebral artery, Subtemporal approach

Introduction

Aneurysms of the posterior cerebral artery (PCA) are rare, accounting for approximately 0.7 – 2.3% of intracranial aneurysms¹. Moreover, these aneurysms have specific characteristics such as deep location, high incidence of large, fusiform type and rich collateral flow to the parent arteries. Therefore, these aneurysms differ from those in other sites not only because of their rarity, but also due to their specific nature². The large fusiform aneurysm on the P2 segment in our case exemplifies these peculiarities. In addition, the presenting complaint of unilateral ptosis is most unusual, with only one case reported earlier by Tafani et al³. The traditionally accepted approach to this aneurysm has been via the subtemporal route. In view of the anatomical peculiarities, the large number of perforating arteries and its close relationship with the oculomotor nerve, trochlear nerve and the midbrain, many authors have advocated alternative approaches such as petrosal, transzygomatic, pterional or even transtemporal transventricular route^{1,2}. We present a

rare case in which the conventional subtemporal route is still proven to be a sound approach in tackling this difficult aneurysm.

Case Report

A 62-year-old Chinese man was referred to our unit with a 2-month history of right occipito-parietal headache, progressive ipsilateral ptosis and diplopia. Clinical examination revealed a complete ptosis of the right eye, dilated pupil and a 'down and out' disposition of the ipsilateral eye in a relatively well patient. Computed tomography (CT) and cerebral angiography showed the presence of a 25x7.5 mm fusiform aneurysm at the P2 segment of the right PCA (distal to the junction of the posterior communicating artery to the posterior aspect of midbrain).

Surgery was electively performed on this patient. The partially thrombosed aneurysm which was located at the proximal P2 segment about 3-4mm distal to the

This article was accepted: 20 January 2004

Corresponding Author: Mohd Ramzisham Abdul Rahman, Department of Surgery, Hospital University Kebangsaan Malaysia, Jalan Yaacob Latiff, Cheras, 56000 Kuala Lumpur

junction of the posterior communicating artery and the PCA was identified. Part of its medial wall adhered to the midbrain and the lateral wall stretched the oculomotor nerve. The thalamoperforators and the long and short recurrent arteries arising from P1 segment were identified and preserved. A temporary clip was applied to the distal posterior communicating artery and the distal P1 segment of the PCA prior to performing thrombectomy to facilitate aneurysm mobilisation. The aneurysm was then trapped at the proximal P2 segment and distal to the aneurysm. The

lateral wall was excised thus freeing the oculomotor nerve from compression.

Our patient recovered well after the surgery. He was discharged home at post-operative day 7 without any new neurological deficits. The ptosis completely resolved eight weeks after the surgery. The subsequent angiography showed complete extirpation of the aneurysm with good 'retrograde' filling of the distal PCA.

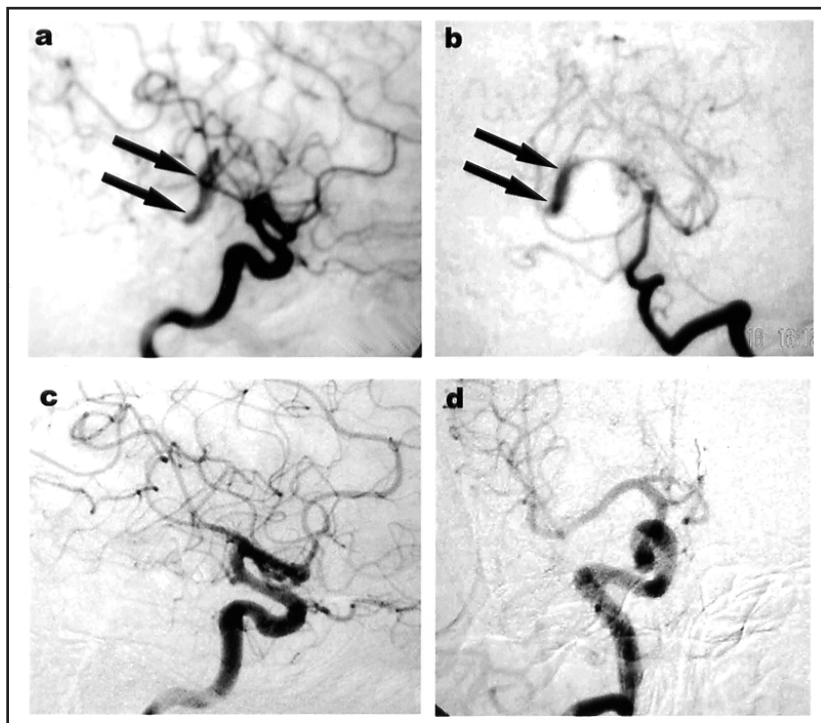


Fig. 1

- a. Preoperative angiogram of the right ICA, demonstrates the P2 fusiform aneurysm. The aneurysm opacifies via the posterior communicating artery (lateral view).**
- b. Preoperative angiogram of the Vertebral artery, showing the P2 aneurysm (Townes view).**
- c. Post operative angiogram showing no residual aneurysm with good collateral vessels (lateral view).**
- d. Postoperative angiogram (Townes view).**

Discussion

P2 aneurysms have special features that create a challenge in their management. The choice of surgical approach, tailored to the aneurysm being treated greatly determines the outcome of surgery. In our case, the subtemporal approach was chosen as it affords the nearest route to the aneurysm. A wider surgical field is also an advantage considering the large size of the aneurysm. The poor visualisation of the major and perforating vessels surrounding this large aneurysm, the adherence of the oculomotor nerve to its (aneurysm) lateral wall and the presence of intramural thrombus were factors which posed serious difficulties in preventing neurological deficits. The occurrence of the fusiform type aneurysm in this case limits our options in trying to maintain the continuity of the parent vessel. Trapping (clipping of both proximal and distal ends of the aneurysmal vessel) and the subsequent excision of the aneurysm removed its bulk and at the same time relieved the compression on the oculomotor nerve. The alternative treatment of trapping alone would not have taken the pressure off the oculomotor nerve thus seriously jeopardising the chances of its recovery.

The drainage of CSF, judicious use of mannitol and cerebral protection with thiopentone infusion had allowed us to manipulate the brain with lesser risk of damage. The utilisation of thiopentone infusion throughout the surgery is thought to minimise ischaemic damage due to brain retraction, temporary clipping and deliberate hypotension during manipulation of the aneurysm. Despite the simplicity of this approach, we were able to visualise, dissect and protect important neurovascular structures without the need for extra osteotomy or resection of brain tissue such as via transzygomatic or transtemporal transventricular routes.

The patient had an uneventful post-operative recovery without any additional neurological deficits and a complete recovery of the oculomotor nerve was seen. In conclusion, our experience in using the subtemporal approach for this large fusiform aneurysm of the P2 segment of the PCA has shown that this conventional method can lead to good long term neurological outcome if adequate steps are taken to address the issue of retraction damage to the brain.

References

1. Kitazawa K, Tanaka Y, Muraoka S et al. Specific characteristics and management strategies of posterior cerebral artery aneurysms: report of eleven cases. *J. Clin. Neuroscience* 2001; 8(1): 23 - 26.
2. Selviaridis P, Spiliotopoulos A, Antoniadis Ch., Kantopoulos V, Foroglou G. Fusiform aneurysm of the posterior cerebral artery: report of two cases. *Acta Neurochir (Wien)* 2002; 144: 295 - 99.
3. Tafani B, Lehmann G, Boudouresques G, Viallet F, Bourdillon J, Khalil R. Fusiform aneurysm of the posterior cerebral artery: an unusual aetiology of isolated paralysis of the IIIrd cranial nerve. *Rev. Otoneuroophthalmol* 1980; 52(1): 69-72.