

Intravenous Immunoglobulin in the Treatment of Acute Disseminated Encephalomyelitis

Y Kanaheswari, MRCP*, J Baizura, M.Med. Paeds**, A Zulfiqar, MMed. Radiology***

*Department of Paediatrics, Faculty of Medicine, University Kebangsaan Malaysia, Cheras, 56000 Kuala Lumpur, **Department of Paediatrics, Kajang Hospital, Kajang, Selangor, ***Department of Radiology, Faculty of Medicine, University Kebangsaan Malaysia, Cheras, 56000 Kuala Lumpur

Summary

We describe a case of acute disseminated encephalomyelitis in a child. This case is unusual in that the illness was characterised by recurrent episodes rather than a monophasic course and that the choice of treatment was intravenous immunoglobulin over corticosteroids. The rapid and remarkable recovery is highlighted and a review of the treatment for this rare condition is discussed.

Key Words: Acute Disseminated Encephalomyelitis, Recurrent episodes, Intravenous Immunoglobulin

Introduction

Acute Disseminated Encephalomyelitis (ADEM) is a rare immune-mediated condition predominantly affecting children. MRI scans are required to confirm the diagnosis and to distinguish it from Multiple Sclerosis in the few cases in which recurrent episodes occur. Although ADEM is a self-limiting disease, recovery may be prolonged. Corticosteroid therapy is the most often used treatment for this condition but more recently, other modalities have been successfully used. We report here a child with ADEM presenting with recurrent episodes of neurological dysfunction in whom, intravenous immunoglobulin produced a remarkable and complete recovery.

Case Report

A 3 year old Chinese boy presented to a private medical centre with a one week history of low grade fever and a four day history of lethargy and poor oral intake. He

also had headache on the first day of illness and vomited twice during the week. He had seen a General Practitioner and been given a course of antibiotics but there had been no improvement. There was no history of trauma, drug ingestion, or similar illness in any other family members.

The antenatal and perinatal history was normal. His immunizations were complete and his developmental milestones were appropriate. He was already toilet trained but wore Pampers at night. He was the only child. His father was a businessman and his mother a home-maker.

At the medical center, his blood investigations revealed a TWBC of 16.2×10^6 /L (Neutrophils 74%, lymphocytes 21%, monocytes 4%); Haemoglobin of 12 g/dl; platelet count 423×10^9 /L. The serum electrolytes, random blood sugar and liver function tests were normal. He also had a CT scan of the brain, which was reported as normal. He was then commenced on intravenous

This article was accepted: 3 August 2003

Corresponding Author: Y. Kanaheswari, Department of Paediatrics, Faculty of Medicine, University Kebangsaan Malaysia, Jalan Yaacob Latiff, Bandar Tun Razak, 56000, Cheras, Kuala Lumpur

CASE REPORT

Ampicillin. One day later he became drowsy and "unresponsive to call" and was then referred to our department.

On arrival, he was afebrile with stable vital signs, normal hydration and nutrition. He had spontaneous eye opening but no verbal or motor response to pain. There was no neck stiffness, the pupils were equal and reactive to light. All limbs were hypotonic and reflexes present and normal. The Babinski reflex was upgoing. There was no rash or jaundice. The spine, respiratory, cardiovascular and abdominal and ENT examinations were normal. A clinical diagnosis of meningo-encephalitis was made and he was commenced on intravenous Cefotaxime and Acyclovir. Over the next 48 hours his conscious level and neurological signs improved. A lumbar puncture was then performed. The cerebrospinal fluid had no cells and a normal protein and glucose level. The latex agglutination test was negative and bacterial culture had no growth. The CSF viral culture was negative for HSV (Herpes Simplex Virus), VZV (Varicella virus), enterovirus and Japanese B virus as was the viral Immunofluorescence test for these viruses. At this point the Weil Widal Felix (WWF) test result from the private medical center was available and noted to be mildly elevated for Salmonella Typhi (T 'H' was 1:160 and T 'O' was 1:320). The child however remained afebrile and showed improvement in neurological signs and thus the Cefotaxime and Acyclovir were discontinued (on Day 5). By day 6 of illness he was ambulating and had normal speech and play. The WWF test was repeated and he was discharged home the next day.

Two weeks later however, he was readmitted with a two day history of low grade fever and weakness. On this occasion he was conscious but restless and could obey simple instructions. His muscle power was grade 3/5, with hypotonia and normal reflexes. His speech was not clear and he was noted to have bilateral ptosis but had no other abnormality of extra-ocular movements.

Investigations done during this admission again showed a normal full blood count, blood urea, glucose, electrolytes and liver function tests. The serum ammonia and lactate were also normal as was the venous blood gas analysis. A lumbar puncture was also repeated and again revealed normal CSF results.

The results of the WWF test taken on Day 7 of the first admission were available and showed a greater than four-fold rise in titre for Salmonella Typhi antibodies (T 'H' of 1: 2560 and T 'O' of 1: 2560). At this point, the diagnosis was thought to be typhoid encephalitis with a differential diagnosis of (i) typhoid fever with encephalopathy and (ii) Acute Disseminated Encephalomyelitis (ADEM).

He was commenced on intravenous Acyclovir (this was discontinued once CSF results were available) and intravenous Chloramphenicol. An MRI of the brain was ordered but due to some technical problems with the MRI scanner, this had to be postponed. Over the next few days, he again improved and by day 7, he was able to walk, had normal speech and play, but mild residual ptosis. His parents took AOR discharge but agreed to come back for the MRI appointment one week later. He completed another 7 days of oral Chloramphenicol.

He returned one day before the appointed follow-up date with low grade fever, lethargy, refusal to eat and refusal to talk. He was drowsy again and had generalised weakness with muscle power of Grade 3/5, this time with hypertonia and hyper-reflexia. There was bilateral ankle clonus and up-going plantar responses. The MRI T2-FLAIR images of the brain (Figure 1A) showed a hyperintense pons and a higher slice (Fig 1B) showed hyperintense areas in the caudate nuclei and left thalamus (arrows).

These changes were consistent with the diagnosis of ADEM. It was then concluded that this boy had recurrent episodes of ADEM and that the most likely trigger was Salmonella Typhi antigen. However, there was no evidence of typhoid infection (blood cultures were negative and the clinical scenario was not that of typhoid fever) at the time of presentation or in the past history.

He was given intravenous immunoglobulin 2 G / kg over 5 days. His recovery was remarkable and is tabulated in Table I. An MRI of the brain repeated at the six month review showed that all the radiological changes had completely resolved (Fig 2). He was completely well with no residual neurological symptoms or signs on his first year follow-up and is due for another review (2 year follow-up) in June 2003.

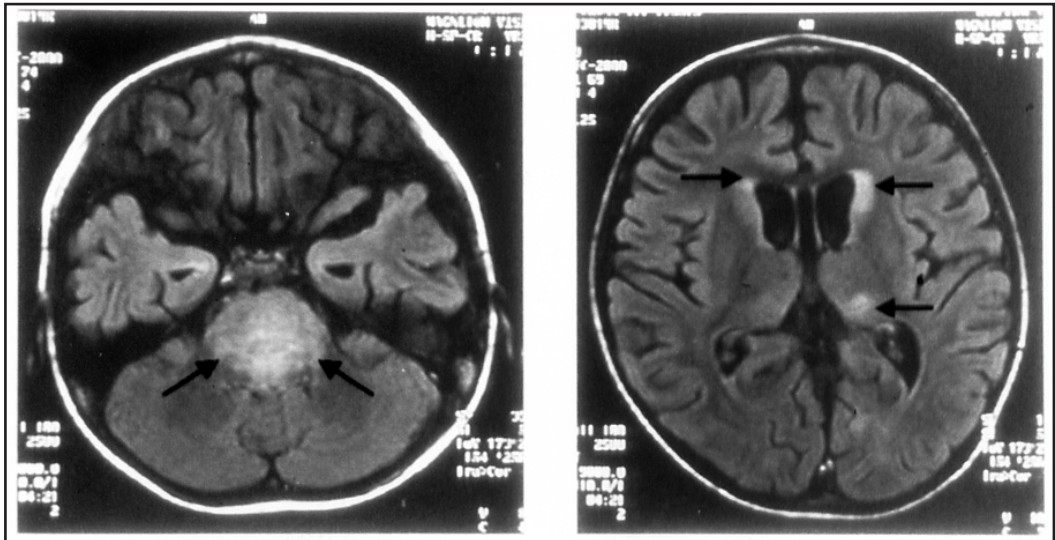


Fig. 1: MRI images of the brain at diagnosis. (A) T2-FLAIR image shows a hyperintense pons (arrows). (B) A higher slice shows hyperintense areas in the caudate nuclei and left thalamus (arrows)

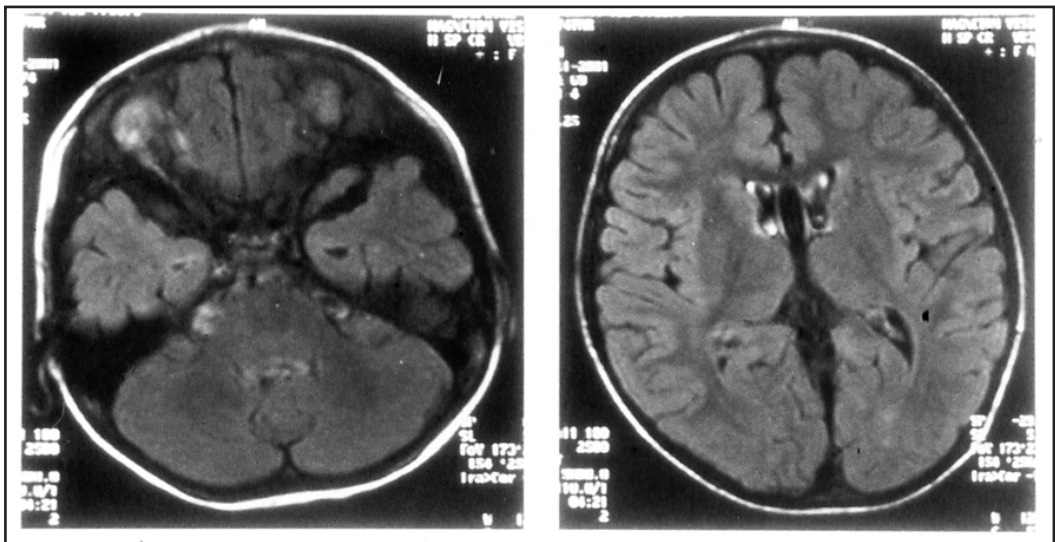


Fig. 2: MRI brain at six-month follow-up. (A) T2-FLAIR image shows a normal pons. (B) The caudate nuclei and thalami are also normal

Table I : Progress and Recovery of Patient with IVIG Therapy

TIME*	MANAGEMENT	PATIENT PROGRESS /RESPONSE
Day 1	IVIG 400 mg / kg	Drowsy, spontaneous eye opening, neck stiffness, generalized weakness, hypertonia, hyper-reflexia, bilat Babinski + and bilat clonus +
Day 2	IVIG 400 mg / kg	Less drowsy, turns to call, UMN signs +, Ryle's tube feeding,
Day 3	IVIG 400 mg / kg	Vocalizing, obeys commands, minimal spontaneous movements, swallowing oral feeds, N tone, brisk reflexes, clonus +
Day 4	IVIG 400 mg / kg	Vocalising, Able to lift both LL spontaneously (grade 4/5), brisk reflexes, clonus +
Day 5	IVIG 400 mg / kg	N speech, sits with support, tone and reflexes N , clonus +
Day 6	Supportive nursing care	Sits alone, stands with support, playing with toys
Day 7	Supportive nursing care	Stands alone, walks with support, N speech, interest in toys, N tone and reflexes, mild bilateral clonus + Allowed discharge home.
2 weeks	Parental care	Still needs help with walking, N tone, and reflexes, mild bilateral clonus,
2 months		Running well without falls, rides tricycle, clear speech and full conversation, N behaviour and moods, N power, tone and reflexes, mild clonus +
6 months		Remains well as above Repeat MRI brain - completely NORMAL
12 months		Well, started kindergarten, N power, tone and reflexes, clonus absent.

* time from initiating of IVIG therapy

Discussion

Acute Disseminated Encephalomyelitis is a rare, demyelinating disorder of the central nervous system which is thought to be immune-mediated^{1,2}. It usually affects children and is preceded by a recent viral infection or immunization, hence it is also known as infectious or para-infectious encephalomyelitis.

The disease is characterized by the acute onset of multifocal neurological deficits and usually follows a monophasic course but recurrent episodes may occur^{1,2}. When ADEM is recurrent, the distinction from Multiple Sclerosis (MS) becomes difficult. Short symptom-free intervals (less than three weeks) favour ADEM. Brain CT is often normal and magnetic resonance imaging (MRI) scan is required to establish the diagnosis and to distinguish from MS^{1,3}. Large, lobar, symmetrical lesions involving the subcortical white matter (instead of periventricular), brain stem and corpus callosum suggest ADEM while periventricular and smaller lesions are seen in MS.

Although ADEM is self-limiting, recovery is usually prolonged and can take weeks to months³. Until

recently, corticosteroids were the only widely used treatment and are thought to shorten the duration of neurologic symptoms. However, the response has been variable and its efficacy has not been established in adequately controlled trials^{1,2}. Alternative modalities including plasmapheresis and immunoglobulins have also been used on an ad hoc basis.

Recently there have been three published reports on the successful use of intravenous immunoglobulins (IVIG) in the treatment of ADEM¹⁻³. Assa et al report two children aged 5 1/2 and 6 1/2 years. The first child presented with acute hemiplegia and the second with facial paralysis and ataxia. Both children had MRI lesions consistent with a demyelinating process. Both received IVIG 2g /kg over a five-day course. In both children, there was a marked improvement in neurological signs seen from 24-48 hours of commencement of therapy. Both children were also fully recovered on their six-month review as were their repeat MRI brain scans. Hahn et al in their report describe an 8 year old boy with multiple episodes of disseminated demyelination of both hemispheres, cerebrum and brain stem who initially responded to corticosteroid therapy but

developed exacerbations after cessation of treatment. He too improved rapidly during a course of IVIG and remained symptom-free for 6 months. Kleinman and Brunquell describe an 11 year old boy with ADEM who had multiple lesions in both hemispheres and cerebellum. He also responded rapidly to a course of IVIG with complete resolution of symptoms.

In the case described here, the initial presentation of a child with fever and acute neurological symptoms and signs initiated the diagnosis of an infectious meningo-encephalitis. However, the investigations refuted this diagnosis and in fact the child was seen to improve spontaneously. The second admission with a recurrence of neurological signs concomitant with a rising titre of Salmonella Typhi antibodies prompted the thoughts of unusual causes of encephalopathy as well as ADEM. Unfortunately the MRI brain was not available at this point to aid in the diagnosis of ADEM.

It is possible that a non-specific viral infection during the first episode had reactivated a previous Salmonella typhi infection. However, we could not elicit a history of any such previous infection from the family. Hence, the child was given a full course of antibiotics for typhoid and again showed some improvement in neurological signs. This of course could have been unrelated to the antibiotics and may in all probability have been the initial spontaneous recovery of the demyelinating disorder. The final diagnosis of ADEM was hence only confirmed on the third episode of recurrence of neurological signs.

Immunoglobulins are a concentrated fractionated human blood product, derived from the pooled plasma of several thousand donors. It contains a wide spectrum of antibodies of which 95% to 99% are of the immunoglobulin G subtype. It was initially developed in 1981 to treat primary and secondary immunodeficiency

states but has since also become standard therapy for Immune Thrombocytopenic Purpura and Kawasaki Syndrome. This benefit has stimulated clinical research trials to examine its use in other disorders believed to have an auto-immune basis. Consequently, IVIG has been shown to be effective in cases of Guillain-Barre syndrome and other immune-mediated neurological disorders such as myasthenia gravis³. The mechanism of action of IVIG in these conditions remains controversial. Idiotype/anti-idiotypic interactions may be the most important. Because IVIG is obtained from a diverse pool of donors, it provides the patient with a vast array of anti-idiotypic antibodies, largely from those who have recovered from a similar disease or controlled it at a subclinical level. These anti-idiotypic antibodies can bind to autoantibodies hence neutralising them. They may also bind to receptors on B and T lymphocytes. Binding to receptors on regulatory T cells leads to inhibition of cytokine release, with consequent diminished activation of the production of autoantibodies by B lymphocytes.

Based on the evidence of the use of immunoglobulins in Guillain-Barre syndrome and myasthenia gravis as well as the three reports delineated above, we decided to use this mode of therapy in our patient. In addition, side effects are notably rare with IVIG use.

The improvement noted in our patient was dramatic and concurrent with the course of therapy. The response was clearly seen within 48 hours of commencement of IVIG. This temporal relationship between treatment and improvement suggests a direct effect. Until further evidence from rigorous controlled trials become available we must proceed on the experiences from small case series. We conclude that IVIG should be considered as a first-line treatment in acute disseminated encephalomyelitis.

References

1. Assa A, Waternberg N, Bujanover Y, Lerman-Sagie T. Demyelinative brainstem encephalitis responsive to intravenous immunoglobulin therapy. *Pediatrics* 1999; 104(2): 301-4.
2. Hahn JS, Siegler DJ, Enzmann D. Intravenous gammaglobulin therapy in recurrent acute disseminated encephalomyelitis. *Neurology*.1996; 46: 1173-174.
3. Kleinman M, Brunquell P. Acute disseminated encephalomyelitis: response to intravenous immunoglobulin? *J Child Neurol*. 1995; 10: 481-83.