

Penetrating Laryngotracheal Trauma Resulting in Vocal Cord Avulsion

I R Lim, FRCS*, C Y Aw, FRCS**

*Registrar, **Consultant, Department of Otolaryngology, Changi General Hospital, 2 Simei Street 3, S(529889), Republic Singapore

Summary

Penetrating neck trauma present difficult management issues by virtue of their rarity. Undiagnosed laryngotracheal injuries have serious implications, especially in the context of multiple trauma, where other injuries overshadow that of the laryngotracheal complex.

This is a case of a schizophrenic patient with multiple self-inflicted cuts on his throat and abdomen. Injuries include open, comminuted laryngeal complex lacerations with vocal cord avulsion, as well as evisceration of small bowel.

Adequate assessment using both direct laryngoscopy and rigid endoscopy, coupled with open exploration, allowed optimal exposure and fixation of the larynx in the anatomical configuration.

The post-operative outcome of the airway and voice remained satisfactory at follow-up. A high index of suspicion coupled with adequate surgical approach allowed establishment of a functional larynx.

Key Words: Penetrating trauma, Laryngotracheal complex

Introduction

Penetrating neck trauma can present difficult diagnostic and therapeutic dilemmas. The mechanisms of injury include missile trauma (bullets or rivets) and knife injuries (stabs or cuts). Whether in the context of multiple or isolated neck trauma, the extent and severity of injury sustained varies significantly. The literature¹ reveal that the structures involved (in descending order of frequency) are: vascular, aerodigestive tract, thoracic, neurological and others.

Pure laryngotracheal trauma present as less than 1% of all trauma in major trauma centers². This rarity potentially increases with underdiagnosis. Further iatrogenic injury from endotracheal intubation increases risk of long-term complications and poor functional prognosis with respect to airway and voice.

The following case report will serve to highlight the important concepts in the management of penetrating neck trauma with an emphasis on trauma to the laryngotracheal complex.

This article was accepted: 7 January 2003

Corresponding Author: Lim Ing Ruen, Department of Otolaryngology, Changi General Hospital, 2 Simei Street 3, S(529889), Republic Singapore

Case Report

A 30 year old Bangladeshi with a background history of schizophrenia. He was found in a semi-conscious state, with multiple self-inflicted slash wounds to the center of his neck and abdomen. There was air-leak but minimal bleeding through his neck wound, and, evisceration of small bowel through the abdominal incision. Standard resuscitative measures were taken, the airway was secured via an oral endotracheal tube by the Emergency team. Since the vital signs were stable otherwise, and as the immediate concern was the viability of small bowel and risk of peritonitis, he was taken to the operating theatre. Priority was accorded to the abdominal injury after airway was secured. The "door-to-table" interval was 20 minutes.

He underwent exploratory laparotomy. There was no transmural bowel injury. Primary closure of abdomen was performed over drains, after copious peritoneal lavage.

The neck injury was assessed by the Otolaryngologic team. Proper assessment and photodocumentation required visualization through both external and endoscopic views. External exploration through the open wound revealed open, comminuted, full-thickness lacerations limited to the prominence of the thyroid cartilage, caused by repeated and forceful cutting movements via a single skin incision, suggestive of underlying determination.

Flexible endoscopy (the standard bedside tool) was difficult in an intubated, unconscious patient. View was poor due to tissue collapse and secretions, even after suction was applied. Extent of endolaryngeal injury was apparent only after direct laryngoscopy with suspension, together with the telescopic visualisation. Rigid esophagoscopy was also performed.

Both vocal cords were avulsed completely from the anterior commissure. The injury to the laryngotracheal complex was limited to the glottis.

There were no injury to the great vessels, cervical esophagus or neural structures. Figure 1.

A tracheostomy was performed for intermediate airway management. The anatomical configuration of the anterior commissure was recreated by suturing the anterior ends of the vocal ligaments to the remnant thyroid cartilage perichondrium. This was doubly secured to the external skin, over a intervening silastic sheet on the skin, using non-absorbable Prolene sutures. This external silastic counter-support served to recreate sufficient tension in the avulsed vocal ligaments. Another silastic keel was fashioned and anchored between the vocal cords at the anterior commissure to prevent potential anterior glottic webbing and left in place for 6 weeks. As the laryngeal framework seemed stable, and telescopic view of the subglottis showed no injury, there was no need for an endolaryngeal stent. Figure 2.

Patient underwent psychiatric treatment post-operatively. Swallowing and speech recovered. The endoscopic assessment after keel removal at 6 weeks was free of webbing or stenosis. Voice after decannulation was satisfactory.

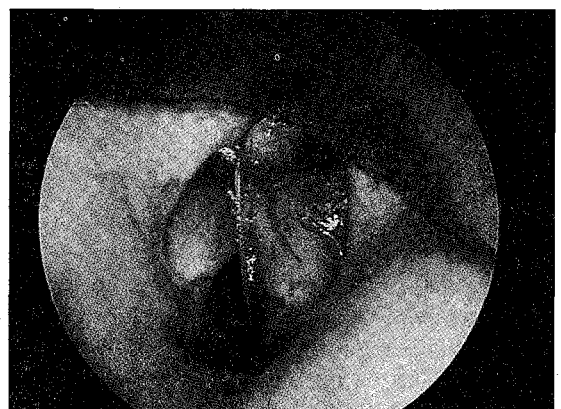

Fig. 1: Endoscopic view of avulsion of anterior ends of both vocal cords at the anterior commissure

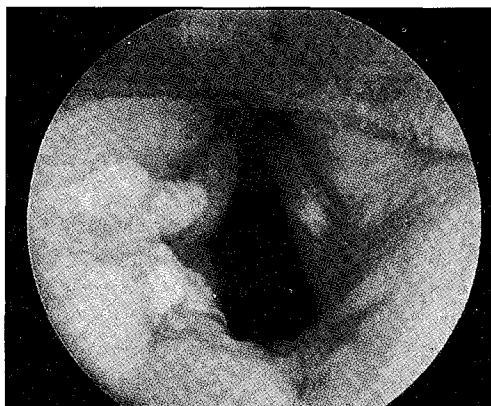


Fig. 2: Intra-operative view of keel at anterior commissure to prevent anterior web formation

Discussion

The goals of management of any trauma case have always been that of preservation of life (i.e. Airway, Breathing, Circulation) followed by that of restoration of function (i.e. airway, swallowing, prevention of aspiration, in this context). It is sometimes a necessary evil to accord priority to the former with the inadvertent compromise to the latter. However, recognition of this shortcoming, is the first step towards improved management.

The management of penetrating neck trauma is difficult due to several reasons. The complex anatomy of the neck results in a wide range of injuries involving any structure, be it vascular, aerodigestive or neural. Different degrees of injury causing a wide range of symptoms means that occult injury may be missed. Unrecognised injury may be further exacerbated by iatrogenic trauma, thus potentially compromising outcome. This is especially so when endotracheal intubation can potentially cause further laryngotracheal injury.

The discussion will highlight on the current concepts in laryngotracheal trauma:

1. Initial assessment of injury,
2. Initial airway management,
3. Definitive management of penetrating laryngotracheal injury.

1. Initial assessment of injury

Clinical indicators of LTC trauma include: hoarseness, stridor, subcutaneous emphysema, distortion of laryngeal prominence. Standard bedside assessment with the flexible nasoendoscopy is of value in the stable, conscious patient, and, should always be done if feasible. Occult injury may however still be missed. Further assessment, either under anesthesia with rigid endoscopy, or, with imaging, is still needed for injury classification^{3,4} which guides subsequent management.

Decision on whether to proceed on with mandatory exploration or with imaging depend on stability of patient and mechanism of trauma. All penetrating LTC trauma and all unstable patients need mandatory exploration. Blunt LTC trauma can be assessed with imaging first before decision for surgical management.

Indeed, Miller¹, in his review, pointed out that the negative exploration rate for mandatory exploration (without aid of imaging) was an unacceptable 38 to 60%, compared to rate of 12 to 21% for selective exploration. This highlights the value of imaging in reducing the negative exploration rate of mandatory exploration.

2. Initial airway management

Alternative airway is needed in up to 30% of neck trauma. Tracheostomy is the superior mode of establishing airway if patient stability and surgeon expertise allows. This is often possible if the patient is able to reach the hospital without airway intervention. Indeed, Schaefer and many other workers^{2,3} have shown that tracheostomy is safer than intubation in the traumatized larynx. This is again illustrated in our case where there is a distinct possibility that the vocal cord avulsion is exacerbated by intubation!

Gussack² is one of the very few proponents of intubation ... but only if ... there is minimal LTC (laryngotracheal complex) trauma, as assessed by flexible nasoendoscopy at the bedside. However,

CASE REPORT

flexible nasoendoscopy is practical only in the conscious, cooperative patient. In the unconscious patient, secretions and soft tissue collapse severely limits visualization.

3. Definitive management

Principles of management¹⁻⁴ include:

- Minimising iatrogenic damage through mucosal preservation and the use of bipolar rather than monopolar diathermy.
- Minimising cartilage exposure by means of meticulous repair, mucosal advancement flaps and grafts (mucous membrane, dermis, split skin grafts).
- Minimising dead space through quilting sutures.
- Preventing endolaryngeal stenosis where there is extensive degloving injury by the use of keels at the anterior commissure for 6 weeks.
- Providing structural support if the cartilage is unstable. This is usually achieved through temporary endolaryngeal stents for about 6 weeks.

- Anatomical reduction and fixation of displaced fractures. Miniplates⁵ akin to fixation of long bone fractures have also been described.

This case illustrates a few important aspects of managing penetrating LTC trauma. This include the need for high index of suspicion of occult injury. It also highlights the superiority of rigid endoscopy (i.e. direct laryngoscopy with suspension and telescopic examination) over flexible endoscopy as a means of assessment and photodocumentation, especially in the unconscious patient. The risk of intubation of a traumatised larynx cannot be more apparent, hence emphasizing the advantage of early tracheostomy if airway intervention needed. Other principles e.g. the importance of anatomical reduction of both soft and cartilaginous structures all have a direct impact on the eventual functional outcome of the larynx with respect to airway and voice.

The limitation of this case report is that the post-operative follow-up assessment was less than six months.

References

1. Miller RH, Duplechain JK. Penetrating wounds of the neck. *Otolaryngol Clin N Am* 1991; 24: 15-29.
2. Gussack GS, Jurkovich G. Treatment dilemmas in laryngotracheal Trauma. *J Trauma* 1988; 28: 1439-43.
3. Fuhrman GM, Stieg FH, Buerk CA. Blunt laryngeal trauma: Classification and management Protocol. *J Trauma* 1990; 30: 87-92.
4. Schaefer SD, Close LG. Acute management of laryngeal trauma. *Ann Otol Rhinol Laryngol* 1989; 98: 98-104.
5. Woo P. Laryngeal framework reconstruction with miniplates. *Ann Otol Rhinol Laryngol* 1990; 99: 772-77.