

# Knee Crepitus from an Unusual Source

S Harwant, FRCSEd.\*, T A Borhan, FRCSEd.\*\*, S Sivakumar, FRCSEd.\*\*, J Jeevanan, MBBS\*\*, \*Universiti Putra Malaysia, 8th Floor, Grand Seasons Avenue, 72, Jalan Pahang, 53000 Kuala Lumpur, \*\*Institute of Orthopaedics and Traumatology, Hospital Kuala Lumpur, 50586 Kuala Lumpur

## Summary

A case report of a missed appendicitis presenting with abdominal wall necrotising fasciitis which extended up to the right knee. This subcutaneous collection in the prepatella region of the right knee presented as a crepitus and mimicked an intraarticular pathology.

**Key Words:** Knee Crepitus, Necrotizing Fasciitis, Appendicitis

## Introduction

Knee crepitus is a common orthopaedic finding which is associated with intra articular degenerative conditions, and is not usually viewed with serious concern in a General Practitioner or Outpatient setting. We describe a case of knee crepitus as a result of necrotising fasciitis from a missed appendicitis, that had a fatal outcome.

## Case Report

A 66 years old woman was admitted to the Surgical Department of Hospital Kuala Lumpur for increasing right loin pain of 6 days duration. She had been treated by her General Practitioner prior to admission with antispasmodics and analgesics, which did not relieve her abdominal pain. On admission, she was urgently referred to the Institute of Orthopaedics and Traumatology for management of an increasingly painful right knee swelling and crepitus which was of 3 days duration. She had also been prescribed a non-steroidal anti inflammatory by her General Practitioner for 'arthritis' of the right knee the previous week.

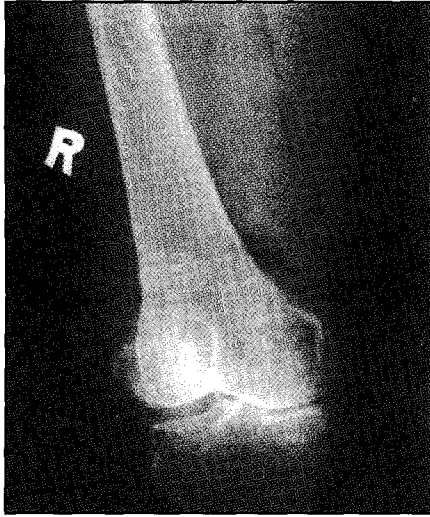Physical examination on admission revealed a toxic and febrile patient with leucocytosis of 26,500 cells / mm<sup>3</sup>. The right flank of the abdomen was guarded. The right knee was

swollen, with cutaneous purplish discoloration, and extremely tender to touch. Movement was severely limited by pain. A provisional diagnosis of septic arthritis of the right knee due to haematogenous spread from intraabdominal sepsis was made. She was commenced on intravenous cefoperazone 1 gram 12 hourly, and metronidazole 500 mg 8 hourly.

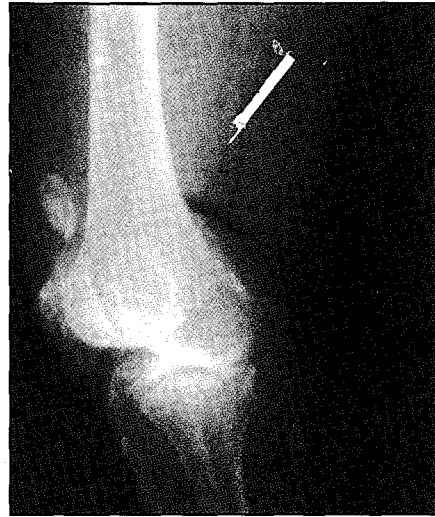
An attempt to aspirate the right knee revealed minimal intra articular fluid, however there was a collection of faeculent fluid in the pre patellar region. Radiographs of the right knee showed air - fluid levels (Figure 1 and 2). She had an emergency laparotomy, which confirmed a retrocaecal appendicular phlegmon and retroperitoneal necrotising fasciitis; extending into the right lower limb. Fasciotomy and debridment of the right thigh, prepatella region, posterior knee and right calf was also done. She required post-operative intensive care. She died the following day due to severe sepsis.

## Discussion

Knee crepitus is an extremely common orthopaedic finding, and relates to mechanical disturbances such as osteoarthritis'. The phenomenon of cracking and crepitus in joints was studied in detail by Unsworth et al<sup>2</sup>, and relates to the cavitation in the joint fluid under low pressure. While it may not be obvious clinically whether the knee crepitus is from the



**Figure 1: AP radiograph of the right knee with the air-fluid levels (shown with dark arrows). Note the subcutaneous air along the medial and thigh.**



**Figure 2: Lateral radiograph of the right knee showing air fluid level at the posterior knee.**

surrounding tissues or intraarticular; careful clinical examination and review of knee radiographs can distinguish the origin of crepitus. Subcutaneous crepitus suggests a gas forming organism, and in certain clinical situations; clostridial, streptococcal A, haemolytic streptococci and non clostridial anaerobic infections must be suspected and effectively dealt with by a combination of debridement or amputation with aggressive intravenous antibiotics<sup>3</sup>. These gas forming organisms can originate from either external wounds or from the intestines.

There are no reports in the English literature (to the best of our knowledge) of the occurrence of lower limb necrotizing fasciitis as a consequence of a missed appendicitis. In order for

a prepatella collection to occur from a missed appendicitis, the necrotising fasciitis has to extend from the peritoneum up to the subcutaneous plane in the abdominal wall; and track down into the lower limb in this plane. In this case, the subcutaneous collection on the prepatella region of the right knee mimicked an intraarticular knee swelling, leading her General Practitioner to conclude an 'arthritis' of the knee. Failure to relate the abdominal symptoms with the knee crepitus lead to the delay in appropriate treatment for this patient, and her severe sepsis which eventually caused her death.

## References

1. Nade S. Clicks, Clunks, Creaks and Crepitus. *Current Orthopaedics* 1992; 6: 60-4.
2. Unsworth A., Dowson D, Wright V. Cracking Joints. *Ann Rheum Dis* 1971; 30: 348-58.
3. Zubaidah AW, Lim VKE. Necrotizing Fasciitis. *Med J Malaysia* 1996; 5: 134-36.