

Dysphagia Due to Anterior Cervical Osteophytes - A Case Report

B A Kareem, M S (Ortho)*, M Sofiyan, M S (Ortho), S Subramanian, M S (ORL)*, *Faculty of Medicine and Health Sciences, University Putra Malaysia, 8th Floor, Grand Seasons Hotel, 72, Jalan Pahang, 53000 Kuala Lumpur **Consultant, Orthopaedic Department, Hospital Kuala Lumpur, Jalan Pahang 50586 Kuala Lumpur**

Summary

Dysphagia due to osteophytes in a young person is uncommon. We present a rare case of Forestier's disease causing dysphagia in a young lady without other bony involvement. The osteophytes were surgically removed and her symptoms resolved completely.

Key Words: Cervical osteophytes, Dysphagia, Forestier's disease

Introduction

Cervical osteophytes are common in advancing aging population. Dysphagia induced by cervical osteophytes although uncommon is an important and treatable cause of dysphagia that must be identified by a modified barium swallow. Asymptomatic osteophytes of the anterior cervical spine are a common occurrence, being found in 20 - 30% of the elderly people. These are largely asymptomatic, however are recognized as an unusual cause of dysphagia, which may occur secondary to the mechanical compression with partial obstruction or periesophageal inflammation caused by pharyngo-esophageal motion over the osteophytes¹. The most likely mechanism is interference with swallowing at the pharyngo-esophageal junction, although osteophytes in the lower cervical spine may also interfere with oesophageal peristalsis². In Forestier's disease the new bone forms at the waist of vertebral body and extend across to adjacent vertebra.

Case Report

A 43 year old Malay lady was referred from Otolaryngology clinic with history of neck pain, foreign

body feeling and progressive dysphagia for the past four months. The dysphagia was more for solid foods than to liquid. There was no associated weight loss or hoarseness of voice or any history of injury to neck. On physical examination, she was well built and cheerful. Indirect laryngoscopic examination showed a retropharyngeal swelling invaginating the posterior wall of oropharynx. There was no neurological deficit that could be related to cervical spine pathology.

X-rays of lumbar and thoracic spine was taken to rule out ankylosing spondylitis. But the cervical radiography showed osteophytes from C₃ - C₆ even though the discs were normal. A barium swallow was performed to investigate for her dysphagia to exclude any filling defects. Lateral cervical X-ray showed anterior osteophytes involving C₃ - C₆ vertebrae with posterior indentation on the oesophagus (Figure 1). Motility of oesophagus was normal on barium swallow. There was no hold up of barium and mucosal abnormality. Routine haematological investigations were normal.

Cervical osteophytes were then considered as the most likely cause of dysphagia. Removal of the anterior osteophytes was necessitated.

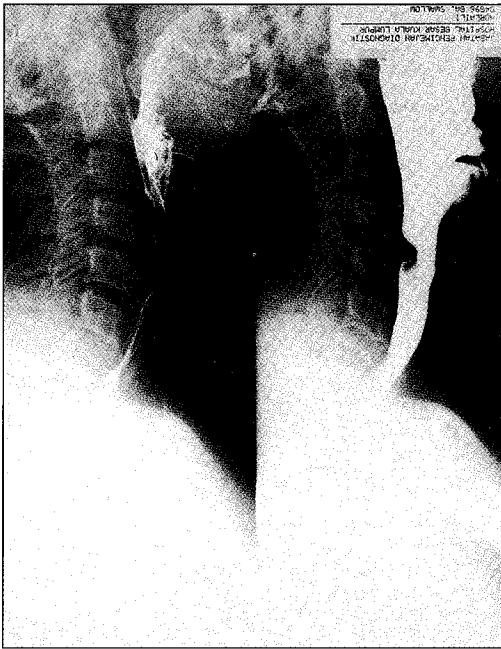


Fig. 1: Lateral view of cervical spine with barium swallow.

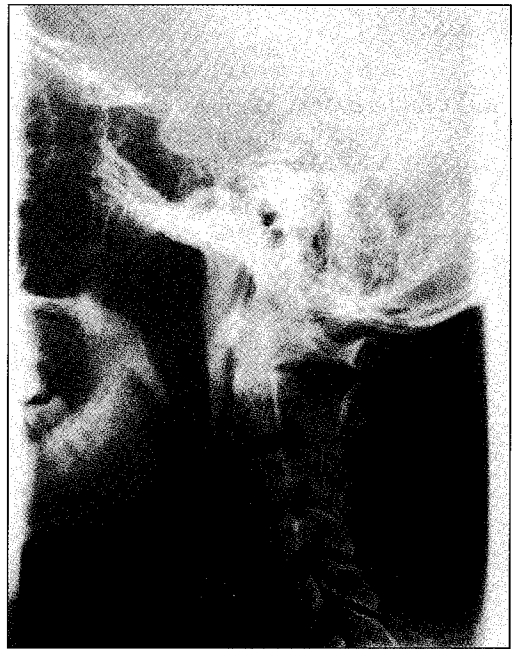

Fig. 2: Lateral view of cervical spine (postoperative).

Under general anaesthesia, a transverse incision over left side of neck was made. The trachea and the oesophagus were retracted medially, and the carotid sheath retracted laterally to expose the osteophytes which were then removed. Post operative period was uneventful. On the 5th day, patient was able to take semisolid food. On follow up she was able to enjoy the solid food without any discomfort. Postoperative x-ray showed there was no osteophytes (Figure 2). The patient was followed up for a period of six months with no further recurrence of symptoms.

Discussion

Cervical osteophytes are common but those giving rise to mechanical obstruction are rare. Forestier's disease characterized by a severe diffuse ankylosing hyperostosis of the spine, calcification of the anterior spinous

ligament (typically spanning at four contiguous vertebrae) and extra spinous ligamentous hyperostosis is unknown in its aetiology but it is found in 6 - 12 % of patients examined at autopsy¹.

Anatomically the oesophagus is fixed to the cricoid cartilage and the diaphragm, as the oesophagus passes from the neck to the abdomen. Thus pathophysiologically the oesophagus is most likely to be compressed in the neck by the anterior vertebral osteophytes in the area of the cricoid. The most common level involved is C₃ - C₅². Tumours are the most common causes for dysphagia in elderly patient. So caution must be taken to rule out unrecognized oesophageal carcinoma. The above case is an unusual cause of dysphagia due to cervical osteophytes (Forestier's disease) in aspect of age in cervical vertebra where no cases have been reported to our knowledge in this region.

CASE REPORT

References

1. A.G. Bridger, W.A. Stening and G.P. Bridger. Cervical osteophytes an unusual cause of dysphagia. *Aust. N.Z.J. Surg*, 1996; 66: 261-64.
2. M.Y.Y. Tung, K.K. Tan. An unusual cause of Dysphagia. *Singapore Med. J.*, 1996; 37: 315-17.
3. F.W.Gamache.Jr, R.M.Vorrhies. Hypertrophic cervical osteophytes causing dysphagia. *J. Neurosurgery*, 1980; 53: 338-44.