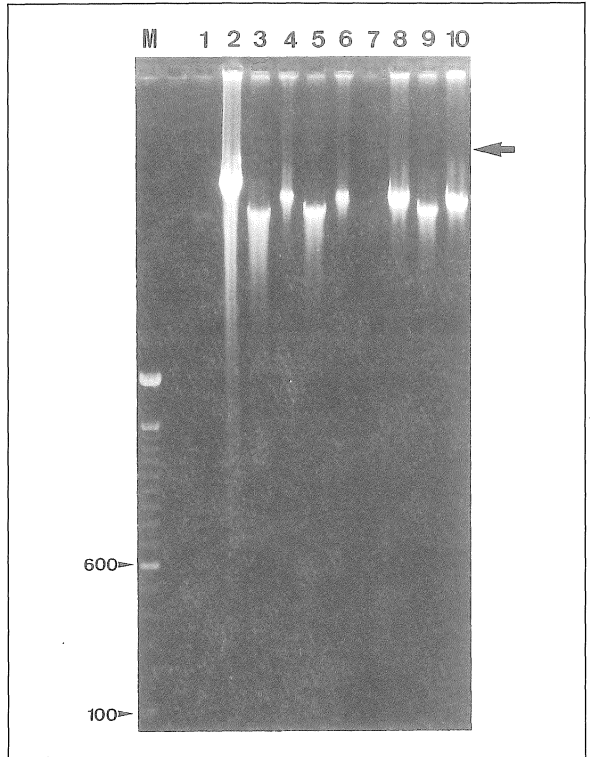


# Induction of Apoptosis in Neurogenic Pulmonary Edema

Dear Sir - It was reported recently in Malaysia that four children between the ages of 3 to 4 years old died as a result of Enterovirus 71 (EV71) infection<sup>1</sup>. All four children showed evidences which implicated pulmonary edema as the main cause of death. In general, pulmonary edema or abnormal accumulation of extravascular fluid in the lung is a life-threatening condition which can occur as a result of myocardial infarction, cardiac dysfunction, left ventricle or mitral valve incompetence, allergic reactions and injuries to the central nervous system. In the later, it is postulated that significant damage to the vasomotor centre in the medulla as suggested in the above cases of EV71 infection could lead to neurogenic pulmonary edema. In these patients, however, the cellular pathophysiological changes in the lung were not described. Here, we present evidence derived from one of the child which suggests the potential involvement of apoptosis in pulmonary edema.

Tissue samples from the patient (Case 1, as reported by Lum et al.)<sup>2</sup>; intended for virus isolation were made available by Prof Lam Sai Kit (University Malaya Medical Centre). Tissues were pulverized to release cells as previously described<sup>1</sup> and the cells were then sedimented by centrifugation at 800 x g. Lysis solution consisting of 1% N-lauroylsarcosine, 0.2% sodium deoxycholate, and proteinase K (1mg/ml) in L-Buffer (0.01M Tris-HCl, pH 7.6; 0.02M NaCl; 0.1M EDTA) was added to the cell pellet and cellular DNA was electrophoresed in a 1.5% agarose gel.

Extensive ethidium bromide-stained DNA smearing was not detected in all the tissue samples suggesting that no non-specific generalised degradation of cellular DNA has taken place. DNA fragments indicating internucleosomal DNA fragmentation, a hallmark of apoptosis, however, were repeatedly noted in the child/s lung tissue (Fig. 1 lane 2). The fragmentation was unlikely to be due to the non-specific degradation caused by treatments of the tissue since all other tissues



**Fig. 1:** Detection of apoptosis in neurogenic pulmonary edema. Total cellular DNA was extracted from samples of a patient who succumbed to EV71 encephalomyelitis (lanes 1-10; stool, lung, liver, left brain, right ventricle, right brain, meninges, left ventricle, septum, left ventricle, respectively). DNA was separated in a 1.5% agarose and stained with ethidium bromide. Apoptotic cellular DNA is indicated by laddering of the DNA in repeating internucleosomal units of 200 bp. An unknown DNA (arrow) is present in the liver (lane 3), right ventricle (lane 5) and septum (lane 9) of the patient. The 100 bp DNA marker (M) is used for size indication.

were similarly treated. This finding raised the possibility that induction of apoptosis is associated with the pulmonary edema noted by chest X-ray of the child. Whether accumulation of the fluid triggers activation of the apoptotic processes or vice versa resulting in pulmonary collapse will remain unknown in this patient. Nonetheless, it is perhaps possible to investigate the potential role of apoptosis in pulmonary edema using appropriate models.

Even though EV71 has been implicated as the causal agent of the disease in this child, no evidence suggesting a direct involvement of the virus in the lung was obtained. The reverse transcription polymerase chain

reaction (RT-PCR) performed using the tissues total RNA failed to amplify any enterovirus genomic sequences. Nevertheless, as previously reported<sup>1</sup>, EV71 was eventually isolated from the cerebrum after four passages in Vero cell cultures leading to the suggestion that the child may have succumbed to neurogenic-associated pulmonary edema. Regardless, our result presented here suggests that induction of apoptosis could be an important cellular pathological mechanism in neurogenic pulmonary edema.

Abu Bakar S, Ph.D., Shafee N, MMedSc, H Y Chee, MMedSc, Department of Medical Microbiology, University Malaya Medical Centre, 50603, Kuala Lumpur.

---

## References

1. Lum LCS, Wong KT, Lam SK, Chua KB, Goh AYT, Lim WL, Ong BB, Paul G, Abu Bakar S, Lambert M. Fatal Enterovirus 71 encephalomyelitis. *J Pediatr* 1998; 133: 795-98.