

The Association of Uvulo-Palatoglossal Junctional Ulcers with Exanthem Subitum: A 10-year Paediatric Outpatient Study

K B Chua, MRCP, Department of Medical Microbiology, Faculty of Medicine, University of Malaya, 50603, Kuala Lumpur

Summary

A 10-year follow-up of children having exanthem subitum (ES) seen in an outpatient paediatric clinic, Kuala Lumpur, Malaysia shows that uvulo-palatoglossal junctional (UPJ) ulcer is a reliable early clinical sign of ES. During this period, 1,977 children (1,086 males, 891 females) had adequate follow-up from the age of 3 months to 24 months old. 897 children (478 males, 419 females) were noted to have UPJ ulcers. Of these 897 children, 855 (459 males, 396 females) presented with the classical clinical features of ES of maculopapular rash following 3 to 4 days of fever. The positive predictive value and the negative predictive value of UPJ ulcers in the clinical diagnosis of ES are 95.3% and 100% respectively. Among the 855 children with clinical features of ES, a provisional diagnosis of ES could be made in 781 children during the pre-eruptive phase by the presence of the UPJ ulcers. The other 74 children already had the rash at the time of consultation at the clinic.

The peak age of occurrence of ES was 6 months old with 98.2% of the total cases of ES seen between the age of 4 and 12 months. There was no significant gender difference in the incidence of ES nor any seasonal variation. Mild to moderate diarrhoea was the other commonly associated clinical feature which usually presented from the third febrile day onwards.

Key Words: Exanthem subitum, Uvulo-palatoglossal junctional ulcers.

Introduction

The clinical features of roseola infantum was first described in 1913 by Zahorsky¹ and renamed in 1921 by Veeder and Hempelmann² as exanthem subitum (ES) because of the acute and unexpected nature of the fever and rash. Thereafter many investigators had documented its clinical manifestations³⁻⁸ and also attempted to clarify its aetiology^{9,10}. However, the causative agent remained unknown until 1988. In 1986, Salahuddin *et al*¹¹ isolated a new human herpesvirus (human B-lymphotropic virus) without knowing its relationship to any clinical entity. In 1988 Yamanishi *et al*¹² isolated the same virus, renamed

human herpesvirus 6 (HHV 6), from patients with ES and also demonstrated seroconversion to the virus, thus, establishing the aetiologic cause of ES. Further published reports showed that primary HHV 6 infection in young children can be asymptomatic or present as febrile illness without the typical maculopapular rash¹³⁻¹⁶. However, the diagnosis of ES remains very much clinical and its characteristic features as documented thus far are :- 1) age of onset between 3 months and 2 years; 2) no gender predominance; 3) acute onset with high fever which continues for 3 to 4 days; 4) no abnormal findings upon physical examination except for mild redness of the throat; 5) appearance of pink maculopapular rash on defervescence

which fades within 3 to 4 days; and 6) good prognosis with no sequelae.

From April 1985 to July 1994, a prospective cohort study of children from 3 to 24 months of age attending a private paediatric outpatient clinic (Chua Child Clinic) in Cheras, Kuala Lumpur, Malaysia was carried out to determine whether the presence of uvulo-palatoglossal junctional ulcers was an early sign of ES.

Materials and Methods

Time frame and population selection:

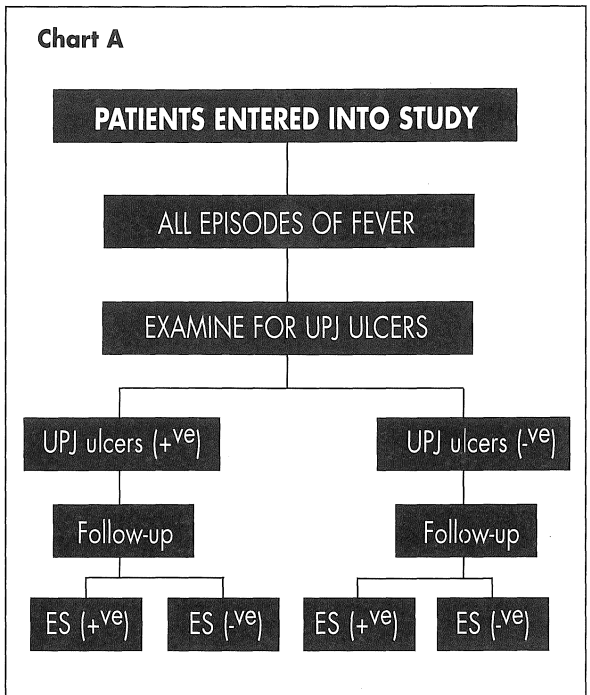
This prospective cohort study was for the period from April 1985 to July 1994. The study population consisted of children first seen in the paediatric outpatient clinic at the age of 3 months old with adequate outpatient follow-up until the age of 24 months old. More than 90% of the children seen in the clinic were Chinese with less than 10% consisting of Malays, Indians and other races. The reasons for the first visit to the clinic were: - 1) routine post-natal check-up; 2) requiring second dose of hepatitis B vaccination or 3) medical illness. The criteria of adequate outpatient follow-up till 2 years old were:- 1) all scheduled vaccinations were done and 2) all medical illnesses were consulted at the stated clinic. Only children who had completed the follow-up adequately were included in the study.

The flow-chart A summarises the design of this prospective study.

Clinical diagnosis and type of follow-up:

The clinical diagnosis of ES for all the cases was made by the same paediatrician based on the criteria as described earlier. Uvulo-palatoglossal junctional soft palate ulcers were specifically looked for in children having high fever (axillary temperature > 38°C) and paucity of other clinical signs. Provisional diagnosis of ES was made whenever UPJ ulcers were present during the pre-eruptive phase of the illness. The types of follow-up for these patients with UPJ ulcers during the pre-eruptive phase of the illness were:-

1. review in the clinic at the anticipated date of defervescence and exanthem.



2. review through telephone for those who were unable to attend the clinic for the follow-up.
3. for those not accessible by telephone, the parents were requested to note down the clinical course of the illness together with any of the specified associated clinical features and subsequently reported to the paediatrician at the next visit to the clinic.

More than 90% of the patients returned to the clinic for review at the anticipated date of defervescence and exanthem while the rest were diagnosed based on telephone interviews and recorded notes by parents; specifically on the presence of any maculopapular rash at the day of subsidence of fever. The parents were also taught tepid sponging besides giving antipyretic to control the body temperature so as to avoid hyperpyrexia and possibility of associated febrile convulsion. Those patients with seizure or any deterioration of clinical signs such as poor feeding, lethargy or drowsiness were reviewed in the clinic earlier than the appointment dates given.

The febrile children were also monitored for other associated clinical features such as diarrhoea, running nose, cough, raised anterior fontanelle, convulsion and for early signs of sepsis or meningitis.

The study group was divided into 4 categories.

- A) No record of clinical occurrence of ES.
- B) Occurrence of ES with a provisional diagnosis made during the pre-eruptive phase by the presence of UPJ ulcers.
- C) Occurrence of ES in which the exanthem was already present at the time seen in the clinic.
- D) Presence of UPJ ulcers but did not develop exanthem after 3 to 4 days of fever.

Statistical tests:

The statistical tests applied in this study are Chi-square, Fisher's exact and Kruskal Wallis tests. All the results are based on the significance of $p < 0.05$.

Analysis of seasonal variation in the incidence of ES is from data collected from the beginning of 1986 to the end of 1991. Data excluded from this analysis are from 1985 which was not recorded over a full year, and for the years 1992 and 1993, as several cases did not complete the 24-month follow-up.

Results

From April 1985 to July 1994, 1,977 (1,086 males, 891 females) children aged 3 to 24 months were adequately followed up. Of these 1,977 children, 45.5% or 897 children (478 males, 419 females) were noted to have UPJ ulcers and 855 of the 897 (95.3%) went on to develop clinical features of ES (Table I). The incidence of ES in this study was 43.2% (855/1977).

Table II shows the distribution of children with and without ES in relation to the presence or absence of UPJ ulcers. The positive and negative predictive values of the UPJ ulcers and the occurrence of ES are 95.3% (855/897) and 100% (1080/1080) respectively. Further analysis indicates that there was a direct correlation of UPJ ulcers with the clinical manifestation of ES ($\chi^2 = 1810.01$, $p < 0.001$).

There was no statistical gender difference in the

Table I
Number of children in each clinical category

Category*	Male	Female	Total
A	608	472	1080
B	416	365	781
C	43	31	74
D	19	23	42
Total	1086	891	1977

- *A - No record of clinical occurrence of ES.
 B - Occurrence of ES with a provisional diagnosis made during the pre-eruptive phase by the presence of UPJ ulcers.
 C - Occurrence of ES in which the exanthem was already present at the time seen in the clinic.
 D - Presence of UPJ ulcers but did not develop exanthem after 3 to 4 days of fever.

Table II
Relationship between exanthem subitum (ES) and uvulo-palatoglossal junctional (UPJ) ulcers

	exanthem subitum	No exanthem subitum	Total
with UPJ ulcer	855	42	897
No UPJ ulcer	0	1080	1080
Total	855	1122	1977

Table III
Other clinical features seen in
855 children with exanthem subitum

Clinical feature	Male	Female	Total	Percent
Diarrhoea	205	190	395	46.2
Rhinorrhoea	34	31	65	7.6
Cough	9	8	17	2.0
Bulging anterior fontanelle	5	9	14	1.6
Convulsion	2	0	2	0.2

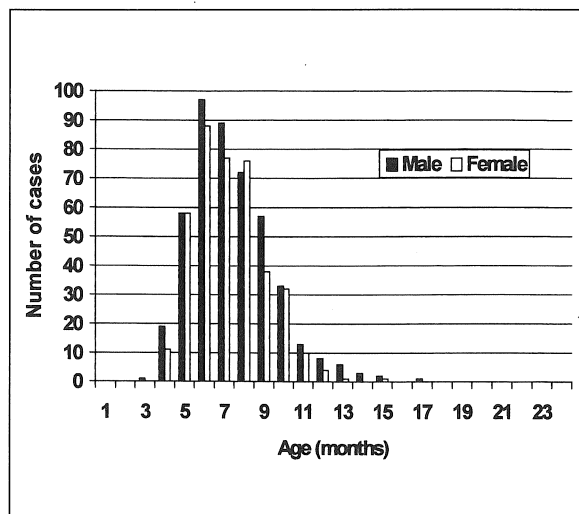


Fig 1: Incidence of exanthem subitum in children by age and sex.

incidence of UPJ ulcers ($\chi^2 = 1.67$, $p = 0.20$) and those who subsequently developed ES ($\chi^2 = 0.86$, $p = 0.35$).

Other features seen with ES are shown in Table III. Of the 855 children with ES, 46.2% also developed diarrhoea, 7.6% had rhinorrhoea and 2% had cough. A small number showed raised anterior fontanelle (1.6%) and convulsion (0.2%). There was also no statistical gender difference in the occurrence of these associated features.

The age of occurrence of ES is shown in Figure 1. The peak age of occurrence of ES in this study was 6 months for both sexes. Of the total 855 children who developed ES, 840 (98.2%) were infected between the age of 4 months to 1 year, of which 775 (90.6%) were between the age of 5 to 10 months showing a narrow age range of occurrence. Over the study period, no seasonal variation in the occurrence of ES was noted (Kruskal Wallis test, $p = 0.09$). None of the patients were tested serologically to confirm the aetiological agent of ES.

Discussion

Although the clinical description of ES dated back to

1913¹, subsequent progress in this field of medicine was rather slow. This disease was often confused with other viral exanthemata, drug allergy or various hypersensitivity reactions. It was in 1988 when there was renewed interest in ES after the causative agent was established by Yamanishi *et al*². Paediatricians become interested in the early diagnosis of ES for better management of their patients. An early and accurate clinical diagnosis will help avoid unnecessary prescription of antibiotics which may subsequently be mistaken as a drug allergy when rashes appear later in the course of the disease. Moreover, this condition is often wrongly diagnosed as measles or rubella and may lead to avoidance of vaccination for the child later.

Over a 10 year period of clinical observation, it was noticed that the presence of UPJ ulcers is a useful and reliable early sign of ES. They can be seen within 24 to 48 hours of onset of fever and normally heal with subsidence of the rashes. The ulcers typically appear singly (one on each side) at the junction of the anterior pharyngo-tonsillar (palatoglossal) folds and the base of the uvula (Figure 2). The ulcers can occasionally appear in crops of two to three on each side but at the same position. It was also noted that in younger infants (5 to 8 months old), the ulcers tend to be situated slightly

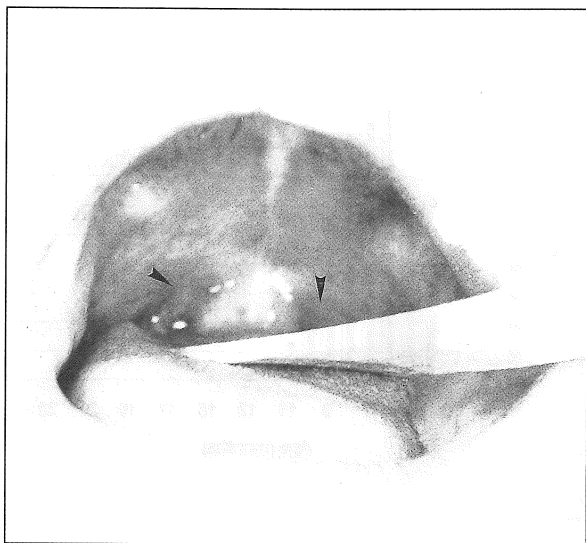


Fig 2: Uvulo-palatoglossal junctional ulcer in a 7 month-old infant with exanthem subitum.

more lateral to the described position. In this study, no ulcer was noted at other sites on the soft and hard palate. There was no associated ulcer on the buccal, gingiva or any part of the oral cavity as compared to other ulcerative lesions due to Coxsackievirus A and enterovirus 71 (Herpangina, Hand-Foot-Mouth Disease) or human herpesvirus 1 (herpetic gingivostomatitis) in which the ulcerative lesions can be found in any part of the oral cavity including the gingiva and oral pharyngeal wall.

The presence of uvulo-palatoglossal junctional ulcers is probably not a new clinical sign. Zahorsky¹ described a macular enanthem which was sometimes seen on the palate on the day preceding and coinciding with the eruptions but no mention of the specific location of this enanthem. Nagayama *et al.*¹⁷ had also noticed that "granules" or "papules" which they called Nagayama's maculae (spots) on either side of the root of the uvula on the first or second day of fever helped in the early diagnosis of ES. The papules as described by them probably progressed to develop into ulcers as noticed in this study. The reason for the lesions occurring at that specific area is not known.

In the present study, 823 children (Category B +D) were noted to have UPJ ulcers in the early febrile phase of the illness and 781 children (Category B) subsequently developed ES on follow-up. Hence, ES was accurately predicted in 94.9% of the children in the acute pre-eruptive phase of the illness. However, considering 897 children with UPJ ulcers and 855 children developed ES in a total of 1,977 follow-up children in this study, the positive predictive value and the negative predictive value of UPJ ulcers in the clinical diagnosis of ES are 95.3% and 100% respectively. Findings presented here indicate a direct association of UPJ ulcers and the occurrence of ES.

In this study, there were 42 children who had 3 to 4 days of fever without eruption of rashes following the subsidence of fever. This could possibly be due to HHV 6 infection but the group did not manifest the full blown clinical picture of ES. This was also observed by Suga *et al.*¹⁸

In this study, the main presenting feature of ES was high fever with paucity of other clinical signs and symptoms. This was also reported in other studies³⁻⁸. The other commonly presented symptom was diarrhoea. The frequency of loose stool was generally less than 5 times per day if no antibiotic was given. The diarrhoea was easily managed by reducing the strength of milk feed. Fourteen infants were noted to have raised anterior fontanelle during the febrile phase but none developed evidence of meningitis or encephalitis on follow-up and the fontanelle normalised with subsidence of fever. The association of raised anterior fontanelle with ES was also observed by Oski¹⁹. The important complication in patients with ES was febrile convulsion but the recorded incidence (0.2%) was quite low as compared to other studies^{20,21}. This might be attributed to early diagnosis and parents were informed of the importance of controlling the body temperature. Two of the patients (age 7 and 14 months) developed seizure after 24 to 48 hours of fever but had no neurological sequelae on follow-up until 3 years old.

In Malaysia, ES is a common febrile illness of children attending the outpatient clinic. The incidence rate is comparable to the estimated rate in Japan as reported by Kusuha *et al.*²². Accurate early diagnosis of ES is

important in the management of these children and the results from this study indicate the presence of UPJ ulcers is a reliable early clinical sign of ES.

Acknowledgements

Thanks to Mr L H Ong for his assistance in performing the statistical tests, Mr S C Cheng in the preparation of the manuscript and Professor S K Lam for reviewing this manuscript.

References

- Zahorsky J. Roseola infantum. *JAMA* 1913; 1446-50.
- Veeder BS, Hempelmann TC. A febrile exanthem occurring in childhood (exanthem subitum). *JAMA* 1921; 77: 1787-9.
- Cherry JD. Roseola infantum (exanthem subitum). In: Feigin RD, Cherry JD, eds. *Textbook of paediatric infectious disease*. 3rd ed. Philadelphia: Saunders 1992; 1789-92.
- Clemens HH. Exanthem subitum (roseola infantum): report of eight cases. *J Pediatr* 1945; 26: 66-77.
- Letchner A. Roseola infantum: a review of fifty cases. *Lancet* 1955; 2: 1163-5.
- Irving WL, Chang J, Raymond DR, Dunstan R, Grattan-Smith P, Cunningham AL. Roseola infantum and other syndromes associated with acute HHV-6 infection. *Arch Dis Child* 1990; 65: 1297-300.
- Asano Y, Nakashima T, Yoshikawa T, Suga S, Yazaki T. Severity of human herpesvirus-6 viremia and clinical findings in infants with exanthem subitum. *J Pediatr* 1991; 118: 891-5.
- Asano Y, Yoshikawa T, Suga S, et al. Clinical Features of Infants With Primary Human Herpesvirus 6 Infection (Exanthem Subitum, Roseola Infantum). *Pediatrics* 1994;93 : 104-8.
- Kempe CH, Shaw EB, Jackson JR, Silver HK. Studies on the etiology of exanthem subitum (roseola infantum). *J Pediatr* 1950; 37: 561-8.
- Hellstroem B, Vahlquist B. Experimental inoculation of roseola infantum. *Acta Pediatr* 1951; 40: 189-97.
- Salahuddin SZ, Ablashi DV, Markhan PD, et al. Isolation of a new virus, HBLV, in patients with lymphoproliferative disorders. *Science* 1986; 234: 596-601.
- Yamanishi K, Okuno T, Shiraki K, et al. Identification of human herpesvirus-6 as a causal agent for exanthem subitum. *Lancet* 1988; 1: 1065-7.
- Asano Y, Suga S, Yoshikawa T, Urisu A, Yazaki T. Human herpesvirus type 6 infection (exanthem subitum) without fever. *J Pediatr* 1989; 115: 264-5.
- Suga S, Yoshikawa T, Asano Y, Yazaki T, Hirata S. Human Herpesvirus-6 Infection (Exanthem Subitum) Without Rash. *Pediatrics* 1989; 83: 1003-6.
- Linnavuori K, Peltola H, Hovi T. Serology Versus Clinical Signs or Symptoms and Main Laboratory Findings in the Diagnosis of Exanthem Subitum (Roseola Infantum). *Pediatrics* 1992; 89: 103-6.
- Okada K, Ueda K, Kusahara K, et al. Exanthem subitum and human herpesvirus 6 infection : Clinical observations in fifty-seven cases. *Pediatr Infect Dis J* 1993; 12: 204-8.
- Nagayama T, Inoue K, Kawasaki K. Early Diagnosis of Exanthem Subitum and Isolation of Its Causative Virus. *Med J Kagoshima Univ* 1956; 8: 212-20.
- Suga S, Yoshikawa T, Asano Y, et al. Clinical and Virological Analyses of 21 Infants with Exanthem Subitum (Roseola Infantum) and Central Nervous System Complications. *Ann of Neurol* 1993; 33: 597-603.

ORIGINAL ARTICLE

19. Oski FA. Roseola Infantum. Another case of bulging fontanel. *Am J Dis Child* 1961; 101: 376-8.
20. Yoshikawa T, Nakashima T, Suga S, et al. Human Herpesvirus-6 DNA in Cerebrospinal Fluid of a Child with Exanthem Subitum and Meningoencephalitis. *Pediatrics* 1992; 89: 888-90.
21. Ishiguro N, Yamada S, Takahashi T, Togashi T, Okuno T, Yamanishi K. Meningo-encephalitis Associated with HHV-6 Related Exanthem Subitum. *Acta Paediatr Scand* 1990 ;79: 987-9.
22. Kusahara K, Ueda K, Miyazaki C, Okada K, Tokugawa K. Attack rate of exanthem subitum in Japan. *Lancet* 1992; 2: 482.