

# Clinical Features and Associated Radiological Abnormalities in 54 Patients with Cavum Septi Pellucidi

\*Guru Raj A K, FRCPI, \*\*Pratap R C, FRCPI, \*\*\*Jayakumar R, MD, \*Ariffin WA, FRCP, Departments. of \*Paediatrics, \*\*Medicine, \*\*\*Radiology, Universiti Sains Malaysia Hospital, Kubang Kerian 16150 Kota Bharu, Kelantan

## Summary

**Purpose** To determine the clinical and radiological features of the patients who were found to have cavum septum pellucidum (CSP) on the cranial computerized tomographic (CT) scans.

**Methods** Fifty four consecutive cases of cavum septum pellucidum were detected amongst 1,281 patients who underwent cranial CT scans; their clinical and radiological features were studied.

**Results** Recurrent seizures and developmental delay were the commonest presenting symptoms seen. Significant neurological deficits were present in 75.9% of these cases. Additional cerebral abnormalities were observed in the CT scan in 76% of cases, the commonest being cortical atrophy, cerebral infarction and hydrocephalus.

**Conclusions** There seems to be a strong association between CSP and certain neurological abnormalities in the population studied. Further interpretation of this study would be possible if normal population in this geographical area is screened for CSP using cranial CT scans or magnetic resonance imaging.

**Key Words:** Cavum septum pellucidum (CSP); Cranial computed tomography (CT) scan.

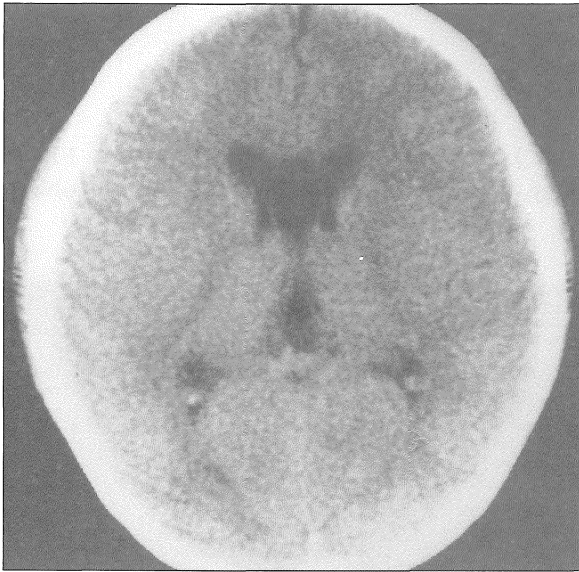
## Introduction

Till recently, cavities in the septum pellucidum were widely regarded as incidental findings of little clinical significance. However, the existence and the clinical significance of these cavities are being increasingly recognized by procedures such as cranial computed tomography (CT), ultra sonography and magnetic resonance imaging. A number of reports have linked the presence of cavum septum pellucidum (CSP) with varied symptomatology such as neurodevelopmental deficits, personality changes, psychosis, seizures and symptoms of increased intra cranial tension<sup>1-5</sup>. In the present study, we report the correlation between CSP and associated cerebral pathology.

## Materials and Methods

During the period June 1986 to May 1989, 1,281 cranial CT scans were performed at the University hospital (USM) and 54 of these were found to have a significant CSP. A significant CSP was defined as measuring >0.95 cm in the age group of birth to 6 months; in the later age (beyond 6 months), a detectable CSP on the CT scan was considered significant (Fig 1). These patients formed the material for the study. Their clinical presentation were studied; detailed developmental evaluation was done in the paediatric patients and perinatal history was analyzed to evaluate a possible perinatal neurological insult. All the patients under-

went systemic and neurological examination. Investigations such as electroencephalography, skull X-ray, bleeding and coagulation profile were done when indicated.



**Fig 1.** Cranial CT scan showing a wide cavum septum pellucidum

## Results

Of the 54 patients with CSP there were 34 males and 20 females. The age at which the condition was detected ranged from neonatal period to 68 years; over 50% of the patients were in the age group of birth – 1 year. The duration of symptoms ranged from one month to 6 years prior to the admission. The symptoms with which these patients presented included recurrent convulsions (27.8%), headache and developmental delay. This data is shown in (Table I). Generally seizures and developmental retardation were the common symptoms in children while headache and syncope were more common among adults. Clinical examination revealed various neurological deficits in 41 (75.9%) of the 54 patients and this is shown in (Table II). Associated cranial CT scan findings are listed in (Table III). Electroencephalography was done in 11 out of 15 patients with epilepsy of which 3 were normal; one showed cerebral hemispheric dysfunction; 7 had evidence of epileptic discharges, 5 of these showing partial seizures. The diagnoses in these patients confirmed to have CSP are listed in (Table IV).

**Table I**  
Presenting symptom in patients in whom C.S.P. was detected

Symptoms	No. Of Patients; n=54 (%)
Recurrent convulsions	15 (27.8%)
Neonate with poor sucking, lethargy, floppiness	9 (16.7%)
Headache	7 (12%)
Loss of consciousness	6 (11.1%)
Large head	4 (7.4%)
Developmental delay	4 (7.4%)
Head injury	5 (9.2%)
Personality and mood changes, hallucinations, violent behaviour	2 (4%)
Syncope	1 (2%)
Unsteadiness	1 (2%)
Bilateral Erb's palsy	1 (2%)
Frontonasal encephalocele	1 (2%)
Lumbosacral meningocele	1 (2%)

**Table II**  
Neurological abnormalities found  
in patients with C.S.P.

Neurological Deficit/ Abnormality	No of Patients; n=54 (%)
Generalised hypotonia	16 (29.6%)
Hydrocephalus	8 (14.8%)
Coma/ altered sensorium	7 (12.9%)
Hemiplegia	5 (9.2%)
Spasticity	4 (7.4%)
Ataxia	3 (5.6%)
Facial palsy (unilateral)	3 (5.6%)
Microcephaly	1 (1.8%)
Gaze palsy	1 (1.8%)
Erb's palsy (bilateral)	1 (1.8%)
Paraplegia	1 (1.8%)
Hyperkinesia	1 (1.8%)
No neurological deficits	13 (24.1%)

**Table III**  
Additional abnormalities on  
Cranial CT scan in patients with C.S.P.

CT Scan Findings	No. Of Patients n=54 (%)
Cerebral cortical atrophy	17 (31.5%)
Infarction	9 (16.7%)
Hydrocephalus	8 (14.8%)
Intra cranial bleed	7 (12.9%)
Intra cranial tumour	3 (5.6%)
Large cisterna magna	2 (3.7%)
Dandy Walker cyst	1 (1.8%)
Large deep sella turcica	1 (1.8%)

**Table IV**  
Clinical diagnosis in  
Patients found to have C.S.P.

Clinical Diagnosis	No. Of Patients n=54 (%)
Epilepsy	15 (27.8%)
Hydrocephalus	8 (14.8%)
Cerebrovascular accidents	8 (14.8%)
Head injury	5 (9.2%)
Cerebral palsy	4 (7.4%)
Haemorrhagic disease of the newborn	4 (7.4%)
Intra cranial tumours	3 (5.6%)
Congenital anomalies*	3* (5.6%)
Psychosis	2 (3.7%)
Choriocarcinoma	1 (1.8%)

\* includes: fronto nasal encephalocele (1), Edward's syndrome (1) and myelomeningocele (1)

### Discussion

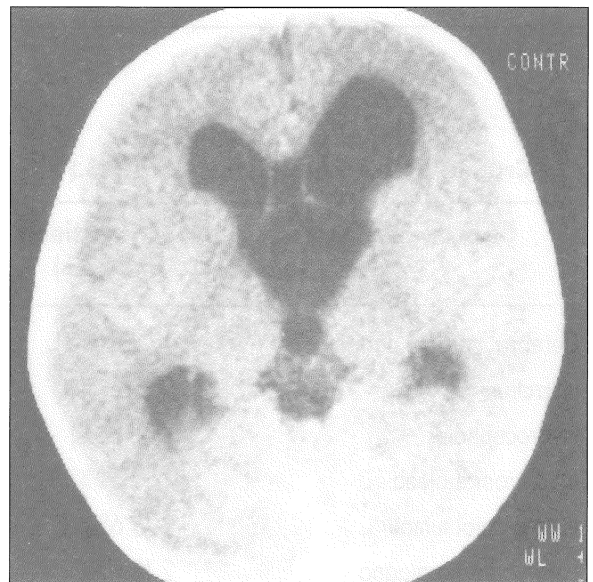
The septum pellucidum (SP) is a midline structure forming the medial wall of the lateral ventricles in the cerebrum. It is a consequence of the caudal growth of the corpus callosum and is demonstrable in human embryos of about 110 cm (crown-rump length)<sup>1</sup>. The formation of the septum pellucidum is believed to be related to the formation of other midline structures of the forebrain, particularly the corpus callosum<sup>4</sup>. The lamellae of the septum are separate in utero; the fusion of the lamellae begins at about 36 weeks of gestation and is complete in two thirds of full term babies. The SP has extensive connections with the hippocampus and is possibly a regulatory key station between the hippocampus and the diencephalon<sup>1</sup>. Absent septum pellucidum is known to be associated with epilepsy, mental retardation and optic atrophy as in septo-optic dysplasia. Persistence of CSP is often seen to be a part of a wide spectrum of abnormalities in the central nervous system<sup>1-5</sup>.

The prevalence of CSP in general paediatric population varies with the age. Mott et al showed that 36% of the normal new borns have a CSP; the presence of a wide CSP greater than 2 standard deviations above the mean width of 0.95 cm in an infant is, however, not a normal event<sup>6</sup>. Similarly persistence of a CSP beyond 6 months of age is considered abnormal<sup>4</sup>. Recently it has been shown that CSP was present in 14 out of 1,914 adults (0.73%); five of these were boxers, who have a recognized increase in the incidence of CSP<sup>5,7</sup>. One third of our patients were neonates in the age group of birth to 1 month, who had a wide CSP greater than 0.95 cm in width and were all symptomatic cases of birth asphyxia and haemorrhagic disease of the newborn. Hence we consider the CSPs abnormal in these cases.

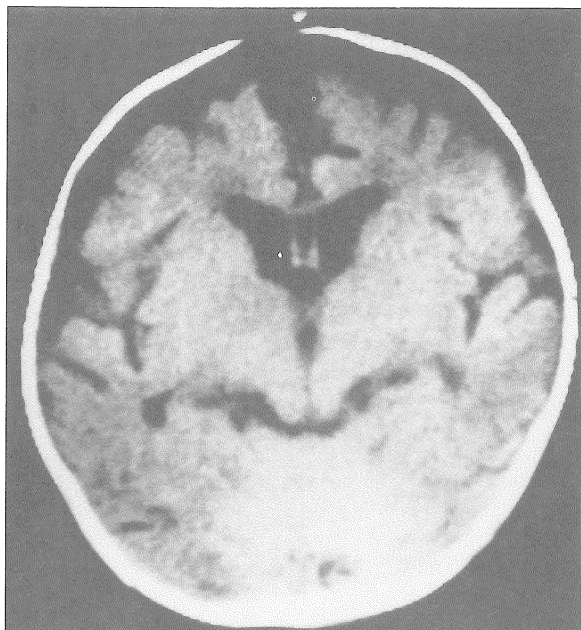
One of the controversial issues regarding CSP is whether it is associated with a defined set of symptoms or not. In 1938, Wilder proposed the term 'septum pellucidum syndrome' consisting of mental disturbances, frontal ataxia, speech disorders, epilepsy and bilateral pyramidal signs<sup>1</sup>. The recent literature links the presence of CSP to a wide spectrum of neuro-psychiatric illnesses<sup>3-5,8</sup>. In the present series, epilepsy was the chief presenting complaint in 37.5% of the children with CSP. As against this, Akiyama et al found an incidence of 22.5% of epilepsy in their series<sup>9</sup>, while Grahmann and Peters found epilepsy in up to 55% of their compiled cases as observed by Bruyn<sup>1</sup>. It is not clear why epilepsy was seen so commonly in the earlier series; however, since the diagnosis of CSP was earlier based on pneumo encephalography, it may be argued that some of the cerebral malformations predisposing to epilepsy were missed which would have been diagnosed on cranial CT scans or MRI in the later series. The cause of epilepsy in the present series is not clear; MRI was not done on these children to rule out conditions such as associated neuronal migration disorders although detailed neurometabolic work failed to reveal any metabolic causes. Bruyn postulated that increased incidence of epilepsy and psychosis in patients with epilepsy was due to the disruption of a circuit connecting SP-fornix-cingulate-hippocampal region by a cystic dilatation of SP<sup>1</sup>. Abnormalities of SP could then be expected to cause symptoms such as disturbance in emotions and behavioural functions of the limbic system. Akinetic mutism has been reported in association with a cystic

CSP. Two patients in the present series had psychotic manifestations unrelated to increased intracranial tension.

Amongst the neurological disorders that have been linked with CSP, hydrocephalus is considered by many as the single most important association<sup>3,8,9-11</sup>. A cystic dilatation of CSP appears to cause intermittent or progressive obstruction to the foramina of Munro resulting in ventricular dilatation in some cases<sup>9</sup> although in the others, CSP may be the result of obstructive hydrocephalus. The cavum is not primarily a part of the cerebral ventricular system although communications between the two may exist; the non-communicating CSP does contain cerebro spinal fluid, which filters through the septal laminae and is reabsorbed through the capillaries and veins of the septum. In the present series 8 (14.8%) cases had significant hydrocephalus secondary to obstruction to the ventricular system, either congenital or acquired following intra ventricular bleeds (Fig 2). The dilated CSP in these cases could be due to CSF seeping in from the dilated ventricles under high pressure.



**Fig 2.** Cranial CT scan showing cavum septum pellucidum with ventricular dilatation



**Fig 3. Cranial CT scan showing cavum septum pellucidum with cortical atrophy.**

An association between cranio cerebral trauma and CSP has been documented; there seems to be a high incidence of CSP among professional boxers<sup>1,7,12,13</sup>. It has been postulated that CSP in the boxers is due to repeated head trauma resulting in bleeds between the

lamellae eventually resulting in the formation of a cavity<sup>13</sup>. Clinically this may lead on to the condition of 'boxers' encephalopathy'. In our series, 5 patients with head injury had CSP in addition to the presence of cerebral contusion and/or bleeding. It is difficult to say whether the CSP was the result of head injury or was a co-incident anomaly present since birth in these cases.

In the present study, the high degree of coexistence of cortical atrophy (Fig 3) is noteworthy. There have been no reports of such an association in the literature. A possible explanation is that in patients with cortical atrophy the potential space of CSP expands along with the ventricles as in 'hydrocephalus ex-vacuo'. Overall additional CT abnormalities were seen in 48 of 54 patients with CSP (88.8%) (Table 3).

In conclusion, the patients with CSP in this study were found to have hydrocephalus, epilepsy, mental retardation, head injury, cerebral haemorrhage and psychosis as the most common clinical presentations. The links between the neurological disorders and the CSP remain unclear at present and await further study. The prevalence of CSP in the normal Malaysian population has not been studied; such a study would be difficult beyond infancy but if possible, would make the association between the neurological disorders and CSP clearer. It would be more useful to study and compare two groups of patients, one with CSP and the other without CSP.

## References

1. Bruyn GW. Agenesis septi pellucidi, cavum septi pellucidi, cavum Vergae and cavum veli interpositi. In: Vinken PJ, Bruyn GW (eds). Handbook of clinical neurology; Vol 30. Amsterdam: North Holland Publishers, 1977; 299-336.
2. Lewis SW, Mezey GC. Clinical correlates of septum pellucidum cavities: an unusual association with psychosis. *Psychol Med* 1985; 15(1): 43-54.
3. Lin K-L, Wang H-S, Chou M-L, Rui T-N. Role of cavum septum pellucidum in akinetic mutism of hydrocephalic children. *Paed Neuro* 1997; 16: 156-9.
4. Schaefer GB, Bodensteiner JB, Thompson JN. Subtle anomalies of the septum pellucidum and neurodevelopmental deficits. *Dev Med Child Neuro* 1994; 36: 554-9.

## ORIGINAL ARTICLE

5. Silbert PL, Gubbay SS, Vaughan RJ. Cavum septum pellucidum and obstructive hydrocephalus. *J Neuro Neurosurg Psych* 1993; 56: 820-2.
6. Mott SH, Bodensteiner JB, Allan WC. The cavum septi pellucidi in term and preterm newborn infants. *J Child Neuro* 1992; 7: 35-8.
7. Bogdanoff B, Natter HM. Incidence of cavum septum pellucidum in adults: a sign of Boxers' encephalopathy. *Neurol* 1989; 39: 991-2.
8. Gubbay SS, Vaughan R, Lekias JS. Intermittent hydrocephalus due to cysts of the septum pellucidum. *Clin and Exptl Neuro* 1978; 14: 93-6.
9. Akiyama K, Sato M, Sora I, Otsuki S, Waks A. A study of incidence and symptoms in 71 patients with cavum septi pellucidi. *No To Shinkei* 1983; 35(6): 575-81.
10. Amin BH. Symptomatic cyst of the septum pellucidum. *Child Nerv Syst* 1986; 2 (6): 320-2.
11. Heiskanen O. Cyst of the septum pellucidum causing increased intra cranial pressure and hydrocephalus. *J Neurosurg* 1973; 38: 771-3.
12. Casson IR, Seigel O, Sham R, Campbell EA, Tarlay M, DiDomenico A. Brain damage in modern boxers. *J Am Med Assn* 1984; 251: 2663-7.
13. Lamper PW, Hardman JM. Morphological changes in brains of boxers. *J Am Med Assn* 1984; 251: 2676-9.