

# Penetrating Cardiac Injury without Tamponade

T Aung, FRCS, Hospital Tawau, Sabah

## Summary

A case of unsuspected penetrating cardiac injury is presented. It was recognised by the presence of bleeding into peritoneal cavity even after the source of bleeding from intra-abdominal organs had been stopped. It highlights the importance of high index of suspicion of associated cardiac injury in high epigastric penetrating injury.

Key Words: Cardiac injury

## Case Report

A 30-year-old Bugis male was admitted to Hospital Tawau, Sabah for a stab wound in his upper abdomen on at 10:30 p.m. He had been stabbed at about 8:30 p.m with a knife. He was alert and not obviously pale. The stab wound was 2cm x 1cm, 3cm to the left of his mid-line and 4cm below the costal margin with omentum protruding. Blood pressure recorded then was 90/50 and his pulse rate was 96/min. A chest X-ray. was unremarkable and his Hb was 18.4g/dl. His white cell count, serum electrolytes and blood sugar were within normal limits. Preoperatively his blood pressure dropped to 80/0 and his pulse rate rose to 120/min and he was resuscitated with 1 unit of blood and 1.5 litres of crystalloids.

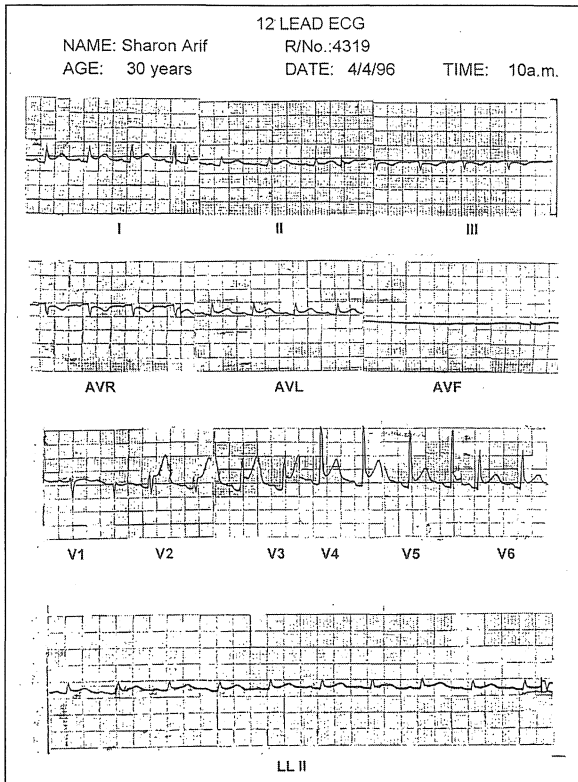
Laparotomy through an upper mid—line incision began at 12:45a.m. Protruding omentum was excised. About 2L of haemoperitoneum was noted. The source of bleeding was a 5cm x 1cm x 3cm puncture wound on the anterior surface of the left lobe of his liver. It was sutured with 2/0 Vicryl and peritoneal lavage was performed. However fresh bleeding around the left lobe of his liver continued. All abdominal organs were inspected and palpated and found to be normal. Pressure on the left lobe of liver posteriorly produced a pulsatile jet of blood from the left leaf of the central tendon of his diaphragm. To get better access the incision was extended upwards and the xiphoid process

was removed. A 1cm diameter diaphragmatic opening was found and it was enlarged by cutting on both sides by 1 cm. A 2mm pulsatile jet of blood shot out from the diaphragmatic surface of the heart near the termination of the posterior inter-ventricular branch of the right coronary artery on the left ventricle. The wound was sutured with 2/0 Vicryl taking care not to include any vessel. A marked bradycardia and irregularity in cardiac rhythm occurred whenever the heart was touched by fingers or instrument. After washing the pericardial cavity with normal saline, a tube drain was inserted through the 5th intercostal space close to the left sternal margin. The diaphragmatic opening was closed with 2/0 Vicryl. A tube drain was inserted into the under-surface of the left lobe of the liver. The abdominal wall wound was excised and sutured layer by layer. The abdominal incision then was closed in layers. The operation was completed at 4:45am.

Post-operatively he was comfortable and stable. ST segment elevation on the ECG persisted for 3 days but disappeared spontaneously (Fig.1). Cardiac enzymes on the 3rd postoperative day were creatine phosphokinase =152u/l, lactic dehydrogenase =287u/l, serum aspartate aminotransferase =42u/l. The abdominal drain was removed on the same day. The pericardial drainage was 26ml on the 1st day, 5-10ml on subsequent days and the drain was removed on the 6th day. He was discharged on the 9th day.

## CASE REPORTS

Reviewed 2 weeks later his cardiovascular status was stable and his wound healed.



**Fig. 1:** ECG showing ST segment elevation on postoperative day 1.

### Discussion

Identification of the instrument that caused the injury is very important in assessing the nature, extent and depth of the wound. Unfortunately the knife in our case was not retrieved. However judging from the size of the abdominal, hepatic, diaphragmatic and cardiac wounds, the knife used was most likely to be a hunting knife, also called Bugis knife in Sabah. Hunting knives are usually 6 inches long. Traditionally laparotomy was mandatory for patients with omental or bowel evisceration regardless of the presence or absence of abdominal signs. But the study by McFarlane<sup>1</sup> in 1996 had shown that the principle of 'selective conservatism'

with serial clinical examination could be applied to cases with omental evisceration provided there are no signs of generalized peritonitis, haemodynamic instability, haemetemesis, haematochezia, or bowel evisceration, singly or in combination. As our case had protruding omentum and was haemodynamically unstable, laparotomy was planned with the presumption that some intra-abdominal organs along the path of the knife namely left lobe of liver and / or stomach could have been injured with profuse bleeding.

Few clinicians would consider the possible injury to the heart in the case of a penetrating abdominal wound especially if there is no sign of cardiac tamponade. This case highlights the need for a high degree of vigilance during trauma surgery where the unexpected may be found. It demonstrates the importance of accounting for every source of bleeding. Our case highlights the importance of high index of suspicion of associated cardiac injury in high epigastric penetrating injury<sup>2</sup>. In such cases a cardiac tamponade may not occur because a puncture of the central tendon of the diaphragm allows blood to escape from the pericardium.

The temporary nature of the post-operative ST segment elevation implied that there was an episode of ischaemia which could be attributed to the episode of pre-operative hypotension and spasm of coronary vessels. The raised cardiac enzymes were due to the injuries to the cardiac muscle cells by the knife and the sutures inserted by the surgeon. The decreasing pericardial drainage implied that there was no recurrent bleeding into the pericardial cavity and the myocardial and the pericardial injuries were healing.

### Acknowledgements

I wish to thank the Director-General of Health for his kind permission to publish this paper. I also wish to thank all doctors and staffs who helped me to manage this case to a successful outcome and Mr Abdullah Haron FRCS, Consultant Cardiothoracic Surgeon of National Heart Institute for his kind advice and help.

**References**

1. McFarlane MEC. Non-operative management of stab wounds to the abdomen with omental evisceration. *J R Coll Surg Edinb*, 1996;41 : 2396-240.
2. Saadia R, Levy RD, Degiannis E, Velmahos GC. Penetrating cardiac injury: clinical classification and management strategy. *Br J Surg* 1994;81 : 1572.