

# Endotracheal Tube Ignition During CO<sub>2</sub> Laser Surgery of the Larynx

C L Chiu, FRCA\*, V Khanijow, FRCS\*\*, G Ong, FANZCA\*, A E Delilkan, FRCA\*, \*Department of Anaesthesiology, \*\*Department of Otolaryngology, Faculty of Medicine, University of Malaya, 50603 Kuala Lumpur

## Summary

We report a case of endotracheal tube fire occurring during CO<sub>2</sub> laser surgery of the larynx. The ignition of an endotracheal tube was thought to be caused by laser penetration of an unprotected portion of the tube during resection of vocal cord tumour. Fire hazard is inevitable when a laser is used in the path of combustible gases and in the presence of flammable objects. We discuss the methods of prevention that were used.

**Key Words:** Laser surgery, Larynx, Endotracheal tube fire

## Introduction

The use of CO<sub>2</sub> laser for laryngeal surgery has many benefits, such as its precision, control and hemostatic properties. However, the hazards of fire and tracheal burns during laser microsurgery are well recognised. Most of the reported and potential complications result from the laser beam or its reflection inadvertently falling on areas that are not intended to be exposed. It has been reported that flaming tissue in close proximity to the tube may ignite it<sup>1</sup>. We are reporting a case of endotracheal tube fire occurring during CO<sub>2</sub> laser surgery. The ignition was thought to be caused by the laser beam falling on an unprotected portion of the tube.

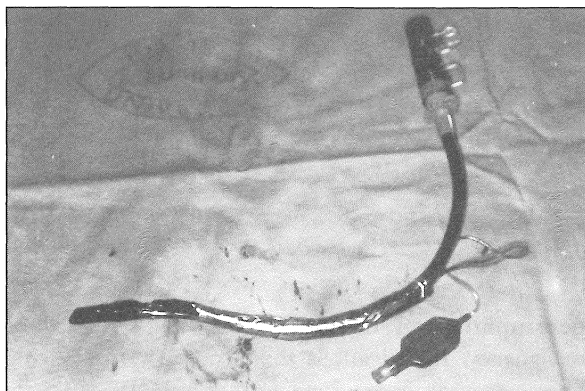
## Case Report

A 75-year-old 65 kg man presented with a 2-year history of hoarseness. He was diagnosed to have carcinoma of the larynx. He received radiotherapy treatment for his laryngeal tumour. However, on follow up, a recurrence was detected and he was scheduled for laser surgery. Preoperative assessment was unremarkable and routine investigations were within normal limits. The patient was premedicated with 7.5

mg of midazolam orally. After preoxygenation, anaesthesia was induced with 225 mg of thiopentone, 100 µg of fentanyl and 100 mg of suxamethonium. Laryngoscopy was performed and the trachea was intubated with a 7.5 mm laser shield Xomed endotracheal tube via the nasal route. General anaesthesia was maintained with 33% of oxygen in nitrous oxide, enflurane and vecuronium. Electrocardiography (ECG), non invasive blood pressure (NIBP), peripheral oxygen saturation (SpO<sub>2</sub>), and end tidal carbon dioxide (E<sub>t</sub>CO<sub>2</sub>) were continuously monitored throughout the operation.

Microdirect laryngoscopy by the surgeon revealed a proliferative growth on the surface and undersurface of the vocal cords. However, the cuff of the endotracheal tube was thought to be partially obscuring part of the tumour at the undersurface of the vocal cords. After unsuccessful attempts to adjust the cuff, the Xomed endotracheal tube was withdrawn. A disposable PVC endotracheal tube wrapped with adhesive aluminium foil tape to the proximal end of the cuff was used to intubate the patient. The cuff was thought to be sufficiently away from the tumour. Three biopsies were taken from the left vocal cord. Before laserization of the vocal cords started, nitrous oxide was replaced by air, the right vocal cord and

laryngeal inlet were covered with wet gauze. About 30 minutes after the surgery started, the surgeon proceeded to laserize the tumour on the vocal cord. Suddenly black smoke arose from the endotracheal tube, the hoses from the anaesthesia machine were immediately disconnected and the charred endotracheal tube removed. (Fig. 1). The trachea was reintubated with a new PVC tube. 100% oxygen was administered. Vital signs were stable. An examination of the airway revealed charred epiglottis and vocal cords.



**Fig. 1: Vinyl plastic endotracheal tube removed from patient**

The patient was transferred to ICU. Dexamethasone and a broad spectrum antibiotic was given. He required ventilation for four days. At weaning, an elective tracheostomy was performed and he was discharged to the ENT ward where he continued to recover uneventfully. Symptoms subsided over the next 3 weeks. The patient was able to eat solids after 12 days. Fiberoptic laryngoscopy revealed good healing and adequate airway. There was no evidence of tumour residue in the larynx. The patient continues to be on regular follow up. At the last visit, almost a year after the incident, the patient is asymptomatic and tumour free. The only abnormality noted is a distorted

epiglottis with slight restriction of arytenoid movement on the left side.

### Discussion

The wavelength of the CO<sub>2</sub> laser beam is in the infrared range (10.6 microns). The heat produced may ignite anaesthetic equipment, such as endotracheal tubes, producing airway burn. Protection of the endotracheal tube by aluminium foil tape has been suggested, so that the laser beam is reflected and the energy dissipated. However, balloon rupture due to laser penetration was reported in 4 of 392 laser surgical procedures<sup>2</sup> and endotracheal tube fire occurred in 4 of 700 laser operation<sup>3</sup>. In each instance, a red rubber tube was either not wrapped with aluminium foil tape or was wrapped so that a portion of the tube became exposed to the laser beam. It was thought that red rubber tube is less vulnerable to laser penetration. However, this purported advantage is not well documented. Instead, Hirshmann *et al* suggested that red rubber tube is more easily ignited<sup>1</sup>. So far no nonflammable plastic material that could be used for the fabrication of endotracheal tubes has been identified. In conclusion, if a metal flexible tube or bronchoscope cannot be used, we strongly recommend meticulous care in protecting the tube from an inadvertent laser impaction. An absolutely clear field of operation must be maintained to employ the laser safely. The red rubber tube should be protected by self adhesive aluminium tape if it is in the target area and the balloon should be shielded by a cottonoid that is kept moist at all times. Orotracheal intubation is preferred because nasotracheal intubation can cause dislodgement of the aluminium foil wrapping. The lowest possible oxygen concentration tolerated by the patient should be employed while monitoring patient's oxygen saturation. Close coordination and communication between the surgeon and the anaesthesiologist is necessary.

### References

1. Hirshman CA, Smith J. Indirect ignition of the endotracheal tube during carbon dioxide laser surgery. *Arch Otolaryngol* 1980;106 : 639-40.
2. Snow JC, Kripke BJ, String MS *et al*. Anaesthesia for carbon dioxide laser microsurgery on the larynx and trachea. *Anaesth Analg* 1974;53 : 507-12.
3. Snow JC, Norton ML, Saliya TS *et al*. Fire hazard during CO<sub>2</sub> laser microsurgery on the larynx and trachea. *Anaesth Analg* 1976;55 : 146-7.