

## References

1. Yamanaka A, Saeki S, Tamura S, Saito K. The problems of chronic obstructive pulmonary disease: especially concerning about diffuse panbronchiolitis. *Intern Med* 1969;23 : 442-51.
2. Akira M, Kitatani F, Lee YS, *et al.* Diffuse panbronchiolitis: Evaluation with high resolution CT. *Radiology* 1988;168 : 433-8.
3. Nagai H, Shishido H, Yoneda R, Yagamuchi E, Tamura A, Kurashima A. Long term low dose administration of erythromycin to patients with diffuse panbronchiolitis. *Respiration* 1991;58 : 145-9.

# Glibenclamide Induced Chronic Cholestasis Simulating Primary Biliary Cirrhosis : A Case Report

M Ramanathan, MRCP\*, S Wahinuddin, MBBS\*, S T Kew, FRCP\*\*, \* Department of Medicine, Taiping Hospital, 34000 Taiping, Perak, \*\* Department of Medicine, Kuala Lumpur Hospital, 53000 Kuala Lumpur

## Summary

A 43-year-old lady with long standing non-insulin dependent diabetes mellitus on glibenclamide presented with cholestatic liver disease. Initially she was thought to have developed primary biliary cirrhosis (PBC). When she made a spontaneous recovery following the withdrawal of glibenclamide, it became obvious that the patient had been suffering from drug-induced chronic cholestasis (DICC). The subtle differences between PBC and DICC are highlighted.

**Key Words:** Vanishing bile duct syndrome, Drug-induced chronic cholestasis, Pseudo-primary biliary cirrhosis sulphonylureas

## Introduction

Glibenclamide is commonly used in the treatment of non-insulin dependent diabetes mellitus (NIDDM). Its well known side effects are rash and hypoglycaemia. We describe a patient in whom the sulphonylurea caused chronic cholestasis mimicking primary biliary cirrhosis.

## Case Report

A 43-year-old Chinese lady was diagnosed as non-

insulin dependent diabetes mellitus (NIDDM) since 1986 and was controlled with glibenclamide 10 mg twice a day. She was well till September 1991 when she was admitted to the hospital with a four-day history of generalised itching and yellow discoloration of eyes.

Physical examination revealed a markedly jaundiced patient with excoriation marks all over her body. The

examination of other systems was normal. Liver was not palpable.

Laboratory evaluations on admission including haemoglobin, total white cells count, random blood sugar, blood urea and serum electrolytes were normal. The erythrocyte sedimentation rate (ESR) was 150 mm/1st hour.

The liver function tests (LFT) on admission showed total serum bilirubin 107  $\mu\text{mol/L}$ , total serum protein 88 g/L, albumin 37 g/L, globulin 51 g/L and serum alkaline phosphatase 285 U/L. The serum aspartate transaminase (AST) was 104 U/L and the alanine transaminase (ALT) was 242 U/L. The prothrombin time was normal. The hepatitis B surface antigen was negative.

An ultrasound examination of the hepatobiliary system revealed that the liver parenchyma was less echogenic than usual. No dilated intrahepatic ducts were seen. Gallbladder appeared contracted although the patient was fasting. No obvious gallstone was seen. These features were consistent with "hepatitis".

The patient's treatment for NIDDM was continued with glibenclamide. Her blood sugars remained within acceptable limits in the ward. Her pruritus remained refractory to treatment including antihistamines steroids and cholestyramine. She lost 4 kg over the next three weeks. She also developed a dark complexion due to generalised hyperpigmentation (melanoderma).

A liver biopsy performed under ultrasound guidance was reported as showing "1. Very few bile ducts and some oedema in the portal tract. No inflammatory cells seen in the portal tract. 2. No features of cirrhosis. 3. Bile plugs seen. 4. Liver cells appear quite healthy". The pathologist's impression was that of a "Disappearing duct syndrome".

Meanwhile, the patient's general condition deteriorated. She was very depressed and anxious due to intractable pruritus and deepening melanoderma. She became overtly cachexic with further loss of 12 kg over the next four weeks.

The following serologic tests were negative: hepatitis B surface antigen (Hbs Ag), antihepatitis B core

antibody (Hbc Ab), antibody to hepatitis C (HCV) and human immunodeficiency virus antibody (HIV Ab). The antinuclear factor (ANF) (speckled) and antimitochondrial antibody were weakly positive. The antismooth muscle antibody was negative.

The fasting serum lipid profile showed markedly raised levels of cholesterol and triglycerides at 10.7 mmol/l and 7.4 mmol/l respectively. The serum caeruloplasmin was mildly raised at 0.9 g/L (Normal: 0.15 to 0.6 g/L).

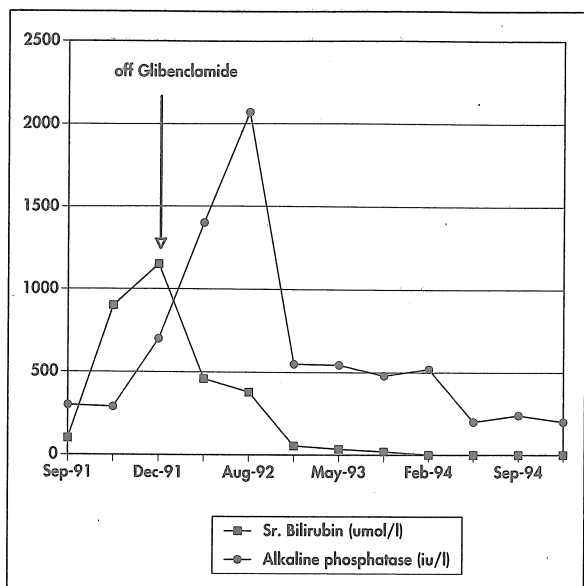
The serum iron, total iron binding capacity (TIBC), alpha foetoprotein and immunoglobulin electrophoresis were normal. An upper endoscopic examination (OGDS), computerised axial tomographic scan (CT scan) of the abdomen and an endoscopic retrograde cholangiopancreatographic (ERCP) studies were all normal.

The serum transaminases remained at the upper limits of normal levels and fluctuated within a relatively narrow range. Serum albumin and globulin levels did not vary much from the values obtained on admission. However, the serum bilirubin and alkaline phosphatase levels kept rising rapidly. The serum bilirubin reached its peak value of 1166  $\mu\text{mol/L}$  during the eighth week of admission while the alkaline phosphatase level raised to the maximum value of 2068 U/L eleven months after presentation (Fig. 1).

Her diabetes control deteriorated, probably due to the steroids she was on. Thus, glibenclamide was stopped about three months after her initial presentation and treatment was switched to insulin. The patient was discharged home after 20 weeks of hospitalisation with a guarded prognosis.

At review one month later, she reported that she had stopped all her medications except for insulin. She felt much better with remarkable improvement in her pruritus. Although she was still jaundiced, there appeared to be some regression of her melanoderma. She had also gained 4 kg.

Repeat liver function test showed a significant drop in her bilirubin level but the alkaline phosphatase still showed an upward trend (Fig. 1).



**Fig. 1: Progress of serum bilirubin and alkaline phosphatase in relation to glibenclamide**

The patient was followed up on a regular basis over the following three years. Her symptoms, jaundice and melanoderma resolved completely about eighteen months after initial presentation. The LFT and the lipid profile too normalised over the next two years. A repeat liver biopsy done two and a half years later was normal. She remains well three years later.

**Discussion**

On admission the patient was thought to be going through a cholestatic phase of viral hepatitis. But when she did not respond to symptomatic treatment, it was felt necessary to look for an alternative explanation for her malady.

The presenting symptom of intractable pruritus in association with progressive melanoderma and jaundice suggested a cholestatic liver disease. The markedly raised alkaline phosphatase levels, near normal aminotransferases, and positive antimitochondrial antibody, mildly raised serum caeruloplasmin level and the abnormal lipid profile were compatible with diagnosis of primary biliary cirrhosis (PBC). The patient's age and sex too favoured PBC. These findings

were supported by liver biopsy. The absence of cirrhotic changes in the liver biopsy did not deter us from making diagnosis of PBC as these changes are a late phenomenon in PBC. Moreover cirrhotic changes could have been easily missed on a small needle biopsy specimen as the lesions may be spotty<sup>1</sup>.

Thus the patient was discharged home with confident diagnosis of PBC. On subsequent follow ups, the patient was expected to go downhill with the known complications of PBC. It has been pointed out that once pruritus and jaundice had occurred in patients with PBC, it is unusual for them to disappear spontaneously<sup>1</sup>.

The patient's spontaneous recovery forced us to review our earlier diagnosis of PBC in her.

Besides PBC, the syndrome of 'vanishing bile duct' has been associated with primary sclerosing cholangitis (PSC)<sup>2</sup>, graft-versus-host disease (GHD)<sup>2</sup>, cytomegalovirus infection (CMV) in an immunocompromised patient<sup>2</sup> and drugs<sup>3</sup>. The normal ERCP examination virtually excluded PSC. The question of GHD and CMV infection did not arise in this patient. Thus the two main contestants for the disappearance of intrahepatic bile ducts in this patient were PBC and drug.

PBC and drug-induced chronic cholestasis (DICC) can resemble each other very closely. In retrospect, there were a few pointers in this patient which were more consistent with DICC than PBC: the presence of marked jaundice and very high bilirubin levels at presentation were more compatible with DICC than PBC in which jaundice is usually mild<sup>3</sup>. The weakly positive antimitochondrial antibody is also seen in DICC<sup>1</sup>. The excellent outcome of this patient also suggested DICC than PBC because the bile ducts do not regenerate spontaneously in PBC<sup>2</sup>.

The only drug that could have caused DICC in this patient was glibenclamide. The amelioration of symptoms following the withdrawal of glibenclamide and the regeneration of bile duct on repeat liver biopsy confirmed our impression that the ductopaenia seen in this patient was due to glibenclamide.

Amongst sulphonylureas, tolbutamide had been reported

to have caused the 'vanishing duct syndrome'<sup>3</sup>. But reports implicating glibenclamide as a cause of DICC or what has been aptly termed 'pseudo-primary biliary cirrhosis'<sup>3</sup>, appear to be rare. Our literature search found one earlier report in the English literature concerning a 66-year-old woman who developed severe cholestatic hepatitis, eight months after having been on glibenclamide 7.5 mg/day. Unlike our patient, she recovered very rapidly within eight weeks of drug withdrawal<sup>4</sup>.

### Acknowledgement

The authors wish to thank the Director-General of Health Services, Malaysia for his kind permission to publish this paper, Dr. Han Seong, of Singapore General Hospital for his excellent interpretation of the patient's liver biopsy slides and Puan Zorah Aziz, Secretary, National Adverse Drug Reactions Advisory Committee for her kind assistance in literature search.

### References

1. Kaplan MM. Primary biliary cirrhosis. *N Engl J Med* 1987;316 : 521-8.
2. Sherlock S. The syndrome of disappearing intrahepatic bile ducts. *Lancet*. 1987;ii : 933-6.
3. Zimmerman HJ. Hepatotoxicity. *Dis Mon* 1993;39 : 715-21.
4. Lambert M, Geubel A, Rahier J, Branquinho F. Cholestatic hepatitis associated with glibenclamide therapy. *Eur J Gastroenterol Hepatol* 1990;2 : 389-91.

## Road Traffic Accidents in Patients with Obstructive Sleep Apnoea

C K Liam, MRCP, L G How, MBBS, C T Tan, FRCP, Department of Medicine, Faculty of Medicine, University of Malaya, 59100 Kuala Lumpur

### Summary

Three patients involved in road traffic accidents were suspected to have obstructive sleep apnoea (OSA). Two of them fell asleep while riding motorcycles and one patient fell asleep behind the wheel of a truck causing it to overturn. The diagnosis of OSA in each case was suspected based on a history of loud snoring, restless sleep, and excessive daytime somnolence and was confirmed by sleep studies.

*Key Words:* Road traffic accidents, Obstructive sleep apnoea

### Introduction

Excessive daytime sleepiness, one of the main symptoms of obstructive sleep apnoea (OSA) syndrome,<sup>1</sup> can lead to real dozing off especially in monotonous situations, such as driving. Studies have

shown that patients with OSA have a high rate of automobile accident<sup>2,3</sup>. We report three cases to illustrate this fact. Recognising and effectively treating these impaired drivers may prevent potentially serious injury to themselves and other road users.