

Video-Assisted Thoracoscopic Surgery for Pneumothorax

Y M Lee, FRCS*

Y C Lim, FRCS*

C K Liam, MRCP**

M Aljafri, FRCSTH*

* *Cardiothoracic Unit, Department of Surgery*

** *Department of Medicine,*

University of Malaya, Lembah Pantai, 59100 Kuala Lumpur

Summary

Five cases of spontaneous pneumothorax were treated with video-assisted thoracoscopic surgery (VATS). These included four cases of recurrent pneumothorax and one case of persistent pneumothorax. The mean age was 33 years. The identified bullae were eliminated with either endoloop ligation (in one patient) or stapled excision (in four patients). There were no recurrences reported in a mean follow-up of 9.4 months. In conclusion, VATS offers an equally effective and less morbid alternative to open thoracotomy in the management of primary spontaneous pneumothorax.

Key Words: Spontaneous pneumothorax, Video-assisted thoracoscopic surgery

Introduction

Spontaneous pneumothorax is a common condition with an estimated annual incidence of 7.9/100,000 population¹. However, the diversity of treatments available for this common condition suggests that the optimal treatment remains debatable. The goal of all forms of treatment is well defined, i.e., removal of air from the pleural cavity, prompt re-expansion of the lung and prevention of further recurrence. The advances and miniaturisation made in the chip technology in the past decades have resulted in the improvement of endoscopic instrumentation and video imaging. Together with the availability of the recently developed endoscopic instruments, video-assisted thoracoscopic surgery (VATS) provides a new approach to diagnosis and treatment of pneumothorax²⁻⁵ with reduced postoperative pain, hospitalization, recovery time and low recurrence rate in the short to medium term follow-up. This paper reports an early experience with VATS for spontaneous pneumothorax at the University Hospital, Kuala Lumpur.

Materials and Methods

Five patients with primary spontaneous pneumothorax underwent VATS between November 1993 and July 1994 (Table I). The mean age was 33 years with a range of 20 to 71. All the patients were male with three diagnosed to have ipsilateral recurrence twice prior to surgery, one patient with four previous ipsilateral recurrences and the fifth patient with persistent spontaneous pneumothorax despite of one week of conservative treatment with intrapleural chest-tube drainage. Informed consents including the explanation of nature of surgery and the possibility of failure of VATS and the necessity for subsequent thoracotomy were obtained from the patients. Preoperative investigations included full blood count, blood urea and serum electrolytes and creatinine, plain X-ray of the chest and lung function tests. All procedures were performed under general anaesthesia with double lumen endotracheal tube in order to allow one-lung ventilation during surgery. Pulse oximetry was added to routine monitoring for general anaesthesia.

Table I
Details of 5 patients undergone VATS

Patient	Age (yr)	Sex	Side	Cause	Follow-up (months)
1	20	M	Right	Recurrent (x4)	12
2	71	M	Left	Persistent	10
3	29	M	Right	Recurrent (x2)	9
4	21	M	Right	Recurrent (x2)	8
5	25	M	Right	Recurrent (x2)	8

All patients were positioned, prepared and draped in the lateral decubitus position with the operating table flexed at 30° in the middle to open up the intercostal spaces. Upon positioning, ventilation to the lung of the operative side was stopped before the insertion of the thoracoscope. This is aimed to minimise the risk of traumatic injury to the lung by the thoracoscope. Prophylactic antibiotic (cefuroxime 750 mg, intravenously) was given at induction.

Video equipment consisted of an Olympus 10 mm straight viewing rigid telescope (Olympus Singapore Ltd, Singapore) with an attached auto exposure camera and light source (Olympus camera connector and power source – Olympus Singapore Ltd, Singapore). The camera was wired to a video cassette recorder to allow recording when required and a medical grade video monitor. The latter was positioned opposite the surgeon for viewing. The lens of the thoracoscope was coated in an antifog solution before it was inserted into the chest.

Three stab-incisions of length 10-20 mm were then made on the chest wall (Fig. 1). The first was usually made on the mid-axillary line one to two finger breath below the inferior angle of the scapula. This was followed by blunt widening of the incision into the pleural space with a haemostat forcep. A blunt end trocar with a 12mm-port was then inserted and through the latter the thoracoscope was introduced for viewing and inspection of the interior. Subsequent stab-incisions and insertions of trocars and ports were made one to two intercostal spaces above the first site along the anterior and posterior axillary lines under direct vision of the thoracoscopic imaging in order to avoid

injury to the lung. We avoided using port of size greater than 12 mm in order to minimise the theoretical risk of the pressure related intercostal neuritis.

Adhesions or fibrous bands seen at the thoracoscopic imaging were divided with diathermy in order to allow normal re-expansion of the lung subsequently. Bullae or scarring areas identified were eliminated with either endoloop ligation (in one patient) or stapled excision with Multifire EndoGIA30™ (Auto Suture, USA) (in

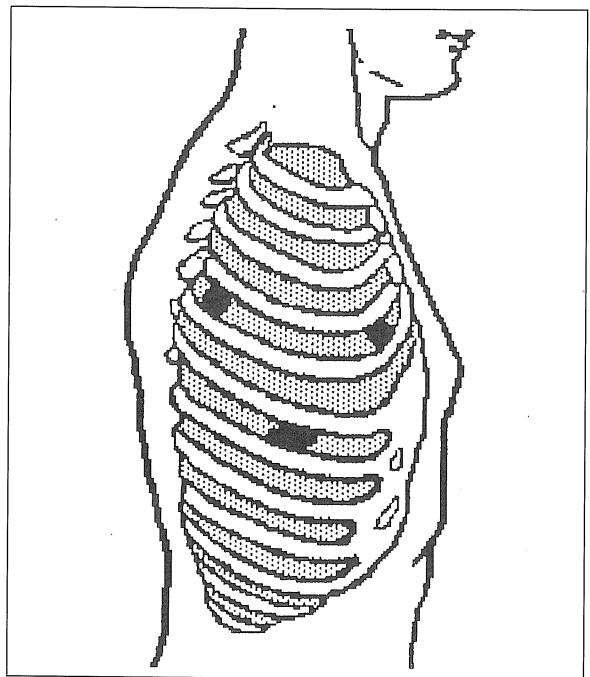


Fig. 1. Approximate sites of routine placement of cannulas

four patients). Pleurodesis was then performed with either tetracycline (in one case) or pleural abrasion (in the rest of the four cases). At the completion of the procedure, the lung of the operative side was reinflated under direct vision of the thoracoscopic imaging. A single intercostal chest-tube was placed at the apex of the hemithorax and the incisions were infiltrated with 0.5% bupivacaine before it was closed with non-absorbable interrupted sutures.

Results

There were no mortality and no intraoperative complications reported. The mean operating time was 35 minutes. The mean duration of chest tube requirement following surgery was 6 days and the hospital stay was 9.4 days after VATS. Apart from paracetamol and tramadol, no patient was given any opiate after VATS. There were no recurrences reported on a mean follow-up of 9.4 months.

Discussion

Primary spontaneous pneumothorax (PSP) is defined as pneumothorax that occurs without previously known

underlying lung disease⁶. It is potentially fatal if left untreated. The goals of treatment are to rapidly and fully reexpand the lung, restore pulmonary function, and prevent recurrence of pneumothorax. A treatment that results in a short hospital stay, has few complications, and has minimal postoperative pain is desired. Conservative management of PSP has been shown to result in significant recurrence⁷. Surgical interventions on the other hand are associated with low recurrence and the available options are well discussed⁸. Indications for surgical intervention are recurrent pneumothorax, prolonged bronchopleural fistula, and failure to reexpand the lung with intrapleural chest tube drainage. Stapled resection of apical blebs, combined with pleural abrasion or apical pleurectomy through axillary or lateral thoracotomy, has a demonstrated recurrence rate of 0 to 3%^{7,9,10,11,12}.

Recently, VATS is suggested by as a probable procedure for PSP²⁻⁵. The early results with VATS in the management of spontaneous pneumothorax have been encouraging. Hospital stay has been short and postoperative pain minimal. Complications are few, and the cosmetic results of the three small trocar sites used for this technique compare favourably with the scar

Table II
Summary of recent series on treatment of primary pneumothorax with VATS

Authors	Nathanson, <i>et al.</i> (1991) ²	Melvin, <i>et al.</i> (1992) ³	Hazelrigg, <i>et al.</i> (1993) ⁴	Yim, <i>et al.</i> (1994) ⁵
- No. of patients	2	6	26	32
- Age, mean (yrs)	(46 yrs & 20 yrs)	23.8	32.3	No data (range 16-42 yrs)
- Indications	Recurrent-2	Recurrent-5 Persistent-1	Recurrent-19 Persistent-6 Persistent haemothorax-1	Recurrent-13 Persistent-4 Tension-2 Bilateral-2 Frequent traveller-11
Procedure	Bulla ligation & partial pleurectomy	Stapled resection & pleurectomy by electrocautery ± chemical pleurodesis by tetracycline	Stapled resection	Endoloop-ligation-5 Stapled excision-11 Plural abrasion-32
- Chest tube duration (days)	No data	No data	2.0 days	2 (median)
- Hospital stay (days)	No data	3.3	2.88 ± 0.99	4 (median)
- F/U (months)	No data	No data	8 months-no recurrence	No data

of thoracotomy. However, the optimal intraoperative options of VATS are still unclear and some of these experiences are summarized in Table II. The general consensus is that the cause of the pneumothorax, i.e., bullae, must be identified and eliminated. The short-term result for bleb excision alone is excellent⁴. Bleb elimination can be achieved with endoloop suture², electrocautery¹³ or endostapler but there is no comparative study available to suggest any of these particular methods is more superior to the others. In addition, there are no data on when and how often the bleb or bulla will recur after excision. On the other hand, aiming to create pleurodesis alone without bleb excision has been associated with a high recurrence¹⁴.

Pleurodesis can be achieved by several options as summarized in Table III. There is no experience to suggest that any one method is superior to the others. Owing to the geometry of the chest wall, mechanical abrasion by VATS is probably less than ideal as there is always a strip of pleura in the lateral chest wall that can not be reached and abraded. It is however cheap and easy to perform under the direct vision of thoracoscopic imaging. Instillation of chemical agents such as intrapleural tetracycline under direct vision with VAT is the alternative. We do not use talc powder in young patients in the believe that it is potentially carcinogenic. Laser pleurodesis¹⁵ has been reported but it is expensive to possess and maintain.

The mean duration of chest-tube requirement and hospital stay in this study were longer than the

Table III
Options in pleurodesis in the management of spontaneous pneumothorax

Types	Agents
Chemical	Silver nitrate Tetracycline Talc powder
Mechanical	Abrasion Apical pleurectomy Full pleurectomy
Laser Electrocautery ¹³	Nd: YAG laser ¹⁵

published papers. This probably and partly reflects our early experience of cautious approach than it would be otherwise. In addition, postoperative analgesic requirement is minimum as none of these patients required opiate analgesia. Although there were only five patients in this small study, the short and medium term results compare favourably with others, whether by thoracotomy or VATS, as there is no recurrence with a mean follow-up of 9.4 months.

Conclusion

When surgical intervention is indicated, VATS offers an equally effective and less morbid alternative to open thoracotomy in the management of primary spontaneous pneumothorax.

References

- Melton LJ, Hepper NGG, Offord KP. Incidence of spontaneous pneumothorax in Olmstead County, Minn., 1950-1974. *Am Rev Respir Dis* 1979;120 : 1379-82.
- Nathanson LK, Shimi SM, Wood RAB, *et al*. Videothoracoscopic ligation of bulla and pleurectomy for spontaneous pneumothorax. *Ann Thorac Surg* 1991;52 : 316-9.
- Melvin WS, Karsna MJ, McLaughlin JS. Thoracoscopic management of spontaneous pneumothorax. *Chest* 1992;102 : 1877-9.
- Hazelrigg SR, Landreneau RJ, Mack M, *et al*. Thoracoscopic stapled resection for spontaneous pneumothorax. *J Thorac Cardiovasc Surg* 1993;105 : 389-93.
- Yim APC, Ho JK, Chung SS, Ng DCY. Video-assisted thoracoscopic surgery for primary spontaneous pneumothorax. *Aust NZ J Surg*, 1994;64 : 667-70.
- DeMeester TR, La Fontaine E. The pleura. In: Sabiston DC, Spencer FC (eds). *Surgery of the Chest*. Philadelphia: WB Saunders, 1990 : 449-53.

ORIGINAL ARTICLE

7. O'Rourke JB, Yee ES. Civilian spontaneous pneumothorax. Treatment options and long term results. *Chest* 1989;96 : 1302-6.
8. Parry GW, Juniper ME, Dussek JE. Surgical intervention in spontaneous pneumothorax. *Resp Med* 1992;86 : 1-2.
9. Deslauriers J, Beaulieu M, Despres JP, Lemieux M, Leblanc J, Desmeules M. Transaxillary pleurectomy for treatment of spontaneous pneumothorax. *Ann Thorac Surg* 1980;30 : 569-74.
10. Youmans CR Jr, Williams RD, McMinn MR, Derrick JR. Surgical management of spontaneous pneumothorax by bled ligation and pleural sponge abrasion. *Am J Surg* 1970;120 : 644-8.
11. Weeden D, Smith GH. Surgical experience in the management of spontaneous pneumothorax, 1972-1982. *Thorax* 1983;38 : 737-43.
12. Singh SV. The surgical treatment of spontaneous pneumothorax by parietal pleurectomy. *Scand J Thorac Cardiovasc Surg* 1982;16 : 75-80.
13. Wakabayashi A. Thoracoscopic ablation of blebs in the treatment of recurrent or persistent spontaneous pneumothorax. *Ann Thorac Surg* 1989;48 : 651-3.
14. Olsen PS, Anderson HO. Long-term results after tetracycline pleurodesis in spontaneous pneumothorax. *Ann Thorac Surg* 1992;53 : 1015-7.
15. Torre M, Belloni P. Nd: YAG laser pleurodesis through thoracoscopy: New curative therapy in spontaneous pneumothorax. *Ann Thorac Surg* 1989;47 : 887-9.