

Dopa Responsive Dystonia with Diurnal Fluctuation (Segawa's Syndrome)

L C Ong, MRCP

S F Tang, MRCP

T R Moti Lal, MRCP

Department of Paediatrics, Faculty of Medicine, Universiti Kebangsaan Malaysia,
Jalan Raja Muda Abdul Aziz, 50300 Kuala Lumpur

Summary

A 10-year-old girl presented with progressive dystonia with diurnal fluctuation. Response to low dose L-Dopa was dramatic and sustained with no complications. Recurrence of symptoms was observed on attempted withdrawal. Because of the dramatic response to therapy, dopa-responsive dystonia must be considered in the differential diagnosis of disorders presenting as gait disorders in childhood.

Key Words: Childhood dystonia, Diurnal fluctuation, L-Dopa therapy, Segawa's syndrome

Introduction

Segawa¹, in Japan first reported a group of children with a progressive idiopathic dystonia and two striking clinical features – a marked diurnal fluctuation and a complete alleviation of symptoms with small doses of L-Dopa. With several similar cases reported since², variable symptomatology became more evident, and features such as lack of diurnal variation, later age of onset (including adolescence) and the occurrence of Parkinsonism have been reported. Nygaard *et al*² introduced the more general term “Dopa-responsive dystonia” (DRD), citing the key feature of Dopa-responsiveness, to minimise confusion with other disorders causing childhood onset dystonia or Parkinsonism.

We report a case of childhood onset dystonia, highlighting the problems of initial diagnosis, her progress and the remarkable response to L-Dopa.

Case Report

The patient, a 10-year-old Chinese girl, first presented with intermittent “tonic spasms” of both upper and lower limbs, associated with retrocollis and uprolling of eyes at the age of six. CAT scan and EEG done were normal. The perinatal history was uneventful. Her parents were non-consanguinous and five other siblings were normal.

There was no improvement with Carbamazepine. Six months later, she developed torticollis, equinovarus deformity of both feet and widebased, unsteady gait. There was hypertonicity and hyperreflexia (with unsustained clonus) of both lower limbs, but with good muscle power and normal plantar responses. She was thought to have sporadic spastic paraplegia. Over the years,

her gait and postural instability worsened, with scoliosis, rigidity and bradykinesia of her left arm resulting in frequent falls. There were no tremors at rest or during activation. Her academic performance remained above average. It had become evident that her symptoms were least in the morning and progressed through the day, with some benefit from an afternoon sleep. A screen for Wilson's disease was negative.

She was started on Sinemet 5/50 twice daily, resulting in dramatic improvement with complete remission of symptoms within a week. Immediate recurrence of symptoms occurred on attempted withdrawal of therapy, but promptly disappeared again on restarting medication. The patient has remained neurologically normal with normal gait and handwriting after two years of therapy, without any side effects or the need for an increase in drug dosage. There has been no "wearing off" of dose effect, tremors, "on off" phenomenon or "freezing episodes" to date to suggest Parkinsonism.

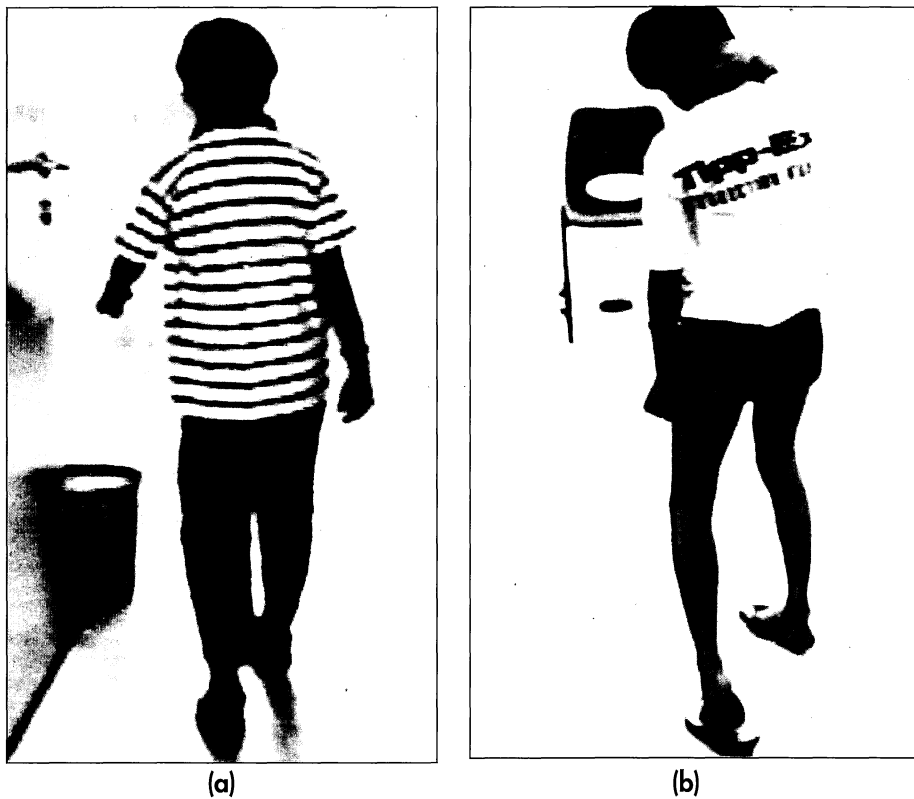


Fig. 1: Dopa-responsive dystonia with diurnal fluctuation

Discussion

Diminished central synthesis of dopamine is the presumed neurochemical deficit in DRD. Segawa¹ postulated a disturbance in sleep regulation of neurotransmitters related to L-Dopa metabolism to account for the diurnal fluctuation of symptoms and the benefits of sleep.

There is frequently a family history but the mode of inheritance is not clear, although autosomal dominant trait with incomplete penetrance and variable expressivity appear likely². Females appear to be more often affected. Although a significant proportion of cases have Japanese or Anglo-

CASE REPORT

Saxon heritage, a wide variety of other ethnic backgrounds including Indian and Chinese have been reported.

The major diagnostic alternative is idiopathic torsion dystonia (ITD), otherwise known as dystonia musculorum deformans. The region containing the gene loci for classic ITD is not linked to DRD³, suggesting that DRD constitutes a distinct subset of idiopathic dystonia in childhood. Although Segawa cited earlier age of onset, diurnal fluctuation, dystonia always starting in the lower extremities with minimal neck involvement as features that separated DRD from ITD, others have found broad overlap and the clinical picture can be indistinguishable. As in our patient, clinical elements suggesting spasticity gave cause for considering spastic paraplegia or diplegic cerebral palsy in some patients². Childhood onset Parkinsonism was a presumptive diagnosis in others, as 20 per cent of DRD had features of Parkinsonism at the onset of disease and 67 per cent at the time of starting treatment².

There was often a significant delay from symptom onset to first treatment with L-Dopa, the longest time reported being 58 years. Nevertheless, these patients showed an impressive response, which was sustained in some for as long as 10 to 22 years². The dramatic response and clinical stability suggests preserved Dopa-decarboxylase activity and dopamine turnover, unlike juvenile Parkinsonism, which may also have good initial response to low doses, but will eventually need increasing doses with time. Wearing off phenomenon with peak dose dyskinesia, generally occur within 1-5 years of treatment of juvenile Parkinsonism; an important but retrospective feature. The young age of onset of our patient, absence of rest tremors and absence of "wearing off" requiring increasingly higher doses of L-dopa even after two years of therapy suggests that she has DRD rather than juvenile Parkinsonism. Recent studies suggest PET may provide a means of differentiating the two earlier in the course of illness³.

Because of the dramatic and sustained response to L-Dopa, DRD must be considered in the differential diagnosis of the various disorders described which present with gait problems in childhood. Nygaard² suggested that a diagnostic therapeutic trial of L-Dopa should be considered in all children presenting with idiopathic dystonia or Parkinsonism. However, the definition of DRD must be modified to include at least five years of stable response to therapy, to avoid misclassification of early cases of childhood onset Parkinsonism.

Acknowledgement

We wish to thank Rouzana Taspin for her assistance in typing the manuscript.

References

1. M Segawa *et al.* Hereditary progressive dystonia with diurnal fluctuation. *Adv. Neurol.* 1976;14 : 215-33.
2. TG Nygaard. Dopa-responsive dystonia :20 years into the L-Dopa era. In: NP Quinn, PG Jenner eds. *Disorders of movement - clinical, pharmacological and physiological aspects.* London: Academic Press, 1989 : 323-37.
3. GV Sawk, KL Lunder, DJ Brooks, Marsden CD, Frackowiak RSJ. Dopa-responsive dystonia of juvenile onset: evidence of disease heterogeneity from 18F-fluorodopa studies (abstract). *Neurology* 1990;40 (suppl 1) : 144