

Cardiac Tumours in Children

S.P. Ram, MD

A.S. Malik, DTCH

Department of Paediatrics,

Hospital Universiti Sains Malaysia, 15990 Kubang Kerian, Kelantan.

Summary

Three children with cardiac tumors are described: a 12-year-old female child who had left atrial myxoma, and two males having rhabdomyoma of the right ventricle associated with tuberous sclerosis. The child with left atrial myxoma was symptomatic and the tumour was subsequently excised. The other two children with rhabdomyoma were managed conservatively.

Key words: Atrial myxoma, Rhabdomyosarcoma.

Introduction

Myxoma is a benign tumour of the heart¹. The exact incidence is not known. Seventy-five per cent of such tumors arise from the left side of the heart, more commonly on the left side of the inter atrial septum. The usual presentation of myxomas are obstruction to blood flow, embolisation and constitutional effects. Rhabdomyoma (RMA), the commonest benign tumour of infancy and childhood, is often associated with tuberous sclerosis (TS) and 80 per cent of RMA occur below the age of one year. RMA may be single or more commonly multiple.

We describe three children with cardiac tumours. Two of them had RMA of the right ventricle in association with TS and one patient had left atrial myxoma (AMA). The role of two dimensional echocardiogram (ECHO) is emphasised in these case reports since RMA generally produces no or minimal symptoms in children.

Case Reports

Case 1

A 12-year-old female Malay child, the eldest in the family, born to unrelated parents after a full-term, uneventful pregnancy, was admitted for breathlessness on exertion for four months. Her growth and milestones were normal. There was no history suggestive of haemoptysis or rheumatic fever. The other siblings were normal. On physical examination, she was tachypnoeic but was not cyanosed or anaemic. Her weight and height were appropriate for her age. Cardiovascular examination revealed pulse 110/min and regular, blood pressure 120/80 mmHg, normal heart sounds with sinus rhythm, grade and a 3/6 ejection systolic murmur over the left third and fourth intercostal space. Liver was palpable 1cm below the right subcostal margin. The other systems were normal.

X-ray chest revealed moderate cardiomegaly. Electrocardiogram (ECG) showed sinus rhythm, QRS axis 120°, P wave duration 0.08 sec in lead II, P wave bifid in V1 and V2. ECHO showed a pendunculated

hyperechogenic homogenous mass originating from the left atrium. The tumour measured 4.6/3.9 cm. The contractility and ejection fraction were normal. The serum aspartate transaminase level was > 1600 IU/L. The haemogram was normal but for thrombocytosis (platelet count $786 \times 10^9/L$). The AMA was removed surgically. The operative findings for the AMA include normal pericardium, solitary myxomatous tumour arising from interior aspect of fossa ovalis on the left atrial side. The tumour measured 5/4 cm. She was discharged well and subsequently followed up in our clinic.

Case 2

A six-year-old male Malay child born to nonconsanguineous parents, was admitted for delayed milestones and recurrent infantile spasms since three months of age. He was born at term and cried at birth. His motor and mental milestones were grossly delayed. His developmental age was approximately one year. The other siblings were normal.

Physical examination revealed the following: weight 15.2 kg (25 to 50th centile), height 99cm (10th to 25th centile), hypopigmented macule over the face and left calf muscle, and a few cafe-au-lait spots over the right leg. The cardiovascular system examination revealed heart rate 120/minute and regular, normal heart sounds, grade 3/6 ejection systolic murmur over the precordium. The other systems were normal.

Investigations revealed X-ray chest mild cardiomegaly, ECG sinus rhythm, QRS axis $+60^\circ$ and no chamber hypertrophy. ECHO showed a pendunculated hyperechogenic mass, originating from the right wall of interventricular septum with tumor size of 0.9/0.5cm. The contractility and ejection fraction were normal. The complete haemogram and serum electrolytes, liver function tests and arterial blood gas analysis were normal. He was managed conservatively. He was subsequently discharged and followed up.

Case 3

A six-month-old male Malay infant born to non-consanguineous parents was admitted for delayed milestones and recurrent infantile spasms, since three months of age. He was born at term by spontaneous vertex delivery at district hospital and cried at birth. The other siblings were normal.

Physical examination revealed weight 8.5 kg (75 to 90th centile), length 63 cm (25 to 50th centile), head circumference 43.5cm, hypopigmented macules of varying sizes over the trunk, back, upper arm and face, and a cafe-au-lait spot over the right leg. Cardiovascular system examination revealed pulse 110/minute, respiratory rate 30/minute, regular, normal heart sounds and grade 3/6 mid-systolic murmur over the precordium. The muscle tone was normal, deep tendon reflexes were brisk and the cranial nerves were normal.

Investigations on admission revealed: Hb: 8.6g/dl, packed cell volume 27.7 per cent, leucocyte count $12.0 \times 10^9/l$, red cell count $4.22 \times 10^9/l$, normal differential count. Liver functions tests and serum electrolytes were normal. X-ray chest showed mild cardiomegaly. ECG showed sinus rhythm, heart rate 110/minute, QRS axis $+100^\circ$, PR interval 0.08 sec, ECHO revealed a round pendunculated echogenic mass arising from the right wall of interventricular septum, measuring 0.8/0.5 sec. (Figure 2). He was treated conservatively and followed up.

Discussion

AMA is rare below the age of 15. The commonest site of AMA is left atrium, often originating in

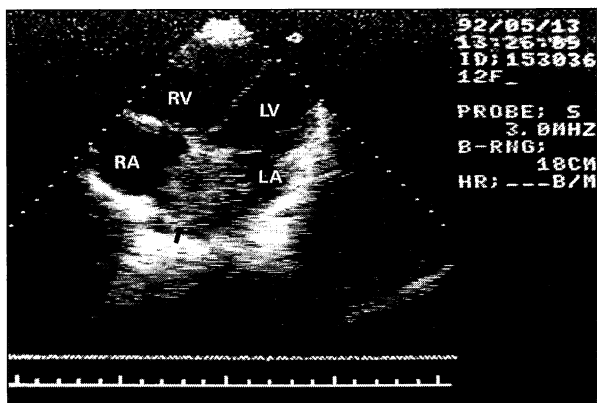


Fig. 1: Showing left atrial myxoma measuring 4.8/3.9 cm echocardiographically in apical four chamber view, (black arrow indicating the site of mass)

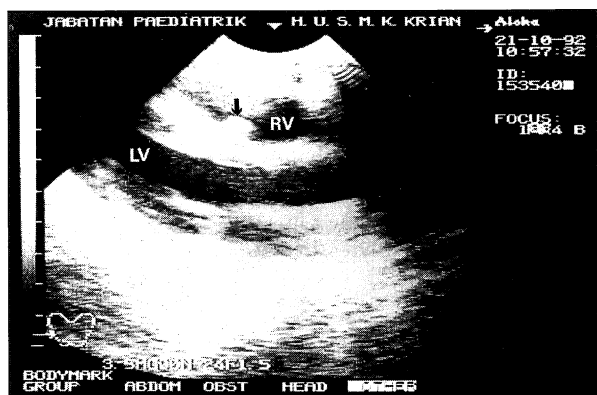


Fig. 2: Two dimensional echocardiogram parasternal view showing rhabdomyoma (black arrow) of the right ventricle measuring 0.8/0.5cm in a six month old infant

the atrial septum in the region of fossa ovalis. AMA may arise directly from the atrium or may be pedunculated. The postulated theories for the genesis of AMA are altered thrombus or a true benign tumour consisting of multipotential mesenchymal cells².

The clinical features of AMA are protean. Children with AMA may be asymptomatic or may simulate mitral valve disease.² Surgery for AMA is the definitive of therapy which carries a mortality of 5 per cent³. Dysrhythmias in AMA like atrial flutter, fibrillation, junctional rhythm, sinoatrial block or complete atrioventricular block can occur post-operatively. Associated features in AMA include lentiginosis, skin myxomas, adrenocortical dysfunction, blue nevi, neurofibromatosis, ephelides, testicular tumours and pituitary adenomas.³ Recurrence of AMA may occur but is uncommon.⁵ Ninety per cent of them occur in the wall of the right or left ventricle or interventricular septum.² The findings in the first female child like 'P' mitrale in electrocardiography suggesting left atrial hypertrophy and 3/6 ejection systolic murmur with normal heart sounds, a smooth globular pedunculated homogeneous mass in the left atrium seen in the two dimensional ECHO were suggestive of left atrial myxoma.

Children with RMA usually present with obstructive symptoms and infrequently with atrial or ventricular tachycardia or arrhythmias and at times with heart blocks⁵. The features in Case 2 & 3 with TS like ejection systolic murmur with normal heart sounds, and an echogenic homogeneous pedunculated mass arising from the wall of the interventricular septum on the right side, were suggestive of right ventricular RMA.

RMA histologically consists of large vacuolated cells containing glycogen.⁴ Prognosis in children with RMA depends on the side of the tumour. The known complications in children with intracardiac RMA include arrhythmias, shock and congestive cardiac failure. Mortality in such infants is high. One of the early indications for surgical interventions in children with RMA is uncontrollable dysrhythmias. Recently, it has been shown that involution of tumour does occur in children with RMA⁶.

This case report describing two children with RMA diagnosed during routine echocardiogram highlights the need to do thorough evaluation of the cardiovascular system in children with TS even in the absence of cardiac symptoms.

Acknowledgement

We thank Dato' Yahaya Awang, cardiothoracic surgeon, at Institut Jantung Negara, Kuala Lumpur and Dr. Lim Ming, paediatric cardiologist at Institut Jantung Negara, Kuala Lumpur for their help in the management of the first child with atrial myxoma.

References

1. Siew TY, Robaayah Z. Left atrial myxoma, Three Case reports. *Med J Malaysia* 1986;4 : 229-32.
2. Goodwin JF. Diagnosis of left atrial myxoma. *Lancet* 1963;1 : 464-7.
3. Poole GV Jr, Breyer RH, Holliday RH *et al*. Tumors of the heart. Surgical Considerations. *J Cardiovasc Surg* 1984;25 : 5-11.
4. Piehler JM, Lie JT, Giuriani ER. Tumors of the heart. In: Bradenburg RO *et al*, (eds). *Cardiology. Fundamentals and practice*. Chicago: Year Book Medical Publishers Inc, 1987 : 1682-3.
5. Brinbaum S, McGahan JP, Janos GG *et al*. Fetal tachycardia and intramyocardial tumors. *J AM Coll Cardiol* 1985;6 : 1358-61.
6. Roach ES. Diagnosis and management of neurocutaneous syndrome. *Semin Neurol* 1988;8 : 83-96.