

## Syndrome X: an uncommon cause of angina

H. T. Ong, MBBS, MRCP, M MED  
*Honorary Consultant Cardiologist  
Penang Adventist Hospital*

*\*Presently Consultant Cardiologist, Gleneagles Medical Centre, Penang, Malaysia.*

### Summary

A 61-year old lady presented clinically in unstable angina with ST-segment depression typical of myocardial ischemia. However, coronary arteries were completely normal at angiography. Exercise testing reproduced symptoms and ST-segment depression. A diagnosis of Syndrome X was made, an uncommon disorder of myocardial ischemia with normal coronary anatomy and excellent prognosis.

*Key Words:* Syndrome X, angina, normal coronary.

### Introduction

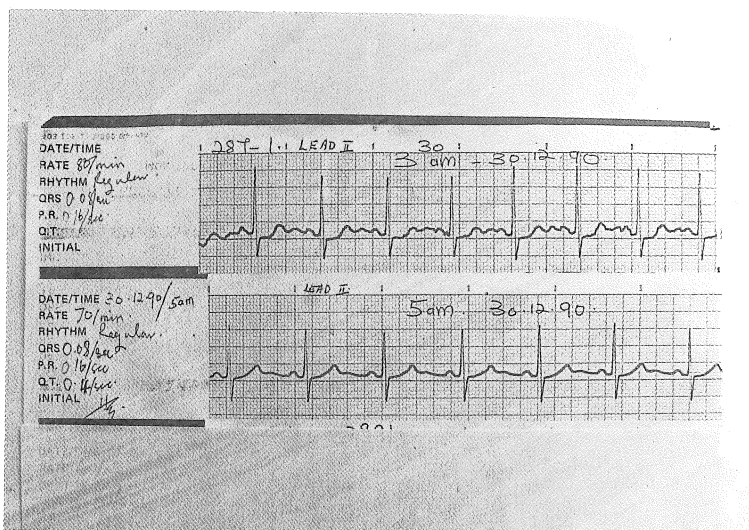
Syndrome X is angina pectoris and myocardial ischemia in the presence of a normal coronary anatomy.<sup>1</sup> While normal coronary arteriograms may occur in up to 15% of patients investigated for chest pain, true ischemia in such patients is rare<sup>2,3</sup>. The patient reported had classical symptoms of angina pectoris which responded to intravenous nitrate therapy with resolution of ST-segment depression and yet was found to have a normal coronary arteriogram.

### Case report

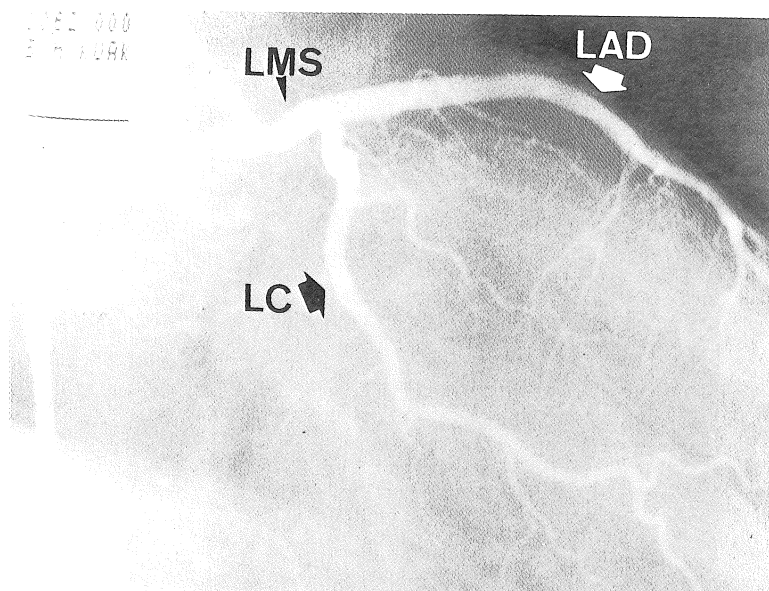
KSH, a 61-year old lady, was referred with a month's history of classical angina pectoris. The symptoms were initially present on exertion and relieved with sublingual nitrates. However, despite hospitalisation and increasing medical therapy, the symptoms worsened in frequency and intensity and were even present at rest; she was then referred for management and investigation of her angina. Risk factors for coronary atherosclerosis were hypertension and a family history of ischemia heart disease. At presentation, clinical examination was normal, as was the electrocardiogram and chest x-ray. The electrocardiogram a day later revealed ST-segment depression in leads I, aV1, and V3 to V6.

A diagnosis of unstable angina was made and the patient put on aspirin, metoprolol as well as heparin and isosorbide dinitrate infusion. Two days after admission, angina recurred and electrocardiographic monitor revealed significant horizontal ST-segment depression; both symptoms and ST-segment depression resolved on reinitiating intravenous nitrate therapy (Figure 1). Subsequent hospital course was uneventful and the patient was discharged on aspirin, isosorbide dinitrate, diltiazem, and metoprolol.

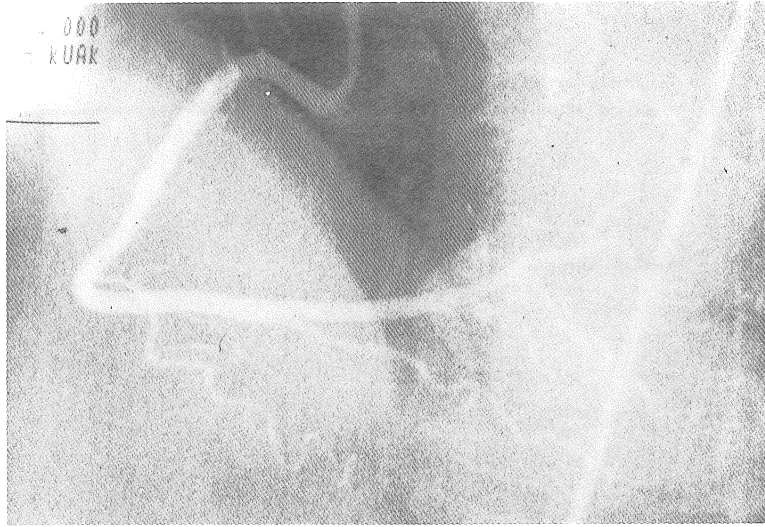At cardiac catheterisation, left-ventricular function was normal with an end-diastolic pressure of 15mm Hg and a post-ectopic ejection fraction of 89%. Coronary anatomy was normal (Figure 2). An exercise test done subsequently was positive with angina and 1 mm horizontal ST-segment depression in leads II, III, aVf, V5, and V6 at 75% of target heart rate (Figure 3). The patient was informed of the organic but benign nature of her disease, and continued on metoprolol 50 mg bd and sublingual nitrate for symptomatic relief.



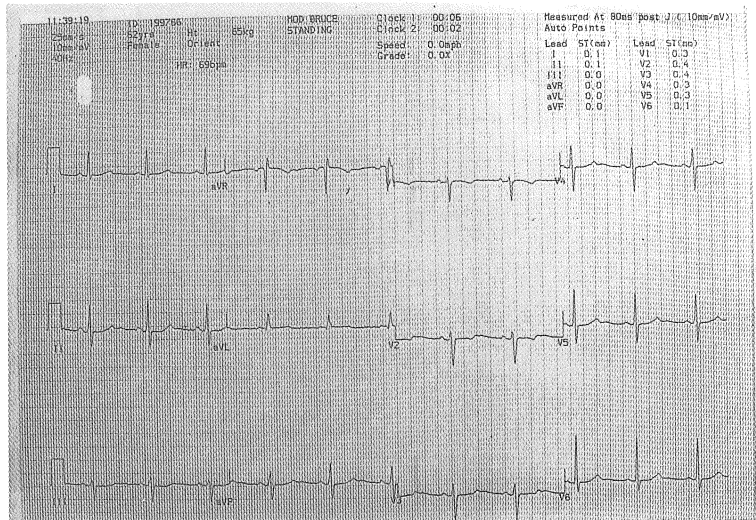
**Fig 1: Resolution of ST-segment depression after initiating intravenous nitrate therapy.**



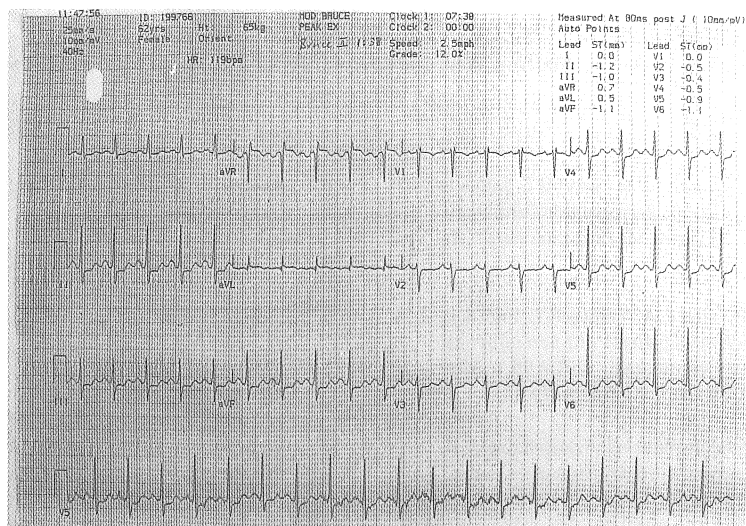
**Fig 2a: Left coronary study in the right anterior oblique position showing the normal left main stem (LMS), left circumflex (LC) and left anterior descending (LAD) arteries.**



**Fig 2b: Right coronary study in the left anterior oblique position showing the normal right coronary artery.**



**Fig 3a: Resting electrocardiogram**



**Fig 3b: Electrocardiogram at peak exercise with significant ST-segment depression in the inferior and lateral leads.**

## Discussion

Unstable angina includes patients with recent onset angina, stable angina increasing in frequency and duration, angina provoked by less than the usual stimuli and angina at rest<sup>4</sup>. The presenting history in this patient establishes a clinical diagnosis of unstable angina. The absence of electrocardiographic change at presentation does not exclude this diagnosis<sup>5</sup>. The presence of ST-segment depression on a subsequent 12-lead electrocardiogram however, strengthens the evidence for ischemia and unstable angina. Therapy in unstable angina is directed at its pathophysiology with anti-platelet agents, anticoagulants and vasodilators; beta-blockers and calcium antagonists may reduce pain but do not influence course and prognosis<sup>6</sup>. The patient initially received aspirin with heparin and nitrate infusion. The ensuing tachycardia was reduced with metoprolol. The calcium antagonist diltiazem was added prior to discharge.

Exercise testing is in fact contraindicated in unstable angina and coronary arteriography is urgently required<sup>7</sup>. Figure 2 illustrates the completely normal coronary anatomy and thus diagnoses Syndrome X. A positive exercise test with angina and ST-segment depression of more than 1 mm is often required as an inclusion criteria for Syndrome X<sup>8</sup>. Despite being on beta-blockers and achieving only 75% of target heart rate, the positive exercise test shown in Figure 3 further supports the diagnosis of Syndrome X in this patient.

It is now recognised that Syndrome X is not a psychosomatic disease but an organic disorder of myocardial ischemia<sup>9,10</sup>. Evidence for transient ischemia comes from regional lactate production and myocardial perfusion defects during pacing or exercise testing<sup>11,12</sup>. The mechanism underlying the ischemia may be a reduced coronary vasodilatory capacity due to abnormal constriction of the coronary prearteriolar vessels; derangement of vasoactive peptides produced by endothelial cells may be the cause of this inappropriate vascular tone at the micro vascular level<sup>9,13,14</sup>. Most importantly, the condition is benign and the prognosis good<sup>9,15</sup>.

Our patient was reassured that she did not imagine her pains, but that the outlook was excellent.

## Acknowledgement

The author wishes to thank Mrs Suclina Wah for secretarial assistnace.

## References

1. Davis G.J. Syndrome X. In: Sobel B E, Julian D G, Hugenholtz P G, eds. *Perspective in Cardiology*, 1988. London: Current Medical Literature Ltd., 1988; 113-17.
2. Kemp H G, Kronmal R A, Vliestra R E, Frye R L. Seven year survival of patients with normal or near normal coronary arteriograms : a CASS registry study. *J Am Coll Cardiol* 1986; 7:479-83.
3. Hutchison S J, Poole-Wilson P A, Henderson A H. Angina with normal coronary arteries: a review. *Quart J Med* 1988; 72:677-88.
4. Hurst J W. The recognition and treatment of four types of angina pectoris and angina equivalent. In: Hurst J W, Schlent R C, Rackley C E, Sonnenblich E H, Wenger N K, eds. *The Heart, artries and veins*. 7th ed. New York: McGraw-Hill, 1990; 1046-52.
5. Rutherford JD, Braunwald E, Cohn PF. Chronic ischemic heart disease. In: Braunwald E, ed. *Heart disease: a textbook of cardiovascular medicine*. 2nd ed. Philadelphia: W B Saunders, 1988: 1314-78.
6. Theroux P, Latour JG. Anticoagulants and their use in acute ischemic syndromes. In: Topol EJ, ed. *Textbook of interventional cardiology*. Philadelphia: W B Saunders, 1990: 28-48.
7. Schlant R C, Friesinger II G C, Leonard J J. Clinical competence in exercise testing. *J Am Coll Cardiol* 1990; 16:1061-65.
8. Levy R D, Shapiro L M, Wright C, Mockus L, Fox K M. Diurnal variation in left ventricular function: a study of patients with myocardial ischemis, Syndrome X, and of normal controls. *Br Heart J* 1987; 57:148-53.
9. Kemp H G Jr. Syndrome X revisited. *J Am Coll Cardiol* 1991; 17:507-8.
10. Lewis N P, Hutchison S J, Willis N, Handerson A H. Syndrome X and hyperventilation. *Br Heart J* 1991; 65:94-6.
11. Arbogast R, Bourassan M G. Myocardial function during atrial pacing in patients with angina pectoris and normal coronary arteriograms. Comparison with patients having significant coronary artery disease. *Am J Cardiol* 1973; 32: 257-63.
12. Korhola O, Valle M, Frick M, Wiljasaalo M, Riihimaki E. Regional myocardial perfusion abnormalities on Xenon-133 imaging in patients with angina and normal coronary arteries. *Am J Cardiol* 1977; 39Z: 355-59.
13. Maseri A, Crea F, Kaski J C, Crake T. Mechanism of angina pectoris in Syndrome X. *J Am Coll Cardiol* 1991; 17:499-506.
14. Henderson A H. Endothelium in control. *Br Heart J* 1991; 65: 116-25.
15. Isner J M, Salem D H, Banas J S, Levine H J. Long term clinical course of patients with normal coronary arteriography: follow-up study of 121 patients with normal and nearly normal coronary ateriograms. *Am Heart J* 1981; 102:645-53.