

# Foley catheter removal of blunt oesophageal foreign bodies in children

Goon Hong Kooi, FRCSEd., FRACS (Paed)  
*Assoc. Professor, Dept of Surgery*

Abdul Samad Sakijan, DMRD (Lon), FRCR (UK)  
*Dept. of Radiology,*

*Universiti Kebangsaan Malaysia,  
Jalan Raja Muda,  
50300 Kuala Lumpur.*

## Summary

In a two year period between 1985 and 1986, eight children presented with impacted blunt foreign bodies in the oesophagus were successfully treated by removal using a Foley catheter without anaesthesia. There were no complications. All patients were discharged well after one or two days in hospital. The technique is safe, rapid and easy to perform.

*Key words:* Blunt oesophageal foreign bodies, Foley catheter removal.

## Introduction

Ingestion of foreign bodies by children is a very common occurrence. Items range from smooth foreign bodies like coins to sharp ones like pins and needles. Fortunately most swallowed foreign bodies will pass through the gastrointestinal tract unobstructed. However, a few may be impacted in the oesophagus causing dysphagia. The conventional method involves removal of the foreign body under direct vision using an oesophagoscope under general anaesthesia. However, an easier method of removal using a Foley catheter has been described.<sup>1</sup>

## Materials and method

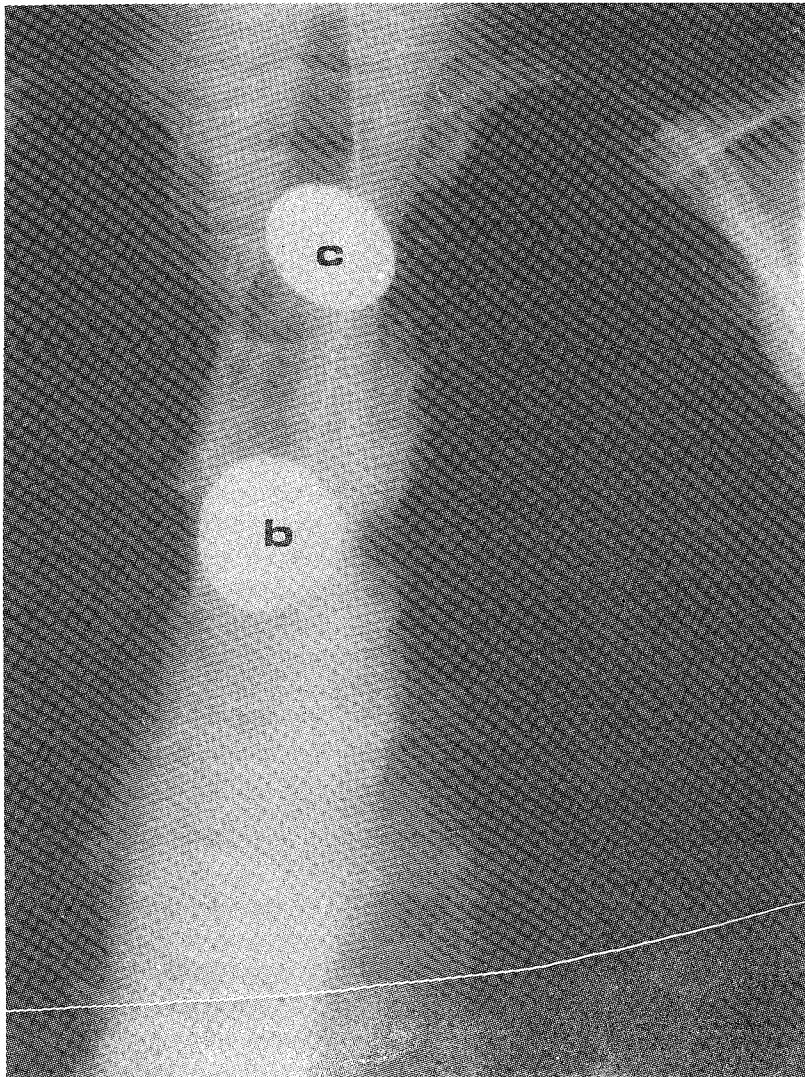
All children, 12 years and below, admitted with an impacted blunt foreign body in the oesophagus were included in the study. The diagnosis is confirmed on a plain chest x-ray which is usually carried out in the Casualty Department. Patients with sharp and jagged foreign bodies are excluded from the study.

The whole procedure is carried out in the Radiology Department. Cardiorespiratory resuscitation equipment including appropriately sized paediatric laryngoscopes and endotracheal tubes are kept easily accessible during the procedure. Foley catheters (sizes 12 to 16) are also kept ready for use. The balloon of the catheter is tested before use. It is necessary that the balloon inflates symmetrically to ensure maximal efficiency during removal. Contrast medium is used to inflate the balloon and the procedure is carried out under fluoroscopy. A chest screening is done to ensure that the foreign body is still impacted in the oesophagus before commencing the procedure. No sedation is given to the child. The oropharynx is sprayed with a small amount of local anaesthetic. The oropharyngeal route of insertion of the Foley Catheter is preferred

to the oronasal route. A size 14 Foley catheter is usually used but smaller sizes may be necessary in smaller children. The patient is put in a semiprone position and the fluoroscopic table turned to a steep head down position.

The Foley catheter is inserted per orally until it is past the foreign body. This is confirmed on fluoroscopy. The balloon is blown up. The size of the balloon varies and is assessed under fluoroscopy. Gentle traction is applied on the Foley catheter and the progress of the foreign body is followed under fluoroscopy (Fig. 1). If successful, the foreign body is brought up to the pharynx by the balloon and is quickly spat out by the patient. If unsuccessful, a second attempt is made. The procedure is terminated if there is undue difficulty in moving the foreign body.

After the procedure, the patient is returned to the ward and observed for a few hours before discharge.



## Results

Over a two year period between 1985 and 1986, eight children presented with impacted blunt foreign bodies in their oesophagus. The results are summarised in Table I. The age ranged from two to eight years old with a mean of 3.8 years. The majority were in the toddler age group. There were four males and four females. All except one patient presented acutely on the same day of ingestion of the foreign body with mild dysphagia. The exception was a two year old Indian boy with a history of oesophageal atresia with a tracheo-oesophageal fistula repaired at birth. He presented with a history of a chest infection for about two weeks and the impacted foreign body was seen on a chest x-ray, at the level of the previous anastomosis at the 2nd thoracic vertebral level. In the other patients, the foreign body was impacted at the level of the thoracic inlet.

All the foreign bodies were coins ranging from a one cent coin (1.8 cm diameter), five ten cents coins (2.0 cm diameter) to two twenty cents coins (2.4 cm diameter).

All attempts at extraction of the coins were successful. No difficulties were encountered in all cases, including the child with previous oesophageal surgery for oesophageal atresia. However, in the latter case, a little barium was introduced to assess the severity of the oesophageal narrowing before the removal was attempted. There were no complications resulting from this procedure. All patients were discharged well on the same day after the procedure.

**Table I**  
**Summary of eight cases with blunt oesophageal foreign bodies**

No.	Name	Ethnic gp.	Age (Year)	Sex	Nature and location of foreign body	Length of hospital stay (Days)	Underlying dis.
1	W.S.Y.	C	7	F	20¢ coin/Thoracic Inlet	1	Nil
2	N.R.	M	3	F	10¢ coin/Thoracic Inlet	1	Nil
3	W.K.R.	M	8	F	10¢ coin/Thoracic Inlet	1	Nil
4	J.G.	I	2	M	10¢ coin/Previous anastomosis – T <sub>2</sub> level	2	Oesophageal atresia – repaired at birth
5	L.C.W.	C	2	F	1¢ coin/Thoracic Inlet	1	Nil
6	S.S.	M	3	M	10¢ coin/Thoracic Inlet	1	Nil
7	V.T.	I	4	M	10¢ coin/Thoracic Inlet	1	Nil
8	B.S.	M	2	M	20¢ coin/Thoracic Inlet	1	Nil

## Discussion

The Foley catheter technique is a proven and safe method of extraction of smooth foreign bodies impacted in the oesophagus. It is preferred to endoscopic extraction under general anaesthesia which still carries a small but significant risk.

A high success rate is seen in this small series (100%) as well as in many other larger series.<sup>1,2,3</sup> No complications were encountered. Most patients present acutely soon after ingestion of the foreign body. However a longer history does not contraindicate this procedure as evidenced in

one patient. All patients presented with symptoms of obstruction and the impacted foreign bodies, are unlikely to pass with conservative treatment. In fact, conservative measures will prolong hospital stay and may lead to the real danger of aspiration pneumonia from unswallowed saliva. Because of all these reasons and the high success rate of Foley catheter extraction, conservatism plays no part in the treatment of this problem.

The presence of an underlying oesophageal pathology also does not contraindicate this procedure. If it is suspected, a barium swallow is advisable to delineate the underlying pathology, so that more care can be adopted during the procedure. Both the oropharyngeal and nasopharyngeal route of insertion of the Foley catheter can be used. The nasopharyngeal route is easier to perform and more tolerable to the patient. However, difficulties may be encountered when the balloon has been withdrawn with the foreign body. Some time is required to deflate the balloon before it can be withdrawn through the nose. There is a possibility that during this short interval, the balloon or the foreign body may obstruct the airway. Thus, the oropharyngeal route is preferred because the catheter and the coin can be removed through the oral cavity in one swift motion. Cardiorespiratory resuscitation equipment is always kept on standby even though respiratory arrest due to airway obstruction has not occurred in this series or reported in other larger series.<sup>1,2,3</sup>

All the foreign bodies in this series were coins. However the procedure is suitable for other smooth foreign bodies as well. Foreign bodies with sharp or jagged edges would obviously contraindicate this technique for fear of injury to the oesophagus. Patients usually stay in hospital for one to two days only and no general anaesthesia is required. This will certainly reduce costs. In fact, with more experience, one can envisage doing this as an outpatient procedure if the patient presents early in the day, thereby further reducing costs.

## References

1. Campbell, JB, Quattromani PL and Foley LC. Foley catheter removal of blunt esophageal foreign bodies. Experience with 100 consecutive children. *Pediatr Radiol* 1983, 13: 118-119.
2. Carlson DH. Removal of coins in the esophagus using a Foley catheter. *Pediatrics* 1972, 50: 475.
3. Shackelford GD, McAlister WH and Robertson CL. The use of a Foley catheter for removal of blunt esophageal foreign bodies from children. *Radiology* 1972, 105: 455.