

A CASE OF SCHIZOPHRENIA WITH THE KLIPPEL-FEIL SYNDROME

SAROJA KRISHNASWAMY
MASTURA MOHAMED

SUMMARY

A case of the Klippel-Feil syndrome presenting with schizophrenia is described. The Klippel-Feil syndrome is reported to be associated with abnormalities in many systems of the body, but its association with a schizophrenic illness has not been described.

INTRODUCTION

Klippel and Feil in 1912 first reported on a patient with short neck, low posterior hair line and limited movement at the neck due to complete fusion of the cervical spinal vertebrae. These features now constitute the classical clinical triad or hallmark of the Klippel-Feil Syndrome.

Saroja Krishnaswamy, MBBS (Mal),
DPM Psych. (Lond)
Lecturer
Department of Psychiatry
Faculty of Medicine
Universiti Kebangsaan Malaysia
50300 Kuala Lumpur, Malaysia

Mastura Mohamed, MBBS(Mal), DMRD,
FRCR (Lond)
Lecturer
Department of Radiology
Faculty of Medicine
Universiti Kebangsaan Malaysia
50300 Kuala Lumpur, Malaysia

Further reports^{1,2} have suggested that there may be associated further defects which may not be obvious but more serious. In a review of the literature, we are unable to find any reports on the association of the syndrome with any psychiatric abnormalities. In this report we describe one case who presented to us with psychiatric manifestations.

CASE HISTORY

S.D. aged 36-years-old, a divorcee from Banting, was referred to us by the gynaecologist upon discovering that they could not verify her complaints of being three months pregnant and having bleeding per vagina. When interviewed, she looked pale and thin, wore shabby clothes and looked generally unkempt. She smiled inappropriately and appeared preoccupied. She was quiet and would respond only when spoken to. She had many stable delusions amongst them being: she was married to a member from a royal family; her father was a member of the Malaysian Cabinet.

She walked with little free movements of her arms and neck; on examination it was apparent she had a short neck with limited movements. Vaginal examination confirmed that she could never have been pregnant because she had atretic vagina measuring 2 cm long ending in a blind pouch with absent cervix and uterus as well. However, she had well developed secondary sexual characteristics. There was no family history of mental illness.

Investigations

Further investigations revealed that she had high blood urea and serum creatinine and low haemoglobin level. Intravenous urography was done to elicit the cause of her renal failure. The intravenous urography showed: poor functioning right kidney with mildly clubbed pelvicalyceal system; no visualisation of the left kidney despite delayed films taken.

Ultrasound was carried out to elucidate further whether the left kidney was present, and to examine the genital organs as well. This revealed: small right kidney with ill-defined central sinus complex and irregular renal outline consistent with chronic pyelonephritis; the left kidney was not detected in its normal position, most likely absent; uterus and both ovaries were not identified in their normal position.

From the intravenous urography and ultrasound we concluded that the patient had chronic pyelonephritis of the right kidney and absent left kidney, uterus and probably ovaries as well.

The chest X-ray was reviewed and she was found to have the following skeletal anomalies (Fig. 1): fusion of the right fifth, sixth ribs and left second, third ribs. Sprengel's deformity bilaterally – abnormally high location of the scapula with associated omovertebral bone seen.

As the above anomalies are commonly associated with anomalies in the cervical spine, X-ray of this region was done. This showed congenital fusion of C2/C3 vertebral bodies and their neural arches. There is also fusion of C5/C6/C7 and T2/T3 as well (Fig. 2).

The radiological appearances of the skeletal abnormalities in the cervical spine with associated abnormalities in the scapula and ribs are diagnostic of Klippel-Feil syndrome.

Other investigations carried out such as: LE cells, ANF, urine FEME, Mantoux test – all were negative; LSH, FH are within normal limits; barr bodies positive; urine culture grew *E. coli*.




Fig 1 Chest Xray showing Sprengel's deformity and fusion of ribs.

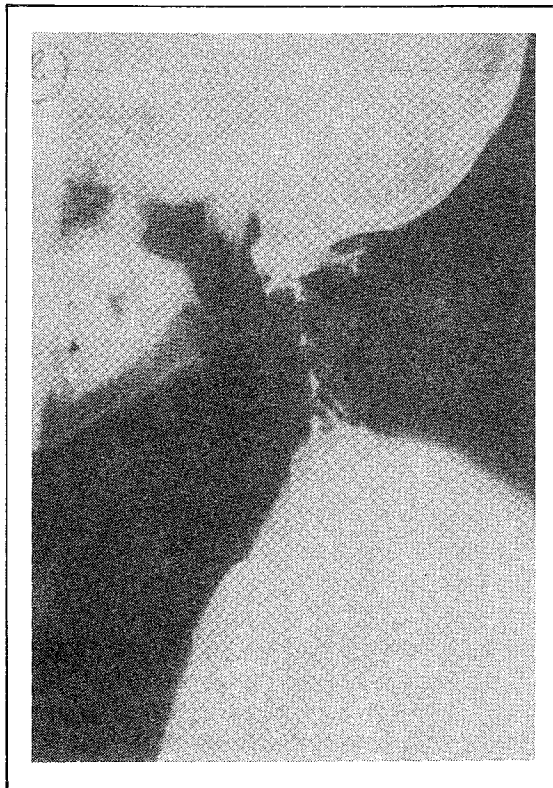


Fig 2: Lateral Cervical Spine

She was treated with a low dosage of Haloperidol (1.5 mg tds) and antibiotics. Her mental status improved, and prior to discharge about two months after her admission, her delusions had completely disappeared and when asked to explain she just shrugged it off with "I don't know". However, she was still in renal failure and is under the care of the Nephrologist who is considering the possibility of haemodialysis or renal transplant in the future. It should be mentioned that her mental status did not vary with the blood urea and serum creatinine levels.

DISCUSSION

S.D.'s elder brother remembers her as often truanting school and running away to join local touring bands, often singing with them as well. Soon after this at the age of 16, she was married off to a police constable attached to the Forest Police and left to set up home with him in an isolated part of Negeri Sembilan, a state in the country. She was unhappy in her marriage and often spent long stretches of time in her parental home. During this time she unsuccessfully sought treatment for her infertility. Subsequently, about ten years ago she adopted a baby girl.

S.D.'s psychotic state can be diagnosed as schizophrenic illness according to ICD9.³ In trying to explain the association with Klippel-Feil Syndrome we postulate that either: the relationship is coincidental; it could be due to

predisposing neurological abnormalities not elucidated yet but which may be suspected in view of the abnormalities occurring in every system of the body. The only neurological abnormalities reported so far are involuntary paired movements of arms and hands called synkinesis suspected to be due to developmental defects; factors like being thrust into an early marriage, being isolated from friends and family in her marital home, her physical deformities and primary infertility being adverse factors which could have contributed to her psychotic breakdown.

ACKNOWLEDGEMENTS

The authors would like to thank Assoc. Professor Madya Ramli Hassan, Head of Department of Psychiatry, for his advice and Cik Rohani and Cik Rohana binte Baba for typing the manuscript.

REFERENCES

- ¹ Hensiger Robert *et. al.* Klippel-Feil Syndrome: A constellation of associated anomalies. *Journal of Bone and Joint Surgery* 1974; 56A: 61245-61253.
- ² Ramsey Jock, Bliznak Johnny. Klippel-Feil Syndrome with Renal agenesis and other abnormalities. *Am J Roentgenol* 1971; 113:460-463.
- ³ *Manual of the International Classification of Disease. Injuries and Causes of Death, Rev. 9.* World Health Organisation, 1978.