

# DIAGNOSIS OF MENISCAL LESIONS OF THE KNEE

KULDIP SINGH DHILLON  
SAMUEL DORAISAMY  
K. RAVEENDRAN

## SUMMARY

*In a prospective study of 50 patients with suspected tear of the meniscus of the knee, the clinical diagnosis, arthrographic and arthroscopic findings were compared at arthrotomy. The clinical diagnosis was correct in 85%, arthrographic in 54%, and arthroscopy in 91% of the patients.*

## INTRODUCTION

The precise diagnosis of internal dearrangement of the knee can be elusive since the signs and symptoms are frequently so similar, and standard roentgenograms are often nondiagnostic. Even at arthrotomy, it can be difficult to be certain that all etiological anatomical abnormalities have been properly visualised. For these reasons, diagnostic aids have long been sought and arthrography has been widely used to improve diagnostic accuracy. Recently arthroscopy has been added to the techniques for evaluation of the knee. It was our

aim to assess the usefulness of arthroscopy and to evaluate the efficacy of arthrography in the light of this new development in the diagnosis of meniscal lesion of the knee joint.

## PATIENTS AND METHODS

A prospective study was undertaken at the University Hospital Kuala Lumpur, from January 1983 to June 1984. 50 patients were included in this study where a tear of the meniscus was suspected as a cause of internal dearrangement of the knee. The clinical diagnosis was based on a detailed history, during which the patients were carefully questioned for evidence of buckling, catching, locking, giving-way, effusion, pain, weakness, disturbance in gait and instability. During the clinical examination, the following important signs were looked for and recorded: slight loss of terminal flexion and extension of the knee; swelling; local tenderness; quadricep weakness; hamstring contractures. Rotatory grinding test of tibia on femur and tests for varus, valgus, antero-posterior and rotatory laxity were a standard part of the examination.

All 50 patients had double contrast arthrography carried by one of the authors (S.D.). He had no knowledge of the clinical diagnosis. Fluoroscopic and spot film technique of Butt and Mc Intyre<sup>1</sup> was used.

Arthroscopy of the knee was performed under general or regional anaesthesia with a tourniquet.

---

Kuldip Singh Dhillon, FRCS  
K. Raveendran, FRCS

Department of Orthopaedic Surgery  
Samuel Doraisamy, DMRD  
Department of Radiology  
Faculty of Medicine  
University of Malaya  
Kuala Lumpur, Malaysia

---

A 3.8mm Storz diagnostic arthroscope with a 30° offset was used. The approach was antero-lateral or antero-medial and a probe was routinely used. The surgeon had no prior knowledge of the arthrographic finding.

All 50 patients had arthrotomy following arthroscopy. At arthrotomy the meniscus that was thought to be pathological was removed.

## RESULTS

At completion of the study, the data of the patients was analysed.

### Age

The age of the patients ranged from 19 years to 39 years. The majority of the patients were in the 26–30 years age group (Fig. 1).

### Ethnic Distribution

In this series, the Indians formed a majority, being 35 out of the 50 patients. This probably

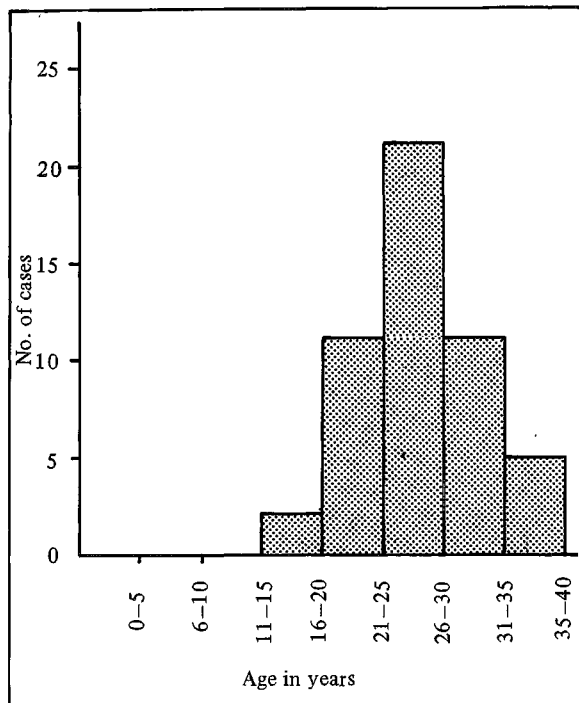


Fig. 1 Age distribution.

could be related to the fact that football is a popular sport among the Indians locally, and the single largest type of injury amongst the 50 patients was a football injury.

### Associated Ligamentous Injury

The common association of ligamentous injury and tear of the menisci is well known. In our series, 83% of the patients had ligamentous laxity associated with a tear of the menisci. 34 out of the 50 patients had a laxity of the anterior cruciate ligament which was confirmed at examination under anaesthesia and arthrotomy.

### Clinical Diagnosis

Although the number of patients in the series was 50, the number of arthrotomies (medial and lateral) was 54, because some patients had medial as well as lateral compartment explored (Table I).

The clinical diagnosis was correct for medial meniscus in 32 out of the 38 arthrotomies. There were five false positive and one false negative diagnosis, giving a total of 85% accuracy for clinical diagnosis of medial meniscus tear.

Clinical suspicion of tear of lateral meniscus was confirmed in 14 of the 16 arthrotomies, giving an accuracy of 87.5%. Both the false negatives were picked up by arthroscopy.

### Arthrography

Arthrographic evaluation of tears of the meniscus was 54% accurate in our series. For tears of the

TABLE I  
CLINICAL ACCURACY

	No. of arthrotomies	Correct diagnosis	False positive	False negative	(%)
Medial	38	32	5	1	84.2
Lateral	16	14	1	1	87.5
Total	54	46	6	2	85

**TABLE II**  
**ARTHROGRAPHIC ACCURACY**

	No. of arthrotomies	Correct diagnosis	False positive	False negative	(%)
Medial	38	17	4	13	45
Lateral	16	12	0	4	75
Total	54	29	4	17	54

medial meniscus the accuracy was 45%. For tears of the lateral meniscus the accuracy was 75% (Table II).

### Arthroscopy

No false positive diagnosis was made with arthroscopy. The diagnosis was missed in five instances giving an accuracy of 91% with arthroscopy. No complications were seen with arthroscopy in this series (Table III).

### Overall Accuracy

The overall accuracy was good with both arthroscopy (91%) and clinical evaluation (85%) but poor with arthrography (54%).

### Combined Accuracy

Combined accuracy of the three methods of evaluation taken together was 98% in our series. The accuracy was assessed by comparing the clinical diagnosis, arthrographic diagnosis and arthroscopic diagnosis with the findings at arthrotomy and meniscectomy.

### DISCUSSION

Various claims have been made of diagnostic accuracy by clinical evaluation, arthrography and arthroscopy (Table IV), depending on the experience and skill of the investigators.

Good clinicians claim an accuracy of diagnosis approaching 90% by examination alone.<sup>2</sup> However Jackson and Abe<sup>3</sup> reported a clinical accuracy of only 68.5%. The majority of their cases were 'problem' knees, referred after other specialists had experienced difficulty in establishing the diagnosis.

**TABLE III**  
**ARTHROSCOPIC ACCURACY**

	No. of arthrotomies	Correct diagnosis	False positive	False negative	(%)
Medial	38	35	0	3	92.1
Lateral	16	14	0	2	87.5
Total	54	49	0	5	91.0

**TABLE IV**  
**CLAIMS AS SEEN BY OTHER INVESTIGATORS**

Investigators	Clinical (%)	Arthrogram (%)	Arthroscopy (%)
Jackson and Abe <sup>3</sup>	68.5	68.2	95
Gilles and Seligson <sup>4</sup>	85	83	68
Nicholas <i>et al.</i> , <sup>5</sup>		97	
DeHaven and Collins <sup>6</sup>	72	78 (84 medial 72 lateral)	94
Casscells <sup>7</sup>			80
McGinty and Metza <sup>8</sup>			91 G.A. 95 L.A.

In our series, cases where the diagnosis was quite obvious clinically, were also included. Our clinical accuracy of 85% is similar to that reported by Gilles *et al.*<sup>4</sup>

Accuracy with arthrography has been reported from as low as 68% by Jackson and Abe<sup>3</sup> and as high as 97%.<sup>5</sup> De Haven<sup>6</sup> reported an arthrographic accuracy of 78% as compared to his arthroscopic accuracy of 94%. As in his series, our arthrography was the least reliable. It is felt that considerable interest and experience is required to produce and interpret a consistently reliable arthrogram. This is not available at present with the existing diversity of a radiologist's workload in many busy hospitals.

In this series arthroscopy proved to be the most accurate diagnostic method. Prior knowledge of the clinical diagnosis but not of the arthrographic finding was available to the surgeon. This was because majority of the cases were seen and treated by the same surgeon. Some degree of personal bias could not be avoided.

However when considering the strength and weakness of arthroscopy, arthrography and even arthrotomy as adjunctive techniques to clinical diagnosis, it is apparent that the three techniques complement each other and are more accurate taken together than individually.

## ACKNOWLEDGEMENT

I wish to thank Professor N. Subramanian for his help in preparing this paper. Grateful acknowledgement is also made to the Director, University Hospital, for permission to publish this paper and to Miss Khamisah Sulaiman for typing this manuscript.

## REFERENCES

<sup>1</sup> Butt W P, Mc Intyre J L. Double contrast arthrography of the knee. *Radiology* 1969; 92: 489.

- <sup>2</sup> Insall J N. Menisectomy. In: Insall J N (ed). *Surgery of the knee*. New York: Churchill, Livingstone, 1984; 150.
- <sup>3</sup> Jackson R W, Abe I. The role of arthroscopy in the management of disorders of the knee. An analysis of 200 consecutive examinations. *J Bone Joint Surg* 1972; 54B 310.
- <sup>4</sup> Gilles H, Seligson D. Prevision in the diagnosis of meniscal lesion. A comparison of clinical evaluation, arthrography and arthroscopy. *J Bone Joint Surg* 1979;61A:343.
- <sup>5</sup> Nicholas J A, Freiburger R M, Killoran P J. Double contrast arthrography of the knee. *J Bone Joint Surg* 1970;52A:203.
- <sup>6</sup> De Haven K E, Collins H R. Diagnosis of internal dearrangement of the knee. The role of arthroscopy. *J Bone Joint Surg* 1975;57A:802.
- <sup>7</sup> Casscells S W. Arthroscopy of the knee joint. A review of 150 cases. *J Bone Joint Surg* 1971;53A:287.
- <sup>8</sup> Mc Ginty J B, Matza K A. Arthroscopy of the knee. Evaluation of an outpatient procedure under local anaesthesia. *J Bone Joint Surg* 1978;60A:787.