

# A RARE CAUSE OF ACUTE APPENDICITIS: BURKITT'S LYMPHOMA OF THE APPENDIX

SAMANI ABD. GHANI  
SYED NOORI  
TAN PUAY ENG

## SUMMARY

*This paper presents a case report of a primary lymphoma of the appendix as the underlying cause of acute appendicitis. As in previous reported cases, diagnosis can only be made intraoperatively followed by a proven histopathological picture as they present with an acute surgical abdomen.*

## INTRODUCTION

The earliest report on gastrointestinal lymphoma was made by Debrunner who in 1883 described the first authentic case of lymphoma of the large bowel. Knox in 1945 found reports of 15 malignant lymphoma of the appendix that were sufficiently well documented to be accepted as primary in the appendix, and reported a case of his own. In

---

Samani Abd. Ghani  
Registrar

Syed Noori  
General Surgeon and Lecturer  
Department of Surgery

Tan Puay Eng  
Medical Officer  
Department of Pathology

Faculty of Medicine  
University of Malaya  
Kuala Lumpur, Malaysia

---

subsequent reports, eight more cases in which the lesion would appear to have been in the appendix were discovered. The diagnosis were established in all instances after appendectomy and resection of adjacent cecum in three, right colectomy in two and a radical operation in two.

Since then isolated reported cases of appendicular lymphoma was noted, the last was the two case reports from Ontario, Canada.<sup>1</sup>

## CASE HISTORY

A 22-year-old Malay male was admitted to University Hospital, Kuala Lumpur on 18 February 1984 with a complaint of (R) sided abdominal pain one day prior to admission. Pain was described as sudden onset, progressive in nature, mainly in the right iliac fossa region. It was associated with nausea and vomiting with low grade fever. No urinary or bowel changes were noted. History review revealed generalised malaise and weakness for the past two weeks.

Upon questioning, patient was apparently seen in A & E Unit, University Hospital on 21 January 1984 for complaint of right hypochondrium and lumbar pain associated with low grade fever. Patient was treated as having myalgia with upper respiratory tract infection and was discharged.

Physical examination revealed a fit young man, with a temperature of 37.8°C. The only significant

finding was in the abdomen where (R) IF tenderness with guarding and rebound tenderness was elicited. No masses or organomegaly was found. Per rectal examination produced tenderness in the (R) side.

No significant lymphadenopathy was noted. A provisional diagnosis of acute appendicitis was made. Basic investigation on admission showed Hb - 14.3 g/100 ml; PCV - 42%; Platelet - adequate; Wbc - 15,800/ $\mu$ l; Metamyelocytes - 1%; M - 74%; Cl - 1%; L - 21%; M - 3%. Urine FEME was normal. Patient was subjected to appendicectomy on 18 February 1984. The operative finding can be seen in Fig. 1.

Retroperitoneum was incised along the lateral border of the appendix and the (R) ascending colon. Appendix and lymph nodes were dissected and freed from ascending colon, cecum and terminal ileum. Appendicectomy was performed in the usual manner. No perforation was noted.

Patient was put in i/v Bactrim and Flagyl. Post-operative recovery was uneventful.

## RESULTS

A solid tumour of 10 x 8 cm, weighing 200 g was found. Cut surfaces revealed a haemorrhagic tumour, replacing almost the entire appendix, with

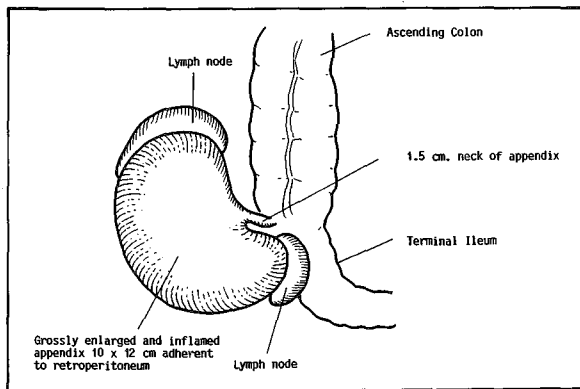


Fig. 1 Operative finding showed the appendix to be grossly enlarged and inflamed.

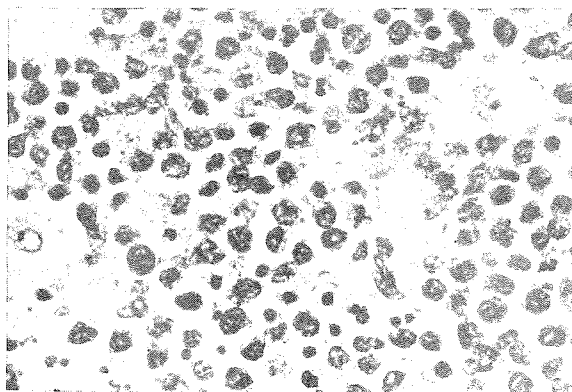


Fig. 2 Large, undifferentiated malignant lymphoid cells with non-neoplastic, foamy histiocytes and pyknotic cells.

only the remnants of it being recognisable (Fig. 2). Histology showed the appendix was infiltrated and compressed by expanding sheets of undifferentiated malignant lymphoid cells of Burkitt's type. The tumour cells had large, round to oval nuclei, multiple nucleoli, moderate amount of amphophilic cytoplasm, and exhibiting frequent mitoses. Many pyknotic cells were present. Non-neoplastic histiocytes with pale nuclei, abundant foamy cytoplasm containing ingested debris, were prominent, contributing to the characteristic 'starry sky' appearance of this tumour. Similar tumour deposits were found in two of the five serosal lymph nodes. Acute inflammation and haemorrhage were noted in the remaining appendiceal tissue proximal to the tumour.

In short, this was primarily an appendiceal lymphoid malignancy with secondary lymph node involvement. This extranodal origin is characteristic of Burkitt's lymphoma which is a neoplastic proliferation of B lymphocytes. It has a very high rate of turnover, with cell death rate - 70% of cell renewal rate. As such, the large number of dead (pyknotic) cells present stimulate the proliferation of histiocytes seen in this tumour.<sup>2</sup> In non-endemic areas, association with Epstein-Barr virus infection is only 15-20% and hence a negative EB serology obtained in this patient is not incompatible with the diagnosis of Burkitt's lymphoma.

## DISCUSSION

Collins reported 11 cases of primary lymphosarcoma in 71,000 human appendix specimen, an incidence of 0.015%. Most reports of primary lymphosarcoma of the appendix do not mention in a simple case of Burkitt's lymphoma except for two case reports of Burkitt's lymphoma of the appendix presented by Ignatius C. Sin *et al.*, from Department of Pathology, Queens University, Ontario, Canada. Both of these patients are children at eight and 10 years old presented with acute appendicitis.<sup>1</sup>

A routine appendicectomy was performed followed by chemotherapy after HPE results. Extensive investigations were carried out in the Ontario case reports following the histological diagnosis of Burkitt's lymphoma. They included cervical lymph node biopsy, bone marrow aspiration, spleen and liver scan, bone scan, short skeletal survey, chest x-ray, upper GIT series, barium enema and lymphangiogram. Their results were all within normal limits.

Recognition of the early stages appear to be a rarity in intra-abdominal Burkitt's lymphoma. Long-term survival have been observed in patients with localised disease.

Extensive removal of bulk tumour to reduce the tumour burden at the start of drug treatment has been shown to improve survival significantly. There

was an excellent survival record in the two cases of the primary lymphoma of the appendix reported by Loehr *et al.*, and in the two cases of Lewin *et al.* This may be related to the fact that the patient became symptomatic at an early stage as in the present case.

Further investigations in our patient were within normal limits. He was given three courses of chemotherapy and responded very well. On follow-up two months later, no recurrence was evident.

Loehr *et al.*, found an overall five-year survival rate of 49% in patients with gastrointestinal lymphoma. Highest survival underwent resection and than post-operative radiotherapy.

## ACKNOWLEDGEMENT

Dr Salmahanim Abu Hassan of the University Hospital, Kuala Lumpur contributed her invaluable opinion in the preparation of this report. I would also like to thank Puan Rohana Dingkel for her clerical assistance.

## REFERENCES

- <sup>1</sup> Collins O C. 71,000 human appendix specimens, a final report summarising forty years study. *Am J Proct* 1963; 14: 365-381.
- <sup>2</sup> Ziegler J L. Burkitt's lymphoma. *NEJM* 1981; 305 (13): 735-745.
- <sup>3</sup> Ignatius C Sin, *et al.* Burkitt's lymphoma of the appendix: Report of two cases. *Human Pathology* 1980; 11(5).