

# FOURNIER'S GANGRENE AND THE USE OF PREPUTIAL ROTATION GRAFT

M. M. SUDHAKAR KRISHNAN

## SUMMARY

*This paper presents four cases of Fournier's Gangrene, including one involving a reconstructive procedure using a preputial rotation flap to cover the raw area, to reduce the period of wound healing.*

*Since Fournier's description of Idiopathic scrotal gangrene in 1884, there have been a number of reports on this relatively rare disease but the problem of achieving early healing and epithelialisation remains.*

## CASE REPORTS

### Case No. 1

A fifty-nine year old Indian male was admitted with pain and swelling of 5 days in the scrotum. He had a swollen scrotum of 14 x 10 cms. with gangrene over its anterior, lateral and posterior surfaces, and discharging serosanguineous foul smelling fluid from its cracked surfaces. The penis was oedematous without evidence of gangrene (Fig. 1). The groins had fungal infection. Two days after admission, the gangrenous areas were excised. The testes were free from gangrene. The scrotal pus grew bacteroides and non-haemolytic streptococci.

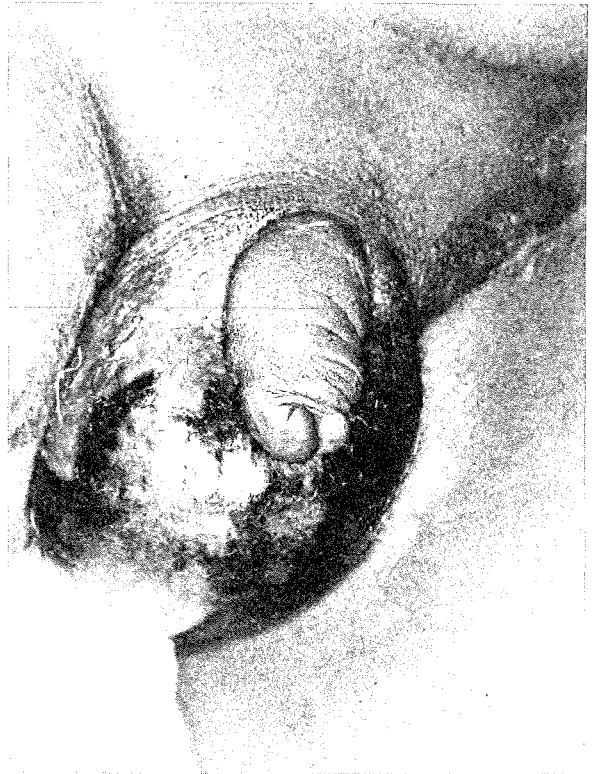


Fig. 1 Case No. 1 - Fournier's gangrene.

---

M.M. Sudhakar Krishnan,  
B.Sc. (Osmania), M.B.B.S. (Kerala),  
M.S. (Kerala), F.R.C.S. (Glasg.), & F.R.C.S. (Edin)  
Department of Surgery,  
University Hospital, Kuala Lumpur.

---

The histology of the excised tissue revealed areas of necrosis and acute inflammation and a few thrombi in the vessels with necrosis of the wall. Gram positive cocci, but no fungi were seen. In 10 days the wound was clean and had adequate contraction of the edges leaving a raw area of 6 x 5 cms.

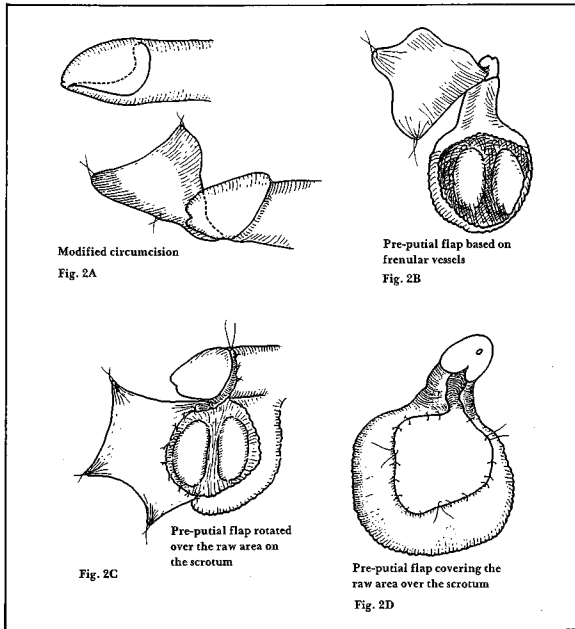


Fig. 2 A,B,C, & D Diagrammatic representation showing use of preputial skin based on the frenular vessels to cover the raw area of the scrotum.

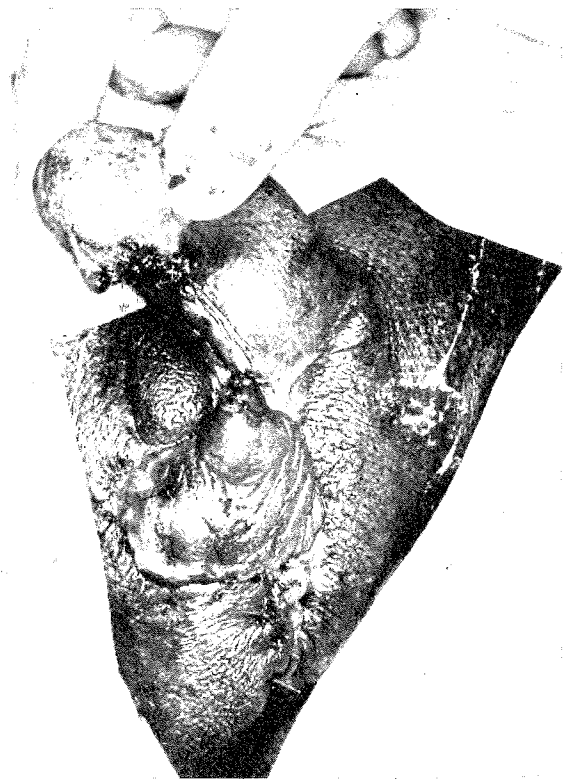


Fig. 4 Showing the reconstructed scrotum after disconnection of the vascular pedicle.

Following a modified circumcision (Fig. 2A), a preputial rotation flap based on the frenular vessels (Fig. 1B, Fig. 1C and Fig. 3) was used to cover the raw area (Fig. 2D).

Twelve days later the vascular pedicle was temporarily clamped to create ischaemia of the flaps, and to open up the collateral vascular channels. Two days thereafter the vascular pedicle was disconnected (Fig. 4). The graft was successful and the patient was discharged after being in the hospital for six weeks. At the follow up a month later the scrotum appeared fairly normal.

#### Case No. 2

A 68 year old caucasian was admitted with swelling and gangrene over the scrotum and parts of the penile skin (Fig. 5). He had fever and chills, 3 days prior to the swelling. With the onset of the foul smell two days later, he was hospitalised, and was given intravenous fluids and antibiotics. The gangrenous areas were excised and the scrotal tissues were desloughed on the 4th and 7th day after admission. The scrotal pus grew non-haemolytic




Fig. 3 The preputial flap rotated to cover the raw area on the scrotum.

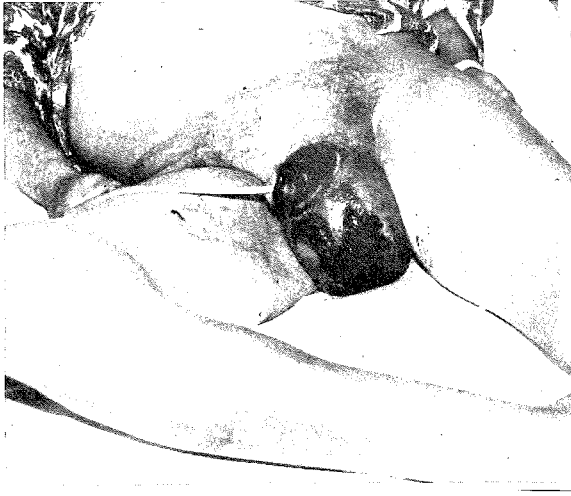

Fig. 5 Case No. 2 - A caucasian with Fournier's gangrene.

streptococci. Healthy granulation tissue and adequate wound contraction occurred after 18 weeks and the raw area was allowed to heal by fibrous tissue and wound contraction without any reconstruction or skin grafting (Fig. 6).

#### Case No. 3

After seven days of fever and rigors a 58 year old Nigerian with extensive gangrene of the scrotum, redness of the penis and left groin extending upwards into the lower abdominal wall was hospitalised. He was thin, apyrexial, dehydrated, toxic and had a foul smelling serosanguineous discharge from the scrotum. The scrotum measured 14 x 10 cms. with areas of blackish discoloration. The left groin and lower abdominal wall were red and in some areas indurated with subcutaneous abscesses. The gangrenous areas were excised. The abdominal abscesses incised to let pus and slough out. The pus grew staphylococcus aureus. Two further desloughing procedures were performed and the wound was allowed to granulate and heal by fibrous tissue formation and the wound was allowed to granulate and heal by fibrous tissue formation. The total period of healing was 14 weeks.

#### Case No. 4

A 43 year old Togolese presented with severe pain and redness of the scrotum and along with fever and rigors. The scrotum was swollen, warm and tender. Scrotal cellulitis was then diagnosed. He was given antibiotics, analgesics and scrotal

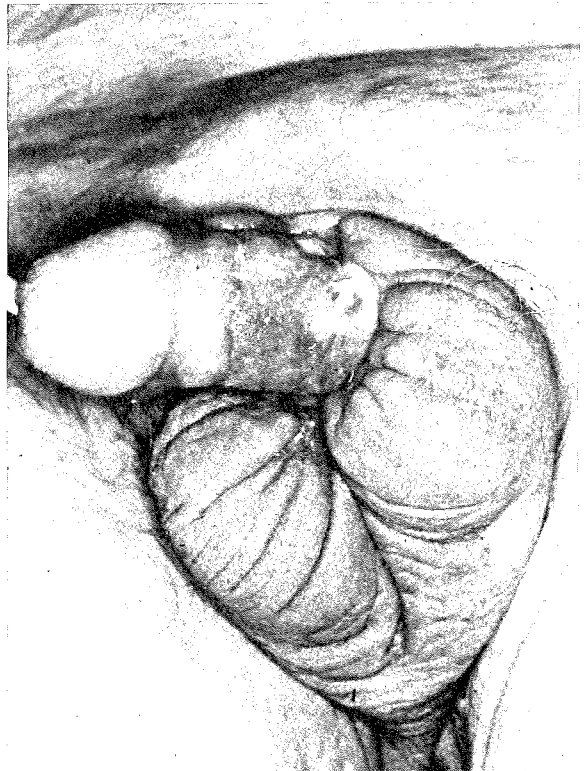


Fig. 6 Case No. 2 - Showing the healing by cicatrization - 18 weeks following the excision of the gangrenous tissues.

support. On the 3rd day gangrenous patches developed over the anterior scrotal wall and spread to the lateral sides the next day. The gangrenous areas were excised and the wound left open. The pus grew streptococcus hemolyticus. The wound was allowed to granulate and heal. Recovery was rapid for within 4 weeks there was adequate wound contraction and fibrous tissue formation.

#### DISCUSSION

In Fournier's gangrene there usually is no evidence of pre-existing disease either in genito-urinary tract or elsewhere. <sup>1</sup> This relatively sudden and rare disease which seems more prevalent in the African and Asiatic continents <sup>2</sup> occurs more often among those living in unhygienic circumstances. <sup>3</sup> The necrosis of Fournier's gangrene is ischaemic, resulting from an infection induced occlusive endarteritis. <sup>3,4</sup> The testes are invariably spared from the pathological process. <sup>3</sup> The exudate of the scrotum reveals such varied infecting organisms as non-haemolytic streptococcus, staphylococcus aureus, E. coli, Clostridium welchi, Pseudomonas, Proteus & Bacteroides. <sup>4,5</sup>

The infection is usually of the mixed type, with anaerobic organisms playing a very important role. It is not definitely known whether a reduced host resistance, an intrascrotal trauma, abrasion, or a sudden pathogenic activity of the scrotal commensal organisms is responsible for initiating the infection.<sup>5</sup> This condition in some cases produces an explosive onset of inflammation that, after a few hours, lead to gangrene,<sup>2</sup> as in case No. 4. Once gangrene sets in there is an offensive smell and the patient appears toxic. Desloughing is usually successful and the wound heals slowly by granulation tissue formation and cicatrization.

This paper seeks to emphasize that early reconstructive procedure to cover the raw area of the scrotum enhances healing. The use of the preputial rotation flap (Fig. 2 A,B,C & D) reduces the period of hospitalisation considerably. A modified circumcision rotates the prepuce with the frenular vessels on to the raw area of the scrotum. The inner epithelial lining of the prepuce could be opened to provide an extra skin cover. Excision of the gangrenous tissue and slough seems to arrest the disease. Granulation tissue covers the testes and the surrounding normal scrotal skin contracts in about 1 - 2 weeks, and is then ready to accept a preputial rotation flap. Case No. 1 illustrates this procedure.

In the other cases, recovery was prolonged as no reconstructive procedure was done. Case No. 4 is an example of the explosive onset in Fournier's gangrene, with a very short prodromal period, fortunately in this case the disease had not spread to the same extent as in the other cases.

#### ACKNOWLEDGEMENT

I wish to thank Professor K. Somasundaram for his encouragement in the preparation of this paper, and Miss Zureena Binti Haron for the secretarial work.

#### REFERENCES

- <sup>1</sup> Campbell M F and Harrison J H : Urology - W B Saunder's Company, Philadelphia; Vol. 1, 588-590, Edition 1970.
- <sup>2</sup> Tan R E : *J. Urol.* 1964; 92, 508-510.
- <sup>3</sup> Buchanan D J : Correspondence - Idiopathic Scrotal Gangrene, *Br. Med. J.* 1972, 4, 672-673.
- <sup>4</sup> Dunaif C B : *Plast. Reconst. Surg.* 1964, 33, 84-92.
- <sup>5</sup> Bejanga B I : Fournier's Gangrene - *Br. J. Urol.* 1979, 51, 312-316.