

UTERINE PERFORATION BY THE INTRA-UTERINE DEVICE

S. RAMAN,
V. SIVANESARATNAM
T.A. SINNATHURAY

SUMMARY

Translocation of the intra-uterine device is a worrying complication although it is an uncommon one. Here we have presented five cases diagnosed and treated at the University Hospital, Kuala Lumpur, four copper devices and one Lippes loop. The incidence, methods of diagnosis, hazards of translocation and methods of removal are discussed.

INTRODUCTION

Advances in fertility control have led to the wider use of contraceptive methods including the intra-uterine device. In this presentation, three cases of translocated Copper-7, one case each of translocated Copper-T and Lippes loop are summarised and their management discussed. Recent advances in the detection and removal of these devices is reviewed and discussed.

CASE 1

A 27-year-old Chinese female, para 4, had a Copper-7 device inserted at the University Hospital. Insertion was easy. Four months later at a routine follow-up visit, examination showed that the nylon thread was not visible. X-ray abdomen showed the device to be still in the pelvis and probably within the uterus. Dilatation and curettage did not reveal the presence of an intra-uterine device. Translocation was diagnosed and confirmed by hystero-salpingogram (Fig. 1). At laparoscopy the device was found to be embedded within the omentum. The uterus was normal with no evidence of perforation. There was difficulty in freeing the device from the omentum and this was delivered through the widened

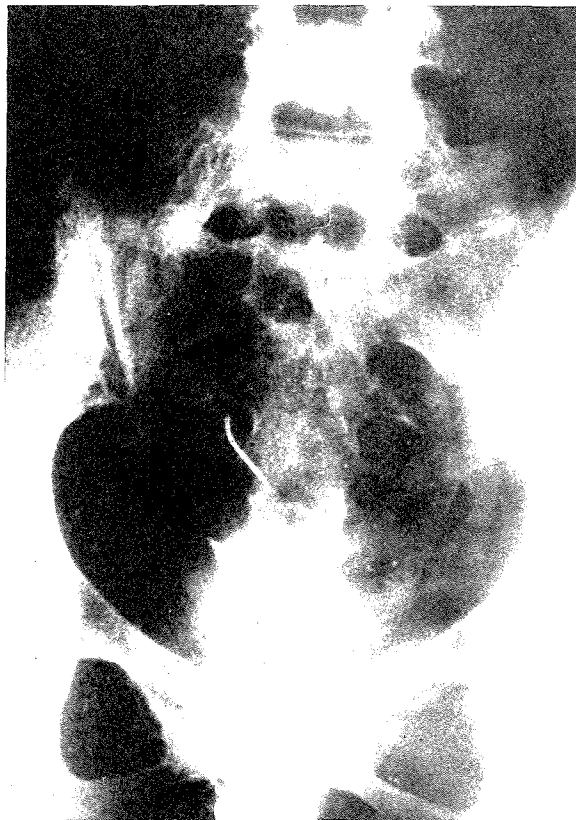

Fig. 1 Hysterosalpingogram - note the extra-uterine position of the Copper-7 device.

umbilical incision and removed under direct vision. The patient was discharged well the following day.

CASE 2

A 28-year-old Malay female, para 3, had a Copper-7 device inserted in Kuantan at a Family Planning Centre. Insertion was easy, with only slight abdominal cramps experienced by the patient soon after insertion. At routine follow-up six months later the thread of the device was not visible. Plain x-ray of the abdomen showed the device to be high up in the left paracolic gutter. There were no adhesions. Laparoscopic removal with a biopsy forceps through a separate incision at the

S. Raman, MBBS, MRCOG
Lecturer.

V. Sivanesaratnam, MBBS, MRCOG
Associate Professor

T.A. Sinnathuray, AM, MBBS (Malaysia), MD (S'pore),
FRCS (Edin.), FRCS (Glasg.), FRCOG, FICS, FACS.
Professor & Head of Department.

Department of Obstetrics & Gynaecology,
University of Malaya, Kuala Lumpur.

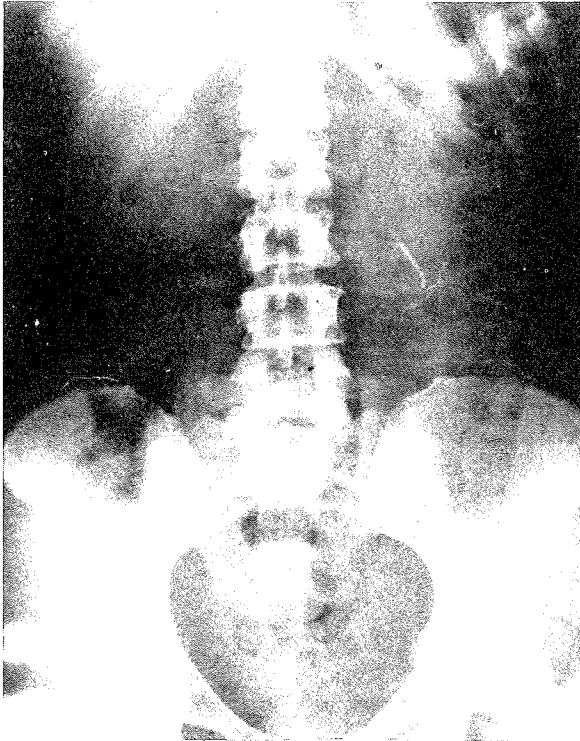


Fig. 2 X-ray Abdomen - note the translocated Copper-7 device high up in left lumbar region.

left iliac fossa was done at the University Hospital. She was discharged the following day.

CASE 3

A 34-year-old Caucasian female, para 3, had a Copper-7 device inserted by a general practitioner. Insertion was unremarkable. She saw the practitioner again later for amenorrhoea of seven weeks' duration, and a dilatation and curettage was done. As the device was not found in the uterine cavity she was referred to the University Hospital.

X-ray revealed the device to be at the level of the fifth lumbar vertebra (Fig. 2 and 3).

At laparoscopy the device was removed from the left iliac fossa with Palmer's forceps. There was bleeding from the site of removal due to adhesions and a mini-laparotomy was done and the bleeding site identified and ligated. The patient was discharged well.

CASE 4

A 29-year-old Indian housewife, para 3, had a lower segment Caesarean section done in 1976. A Lippes loop was inserted one month after delivery of her second child in 1978. She became pregnant one month later and delivered a male baby at term in 1979. The device was

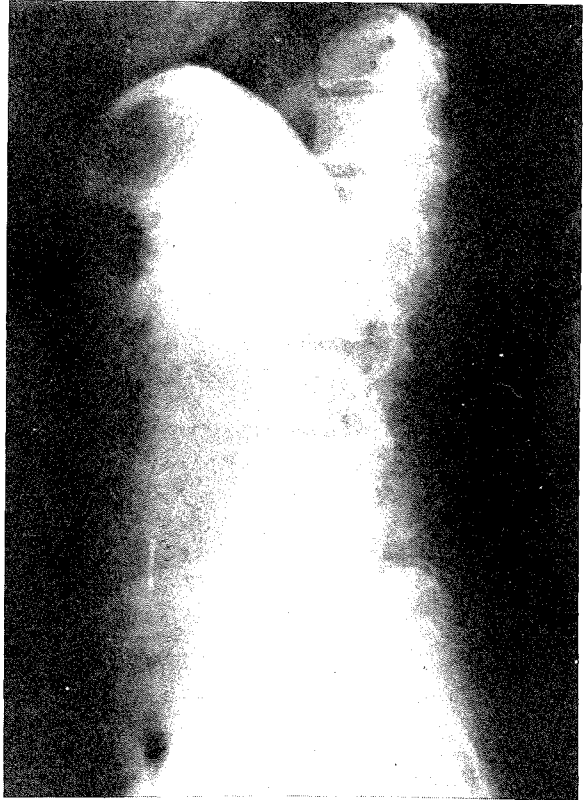

Fig. 3 Lateral x-ray abdomen - The device is at the level of the fifth lumbar vertebra on standing.

not expelled with the placenta and membranes, but on vaginal examination the thread of the device was visible at the external os. The device could not be removed with traction. Under anaesthesia the Lippes loop was not felt in utero although the thread was visualised.

At laparoscopy the tip of the Lippes loop was seen to be embedded in the utero-vesical fold of peritoneum surrounded by thick fibrous tissue. An attempt to remove it with Palmer's forceps was unsuccessful and a laparotomy was done to remove the device. The patient refused tubal ligation and was discharged seven days later. She agreed to go on oral contraceptives instead.

CASE 5

A 24-year-old female, para 3, had a Copper-T device inserted at the University Hospital six weeks after the delivery of her third child. There was no problems at insertion.

Four and a half months later she was seen for delayed menses. Examination revealed a bulky uterus and the tip of the thread of the device was just visible at the external os.

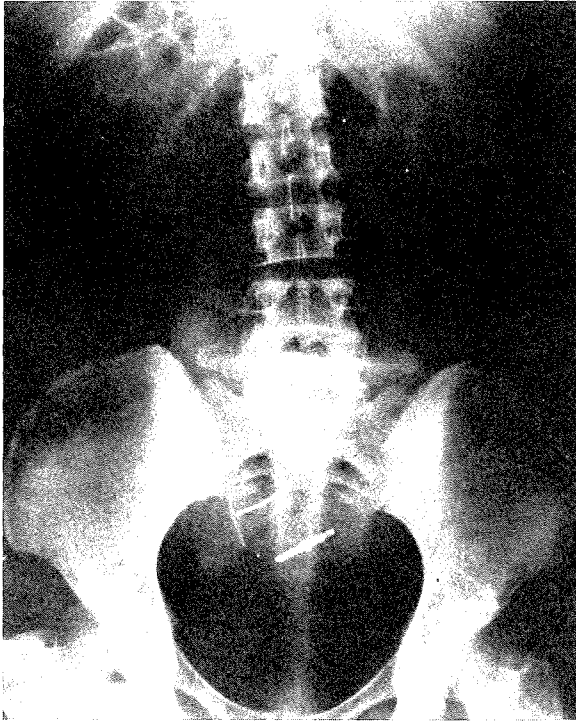


Fig. 4 X-ray abdomen - The newly inserted Lippes loop is in utero; the Copper T device is outside the uterus.

On attempting to remove the device the thread snapped. At "menstrual regulation" there were abundant curettings (products of conception) but the device was not felt in utero.

X-ray abdomen done after insertion of a Lippes loop into the uterine cavity revealed a translocation Copper-T (Fig. 4).

Dilatation and curettage under general anaesthesia (after removal of the Lippes loop) confirmed that the copper device was not in utero. At laparoscopy the stem of the device was just visible amidst dense adhesions on the pouch of Douglas. A uterine perforation on the posterior surface was seen. A laparotomy was then carried out. The Copper-T was completely translocated and embedded in adhesions between the posterior surface of the uterus and the sigmoid colon at the site of perforation.

The device was removed and the uterine perforation repaired. The patient was not keen on having a tubal ligation and she was discharged a week later with oral contraceptives.

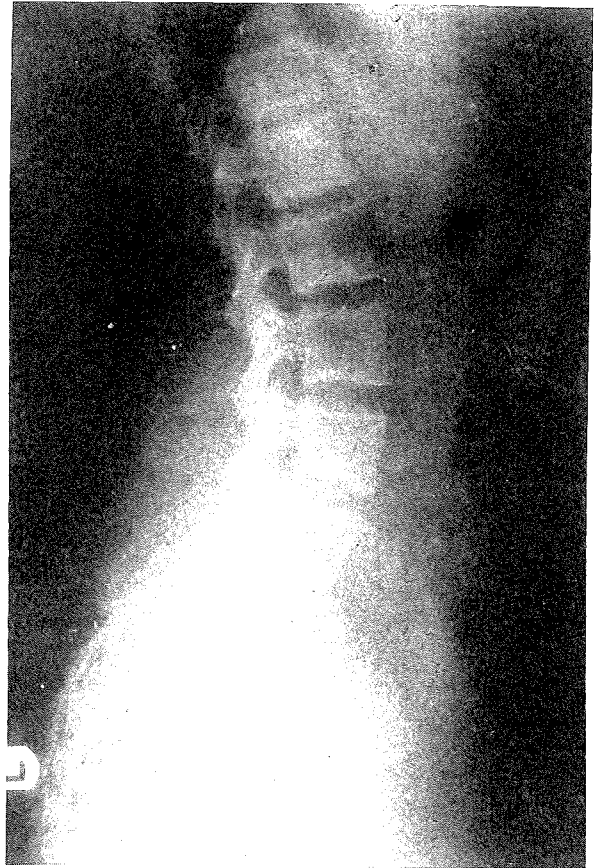

Fig. 5 Lateral x-ray abdomen - shows the Copper T device outside the uterus but within the pelvis.

DISCUSSIONS

Recent advances have made the intra-uterine device a popular method of contraception. However uterine perforation is a worrying complication which was one of the major causes that led to disrepute of the earlier devices, such as the Grafenberg ring.

The incidence of translocation varies and depends on the timing of insertion, the technique used ("withdrawal" or "push-out" technique) and the person performing the procedure.

Ratnam and Tow (1970) have shown that insertion of the Lippes loop size D, four to eight weeks postpartum has a higher translocation rate when compared with the non postpartal patient. This was seen in Case 4 above. Ratnam (1969) had also found that the perforation rate is higher if the inexperienced is performing the procedure.

Fewer perforations occur during insertion which uses

the "withdrawal" technique (e.g. Copper-T, copper-7) as compared to "push-out" methods (e.g. Lippes loop). The occurrence of four out of the five cases of perforations in our series were due to copper containing devices might give the wrong impression that perforations are more common with these devices. However, it would be noted that these are now the more commonly used devices in Malaysia. It is generally held that complete or partial translocation is secondary to uterine perforation which occurs at the time of insertion. Ratnam (1969), however postulates that with the Lippes loop spontaneous displacement through the uterine muscle is a distinct phenomenon and can account for some of the cases seen in the non post-partal patients.

When the thread of the device is missing at routine follow-up, translocated or spontaneous expulsion of the device should be suspected. In some instances the thread becomes retracted into the cervical canal or uterine cavity. In these circumstances the cervical canal can be explored with a forceps for the presence of a retracted thread or a uterine sound passed to detect the presence of the device in utero. A pelvic examination should be routinely done as the device may sometimes be felt in the pouch of Douglas from which it could be removed by colpotomy (Gentile and Siegler, 1977).

Other methods of diagnosis include ultrasonography and radiography. Unless the device is near the uterus and free from the omentum and intestines, it is difficult to locate it with the ultrasound. With radiography, although it is easy to detect an abdominal location of the device, a device in the pelvis will require a marker to localise the endometrial cavity to make a diagnosis of translocation. Such markers include hystero-graphy (as in Case 1), a radio-opaque instrument like a uterine sound, or insertion of another intra-uterine device in utero (as in Case 5). In some instances, hysteroscopy has been used when the device is partly in the uterine cavity (Siegler and Kemmann, 1975).

Some controversy exists over the management of translocated intra-uterine devices particularly the inert ones like the Lippes loop. In our view all translocated devices should be removed even though they are asymptomatic (Sivanesaratnam and Puvan, 1975). The risks of translocation depend on the type of device (open or closed) and whether they are medicated (e.g. copper) or not. Intraperitoneal closed devices like the Grafenberg ring or Birnberg Bow have circumscribed apertures larger than 5 millimetres through which a loop of bowel or omental segment could enter and be strangulated

(Benson, 1976).

Metal devices like the Copper-7 may cause visceral adhesions, as seen in Case 3 and Case 5. Such adhesions if neglected can lead to intestinal obstruction. This did not occur in our cases. Other complications reported are omental granulomas, peritoneal-cutaneous fistulous tracts and cystitis from an intravesical translocation of an intra-uterine device (Gentile and Siegler, 1977). Hazards involved in translocated progesterone-bearing devices have not yet been assessed but it is believed to be less harmful than copper, since progesterone is a rapidly absorbed natural hormone (Piotrow *et al*, 1979).

As illustrated in three of our cases, removal of the devices can usually be secured under laparoscopic control. Laparotomy is rarely required unless laparoscopy is contra-indicated or fails in removing the device as in two of our cases.

ACKNOWLEDGEMENT

We are grateful to Ivy Phang for typing the manuscript.

REFERENCES

- Benson, R. (1976) Current Obstetric and Gynaecologic Diagnosis and Treatment *Lange Med. Publications* pp. 426-432.
- Gentile, G.P. and Siegler, A.M. (1977): The Misplaced or Missing IUD, *Obstetrical & Gynaecological Survey*, Vol. 32, No. 10, pp. 627-636.
- Piotrow, P.T., Rinehart, W. and Schmidt, J.C. (1979): "Intra-uterine Devices", *Population Reports*, John Hopkins University, Vol. 7, No. 3.
- Ratnam, S.S. (1969): The Lippes Loop, M.D. Thesis, University of Singapore.
- Ratnam, S.S. and Tow, S.H. (1970): "Translocation of the Loop" Postpartum intra-uterine contraception in Singapore. Edited by D. Walters. *Excerpta Medica Foundation Amsterdam*, pp 134-15.
- Siegler, A.M. and Kemmann, E., (1975): Hysteroscopic Removal of Occult Intrauterine Contraceptive Device, *Am. J. Obstet. Gynaec.*, 46: 604-606.
- Sivanesaratnam, V., and Puvan, I.S., (1975) Asymptomatic perforations of the uterus with the Copper-7 I.U.D. and its management. *S'pore Med. J.* 16, pp. 312-314.